



## SIGMA® KNEE SYSTEM

This publication is not intended for distribution in the USA.

Never Stop Moving™ is a trademark of DePuy International Ltd.  
P.F.C.® and Sigma® are registered trademarks of DePuy Orthopaedics, Inc.  
Robert Brigham™ is a trademark and SPECIALIST® is a registered trademark of Johnson & Johnson.  
© 2010 DePuy International Limited. All rights reserved.  
DePuy Orthopaedics EMEA is a trading division of DePuy International Ltd.  
Registered in England No. 3319712

Cat No: 9068-45-000 version 3

DePuy International Ltd  
St Anthony's Road  
Leeds LS11 8DT  
England  
Tel: +44 (0)113 387 7800  
Fax: +44 (0)113 387 7890



SPECIALIST<sup>2</sup> INSTRUMENTS

Fixed Bearing Surgical Technique

# Prostheses Designed by

## **Cruciate-Retaining Prosthesis**

### **Richard D. Scott, M.D.**

Associate Clinical Professor of Orthopaedic Surgery,  
Harvard Medical School

Orthopaedic Surgeon, New England Baptist Hospital  
and Brigham and Women's Hospital

Boston, Massachusetts

## **Cruciate-Substituting Prosthesis**

### **Chitranjan S. Ranawat, M.D**

Clinical Professor of Orthopaedic Surgery,  
Cornell University Medical College

Director, Orthopaedic Surgery  
Centre for Total Joint Replacement  
Lenox Hill Hospital  
New York, New York

### **Thomas S. Thornhill, M.D.**

Chairman, Department of Orthopaedic Surgery,  
Harvard Medical School

Orthopaedic Surgeon, New England Baptist Hospital

Boston, Massachusetts

# Contents

Introduction	1
Primary Cruciate-Retaining Procedure	4
Primary Cruciate-Substituting Procedure	45
Appendix I: Ligamentous Balance in Total Knee Arthroplasty	85
Appendix II: The External Femoral Alignment System	94
Appendix III: Intramedullary Alignment Device	95
Appendix IV: Extramedullary Tibial Alignment Device with Proximal Fixation Spike	100
Appendix V: Femoral and Tibial Insert Compatibility Charts	103

**Appendix IV, Surgical Technique,**  
**edited by William L. Healy, M.D., Chairman**  
**Department of Orthopaedic Surgery,**  
**Lahey Hitchcock Medical Center, Burlington, M.A.**

# Specialist® 2 Technique

## Introduction

Total knee replacement is performed on a range of patients, of all ages, with various pathologies and anatomical anomalies. As no single arthroplastic approach is appropriate for every knee, the surgeon must be prepared, as the situation indicates, to preserve or substitute for the posterior cruciate ligament. PCL sacrifice is indicated in patients with severe deformity, profound flexion contracture and in the greater number of revision cases. Most primary and some relatively uncomplicated revision cases are suitable cruciate-sparing procedures. Where the ligament is to be preserved, it is essential that its balance in flexion be confirmed.

The P.F.C.® Total Knee Systems were designed as comprehensive approaches allowing intraoperative transition from PCL retention to PCL substitution. The major difference in the design for the two prostheses is the incorporation of an intercondylar post in the PCL substituting tibial insert and its corresponding intercondylar receptacle in the femoral component, to compensate for the stabilising restraint of the PCL. They were also designed to provide greater restraint in cases of revision surgery, and to meet the most demanding clinical and institutional requirements.

A single integrated set of instruments, the Specialist® 2 Instruments, was designed to assure fully accurate bone resection and to accommodate most surgical techniques and contingencies.



## Criteria For Successful TKR

### Appropriate Sizing of Components

This is attained through critical approximation of the A/P dimension of the femoral component to the lateral femoral profile. Undersizing will create looseness in flexion and possible notching of the femoral cortex. Oversizing will create tightness in flexion and increased excursion of the quadriceps mechanism.

### Accurate Component Alignment

This is assured by resection of the distal femur in the appropriate degree of valgus as determined by preoperative evaluation, and resection of the proximal tibia at 90° to its longitudinal axis.

### Soft-Tissue Balance

This is realised through the careful sequential release of medial constraining elements in varus deformity and lateral structures in valgus.

### Accurate Patellar Tracking

This is effected through accurate positioning of the femoral and tibial components, precise resurfacing of the patella, careful trial evaluation and, where indicated, lateral retinacular release.

### Dependable Cement Fixation

This is achieved through controlled technique that ensures the establishment of comprehensive bone/cement/prosthesis interlock.

## Balancing the Knee

The appropriate level of prosthetic constraint is determined through preoperative evaluation subject to intraoperative confirmation. Where soft-tissue constraint is identified, the system is designed to effectively address it.

### Primary Cruciate-Retaining TKR

A posteriorly lipped insert is employed, designed for situations where the PCL is functionally intact. Where there is tightness in the PCL, a posterior cruciate recession is indicated (see Appendix I).

### Primary Cruciate-Supplementing TKR

A curved insert is used with improved contact area to supplement the PCL where the ligament has sufficient functional laxity to accommodate the greater conformity.

### Primary Cruciate-Substituting TKR

This incorporates a central polyethylene eminence in the tibial insert to perform the function of an absent PCL. The corresponding femoral component uses A/P cuts and chamfers identical to those of the PCL-retaining component, allowing ready transition without revision of the prepared implantation site.

### Revision TKR

The geometry of the tibial insert allows for substitution of the PCL and/or MCL in revision and complex primary situations. The selection of modular tibial and femoral stems and wedges will accommodate virtually any revision consideration. The system offers three levels of constraint to meet the varied requirements of revision cases; stabilised, constrained or TC3.

## Preoperative Planning

Full-length extremity roentgenograms are obtained and the mechanical and anatomic axes identified. Where the intramedullary alignment system is selected, the angle of the anatomic and mechanical axes indicates the appropriate angle to be used in conjunction with the intramedullary rod and the femoral locating device, thereby assuring that the distal femoral cut will be perpendicular to the mechanical axis. It is helpful to draw the femoral and tibial resection lines on the film as an intraoperative reference.

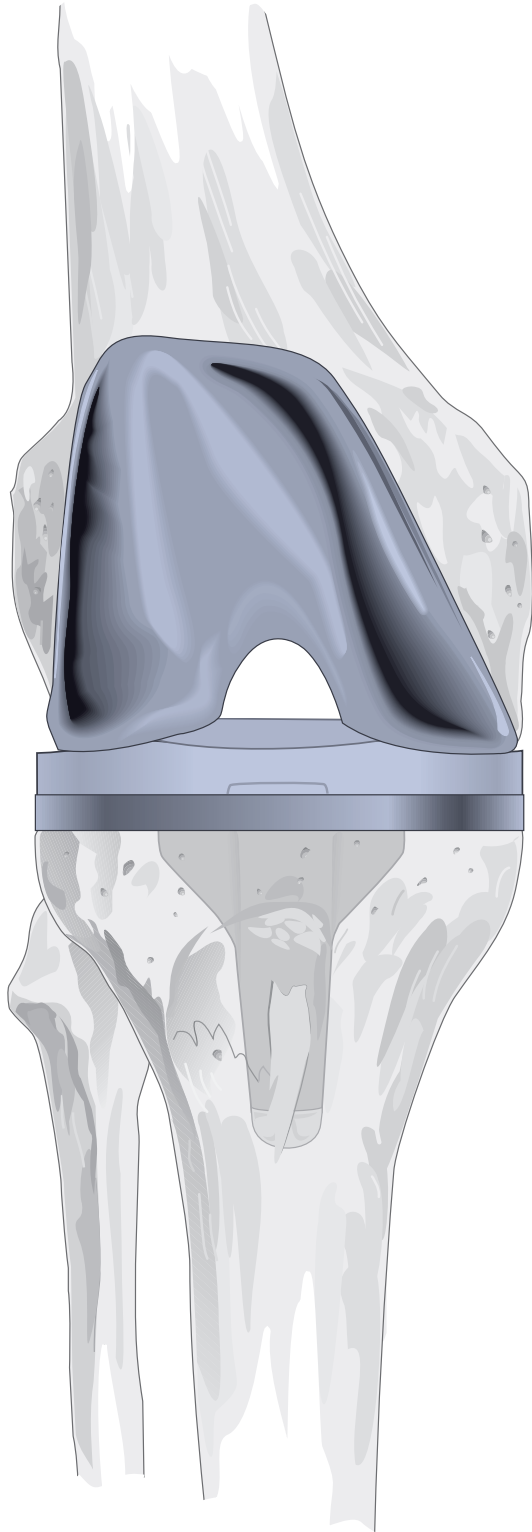
Radiographic templates are overlaid on the films to estimate the appropriate size of the prosthesis. The femoral component is sized on the lateral view. The A/P size is critical to the restoration of normal kinematics and quadriceps function.

## Instrumentation Rationale

Specialist® 2 Instrumentation was designed to address the requirements of all total-knee replacement procedures, to fully assure precise and dependable resection of the recipient bone and to serve a variety of surgical options. The instruments can be customised to meet any special requirements of the individual surgeon.

Preparation may be initiated at either the femur or the tibia. The instruments may be employed with either the intra-or extramedullary alignment approach. Bone resection is made at the appropriate level as determined through a calibrated stylus assembly. A selection is offered of slotted and surface-cutting blocks. Spacer blocks are provided for extension and flexion gap evaluation. Patellar instrumentation is available for compatible preparation of either resurfaced or inset patellar implants.

# Primary Cruciate-Retaining Procedure



## **Richard D. Scott, M.D.**

Associate Clinical Professor of Orthopaedic Surgery,  
Harvard Medical School

Orthopaedic Surgeon, New England Baptist Hospital  
and Brigham and Women's Hospital

Boston, Massachusetts

## **Thomas S Thornhill, M.D.**

Chairman, Department of Orthopaedic Surgery,  
Harvard Medical School

Orthopaedic Surgeon, New England Baptist Hospital

Boston, Massachusetts

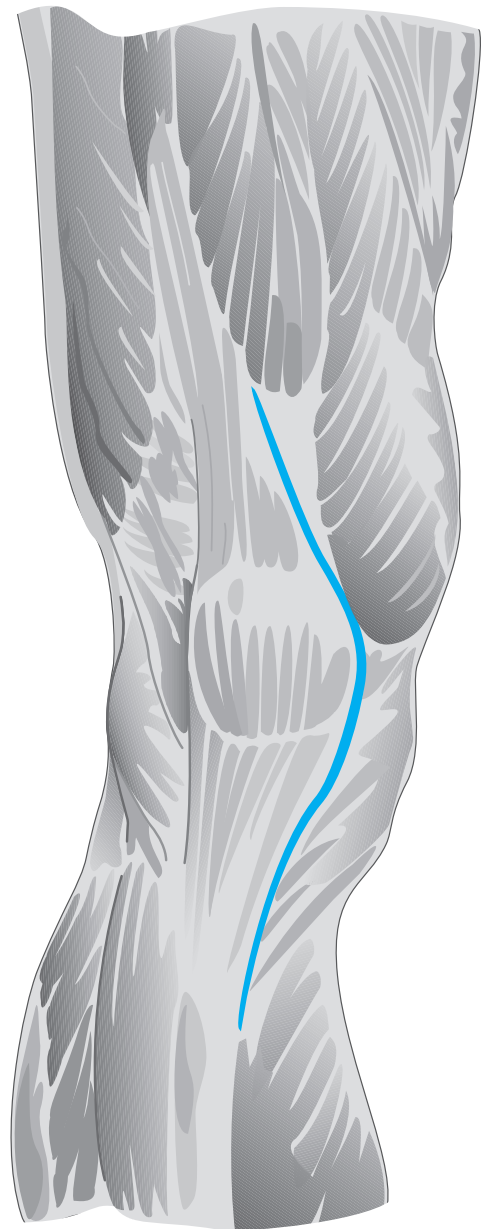
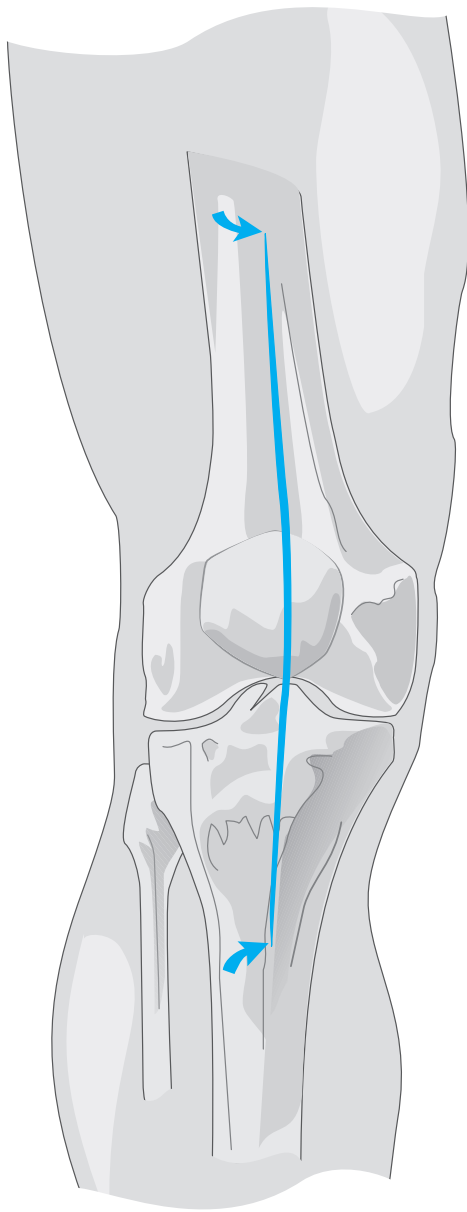
# The Surgical Approach

The extremity is appropriately prepared and draped. A tourniquet is applied and following application of an Esmarch bandage, inflated.

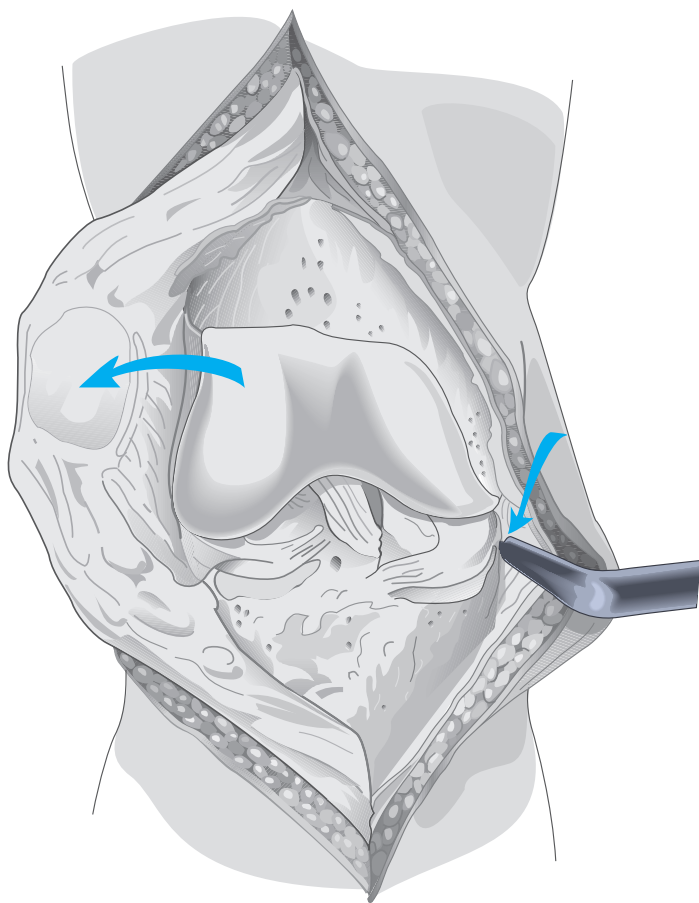
The skin incision is longitudinal and, where possible, straight. It is initiated proximally from the midshaft of the femur and carried over the medial third of the patella to the medial margin of the tibial tubercle.

The joint is entered through a medial parapatellar capsular approach, extended proximally to the inferior margin of the rectus femoris and distally to the medial margin of the tubercle.

**Note: Where indicated, the subvastus or the lateral approach may be used.**



# Exposure

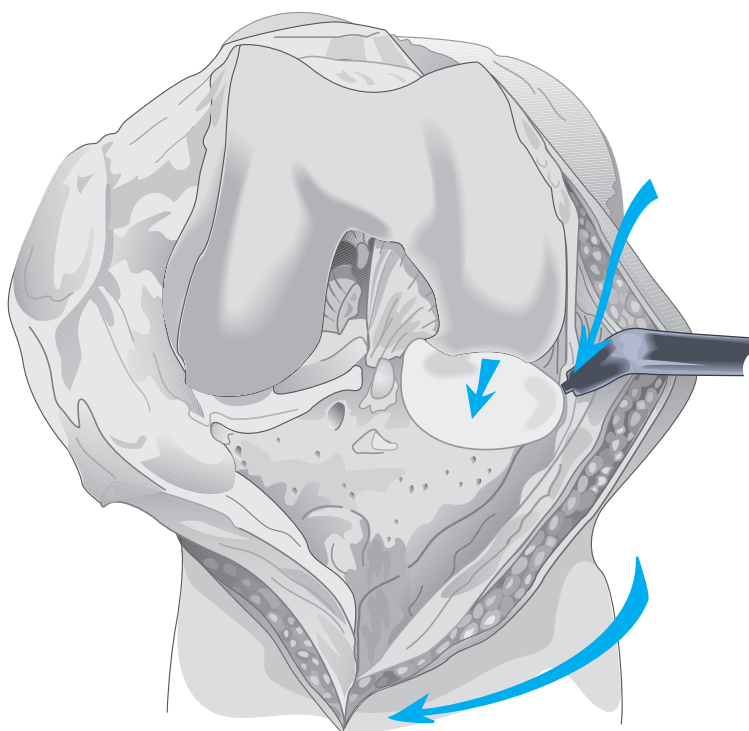


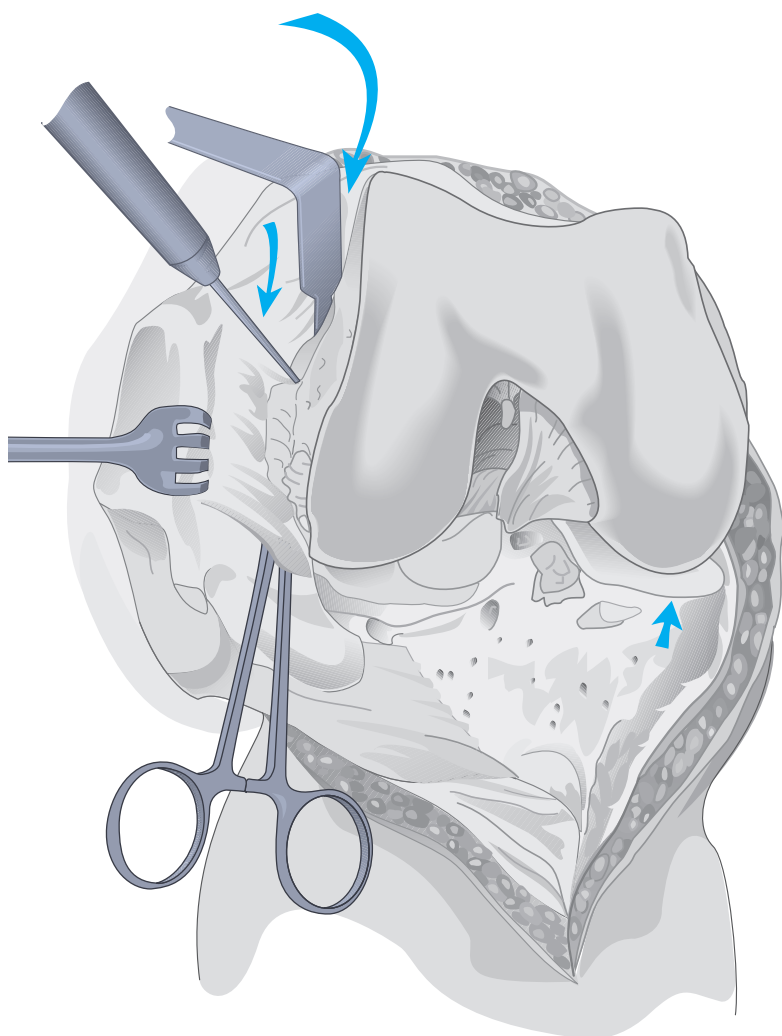
Exposure and preliminary balance must be based on the patient's preoperative deformity and soft-tissue stability. The following is for mild varus deformity.

**Note:** See Appendix I for discussion of soft-tissue balance.

With the knee in extension, the patella is everted laterally. The medial tibial periosteum is elevated and a narrow 90° Hohmann retractor positioned subperiosteally around the medial border of the medial condyle. Residual periosteum is dissected posteromedially to the level of the insertion of the semimembranosus. The knee is flexed and a partial meniscectomy performed. Any residual ACL is excised.

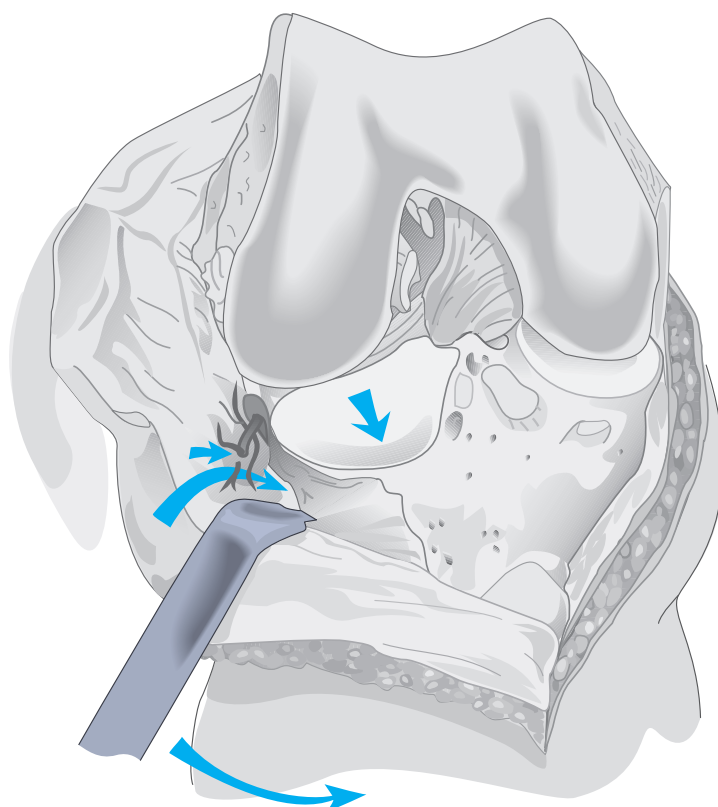
With the knee in 90° of flexion, the tibia is externally rotated with posteromedial dissection, bringing its medial condyle clear of the femur. Medial meniscectomy is completed, and attention directed to the lateral side.



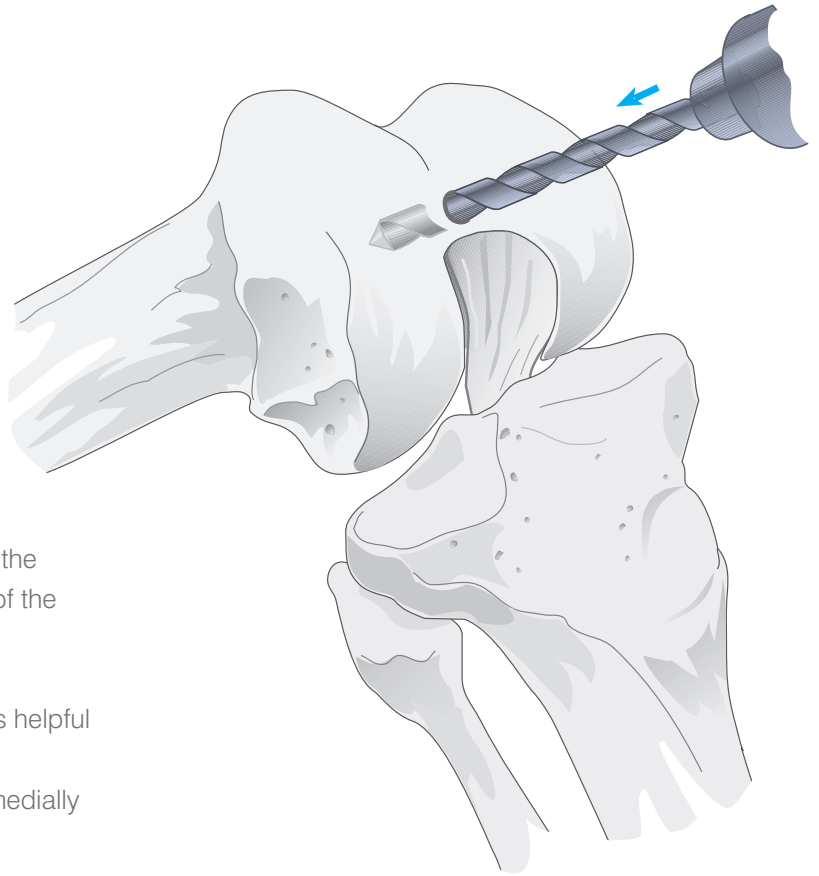


A 90° Hohmann retractor is positioned between the everted patella and the distolateral femur, exposing the lateral patellofemoral ligament, which is incised with electrocautery.

The retractor is repositioned at the interval of the iliotibial tract and the tibial attachment of the capsule. The capsule is dissected free from the infrapatellar fat pad and a lateral meniscectomy is performed. The lateral inferior genicular artery is coagulated. The insertion of the iliotibial tract is identified and the capsule dissected from the lateral tibial condyle. The retractor is repositioned against the lateral tibial condyle.

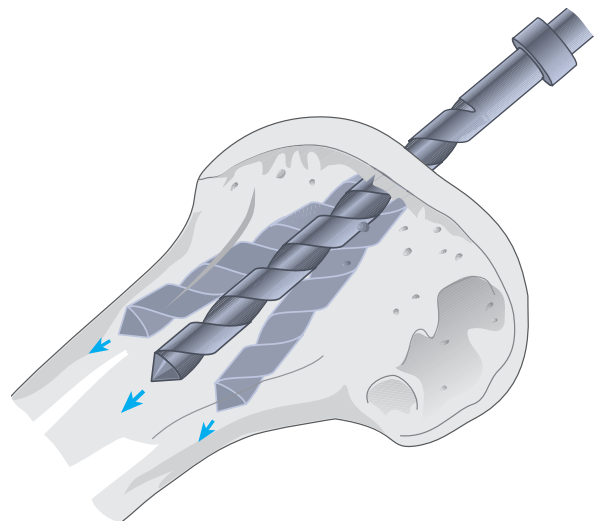
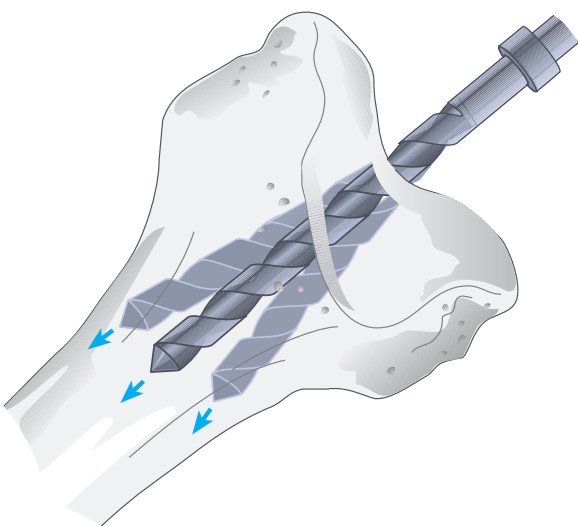


# Entering the Medullary Canal



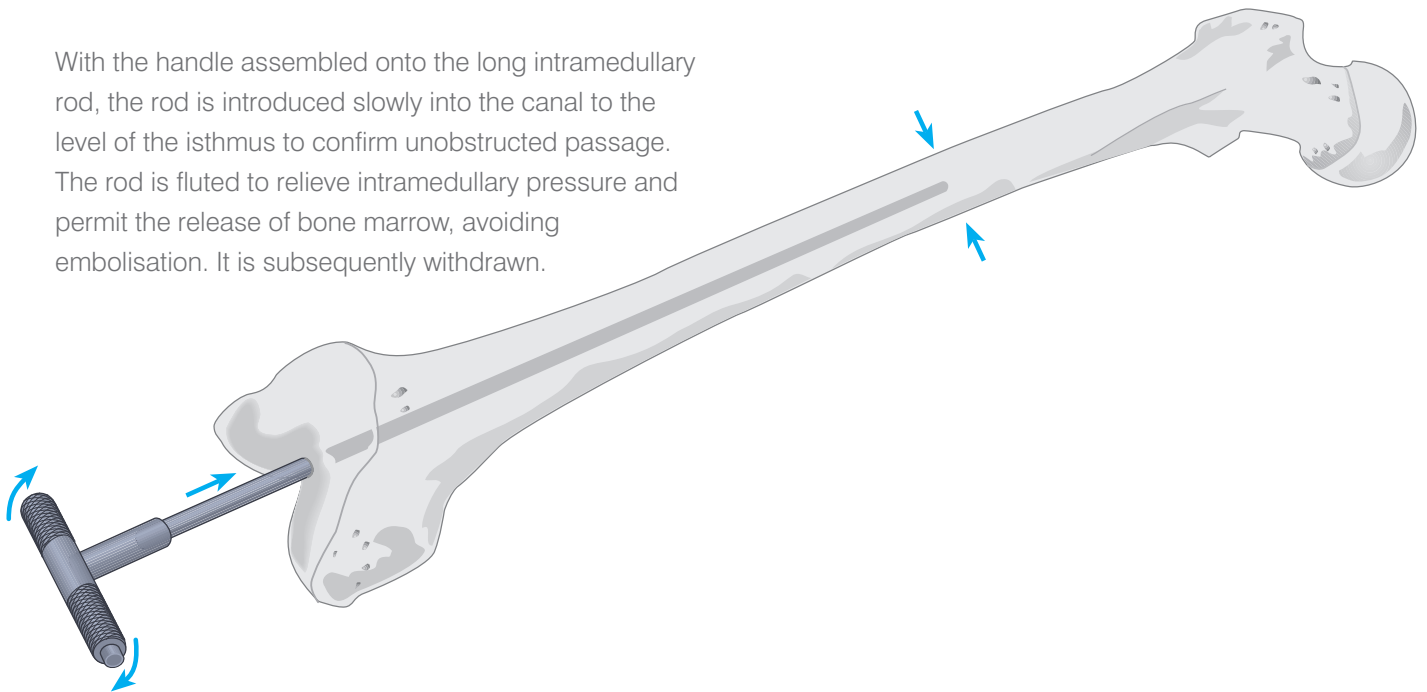
The medullary canal is entered at the midline of the femoral trochlea 7-10 mm anterior to the origin of the PCL to a depth of about 5-7 cm using a  $\frac{5}{16}$ " drill.

Care is taken that the drill avoid the cortices. It is helpful to palpate the distal femoral shaft as the drill is advanced. The drill hole may be biased anteromedially to facilitate unobstructed passage of the long intramedullary rod to the diaphyseal isthmus, if indicated by pre-operative x-rays.



# The Intramedullary Rod

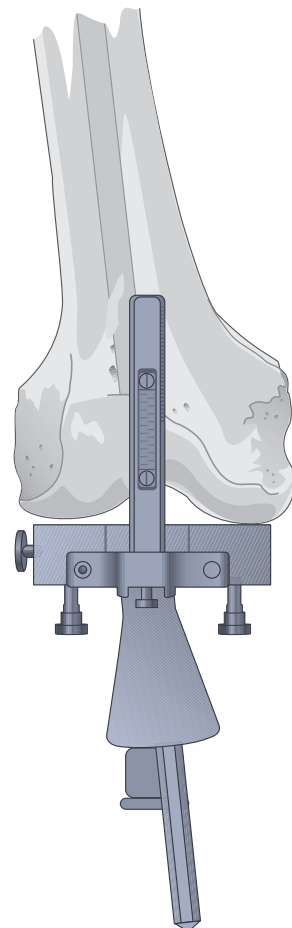
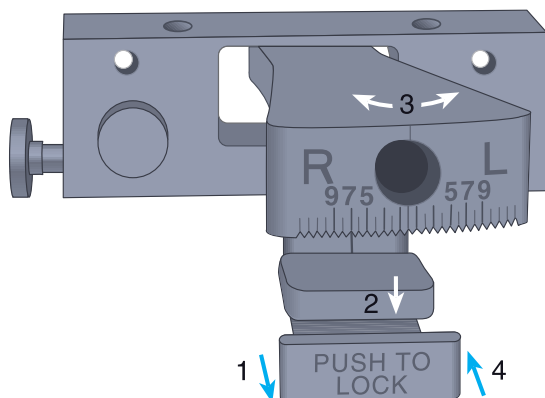
With the handle assembled onto the long intramedullary rod, the rod is introduced slowly into the canal to the level of the isthmus to confirm unobstructed passage. The rod is fluted to relieve intramedullary pressure and permit the release of bone marrow, avoiding embolisation. It is subsequently withdrawn.



# The Femoral Locating Device

The valgus angle with the appropriate Right/Left designation, as indicated on the preoperative films, is set and locked into place on the front of the locating device. The angle can be set from 0° to 9° in 1° increments.

With the rod repositioned in the medullary canal, the handle is removed and the locating device is placed over the rod.

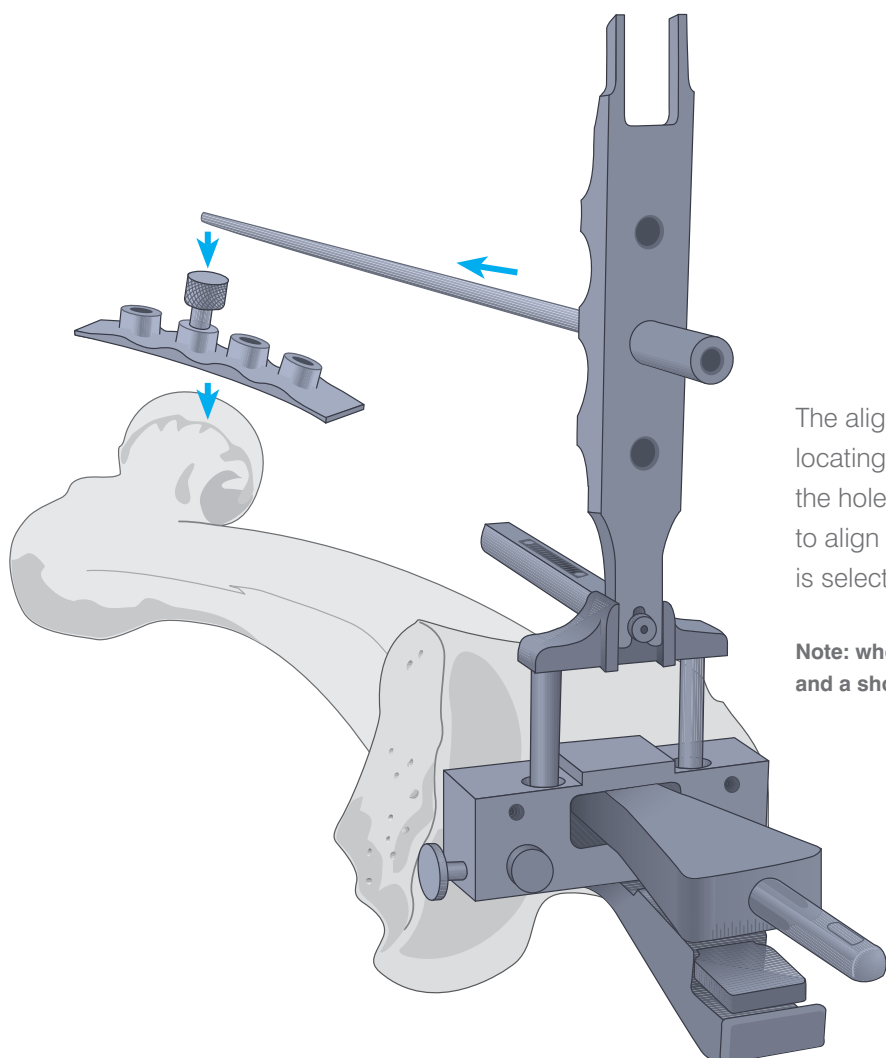
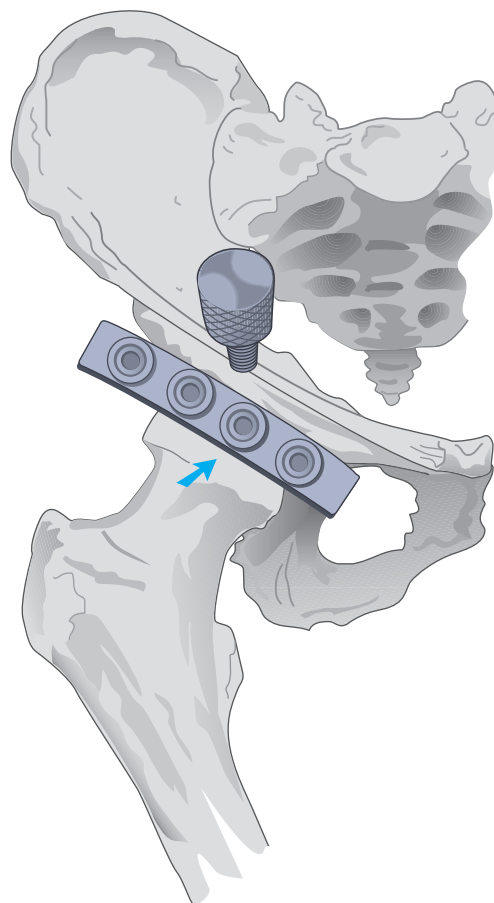




# The External Alignment System

A radiopaque marker is positioned over the ipsilateral hip, parallel and immediately distal to the inguinal ligament. An A/P roentgenogram indicates which of four markers most closely approximates the rotational centre.

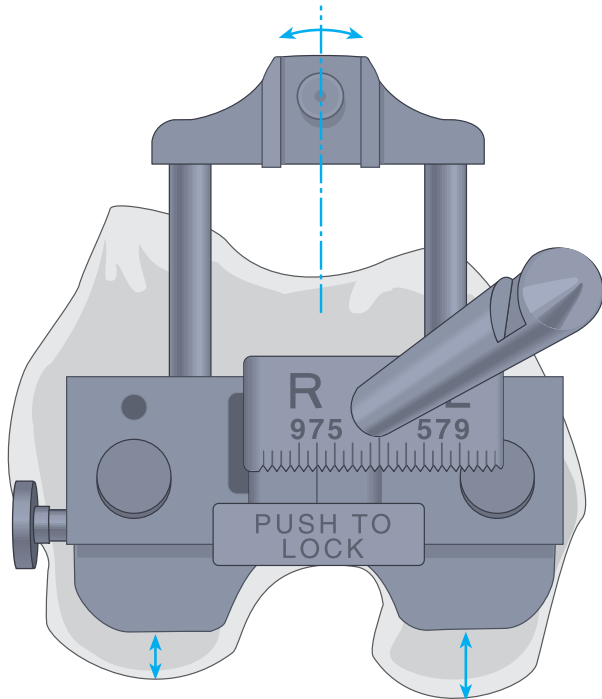
At surgery, the femoral-head locating strip is aligned with the markers. A target screw is introduced into the position overlaying the rotational centre. Draping is such that the screw is readily palpated at the coxal reference point.



The alignment tower is assembled onto the femoral locating device. The alignment rod is passed through the hole and advanced to the hip. Where the rod fails to align with the coxal reference point, a different angle is selected.

**Note:** where indicated, as in femoral deformity, 0° is selected and a short intramedullary rod is substituted. See Appendix II.

# Rotational Correction

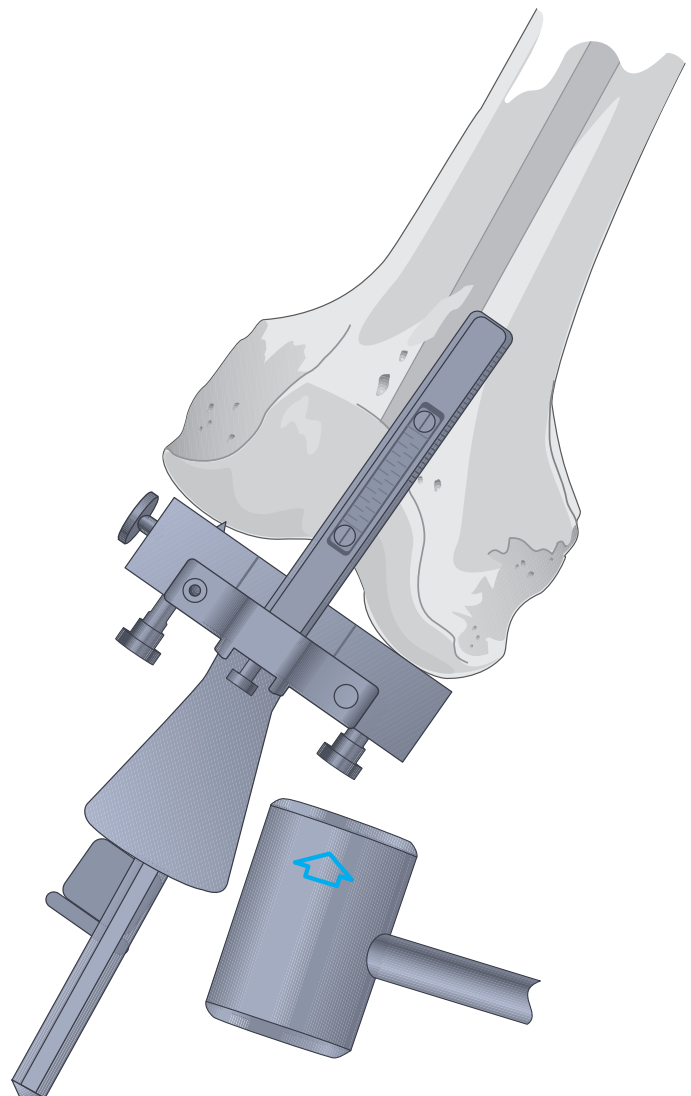


Orientation is initially determined with reference to the posterior femoral condyles, subject to subsequent correction at the A/P resection. The calibrated outrigger is centred at the femoral trochlea, placing it in slight external rotation and exposing a greater amount of medial condyle.

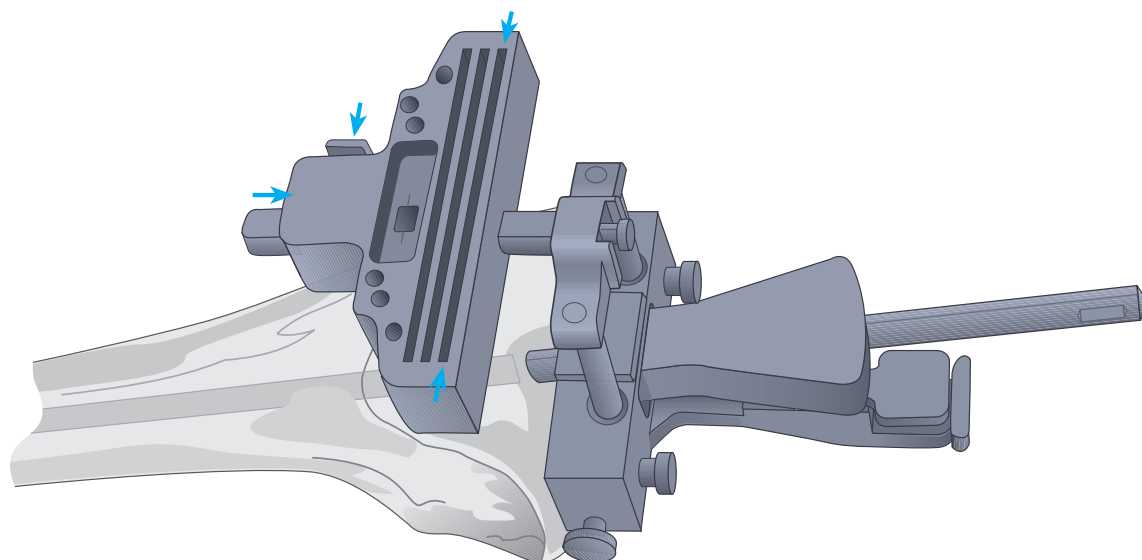
Alternatively, it may be externally rotated until perpendicular to the mechanical axis of the tibia in 90° of flexion.

The femoral locating device is tapped into position at the more prominent condyle (usually the medial).

**Note:** It is essential that firm contact be established at the subchondral level of the condyle, clear of any residual peripheral osteophytes.

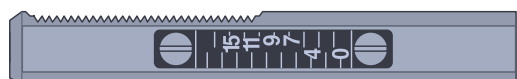

# The Distal Femoral Cutting Block



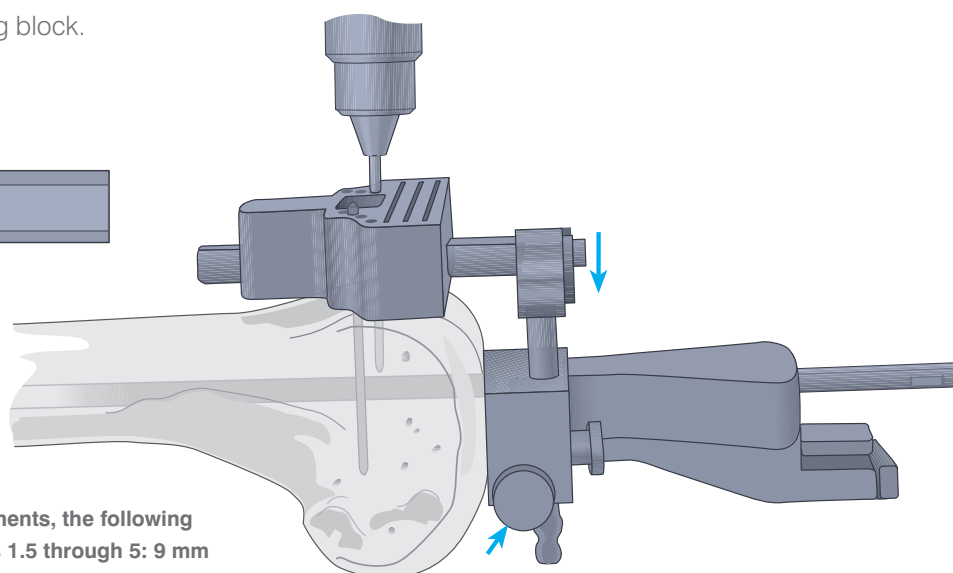
The cutting block is assembled onto the calibrated outrigger by depressing the button located on the right proximal end. The resection of the more prominent condyle, inclusive of residual cartilage, will correspond to the distal dimension of the femoral prosthesis. Where the femoral locating device rests on eburnated bone, resection is 2 mm less than the distal dimension of the femoral prosthesis to allow for absent cartilage and to avoid elevation of the joint line.

The scale for the numbers on the outrigger is even on the left and odd on the right. The number corresponding to the appropriate resection level is aligned with the inscribed line in the centre of the window of the distal femoral cutting block.



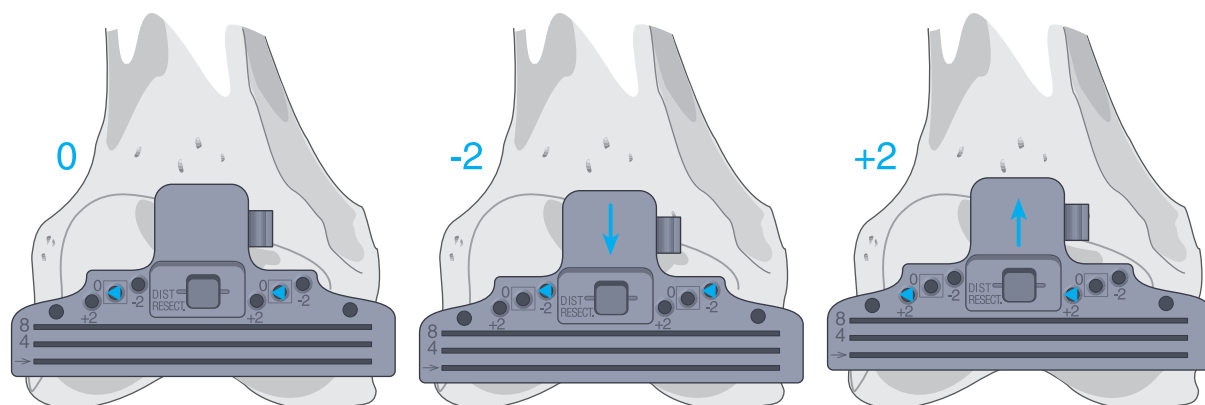
The base block is slotted; however, if used without the slot and the resection is initiated from the top of the block, 4 mm is added to the resection level. For example, if 9 mm is the desired resection level, add 4 mm to this and set the block at 13 mm and cut from the surface of the block. Note the top of the block is engraved "4 mm offset".

The outrigger and cutting block is lowered onto the anterior cortex by depressing the button on the left-hand side of the locating device. Either 1/8" drill bits or Steinmann pins are introduced through the holes designated zero and enclosed in □'s. They are advanced into the anterior cortex.



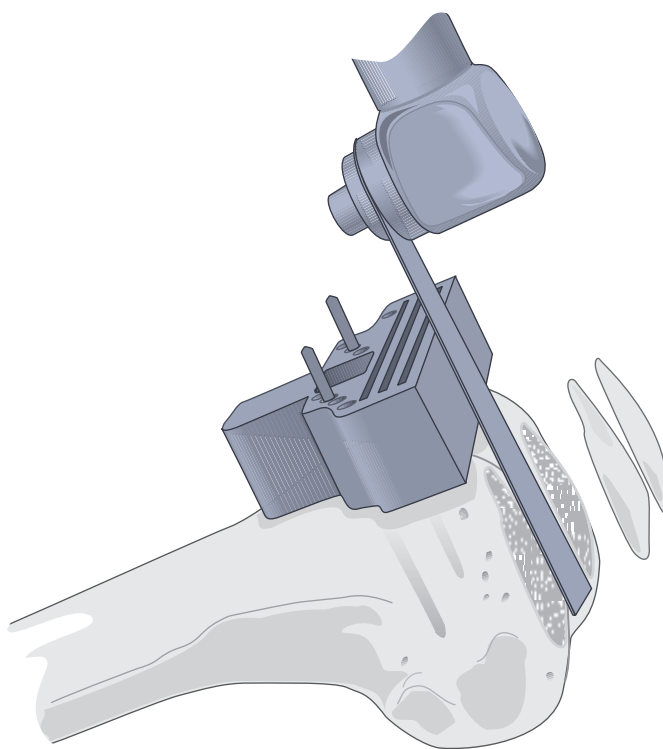
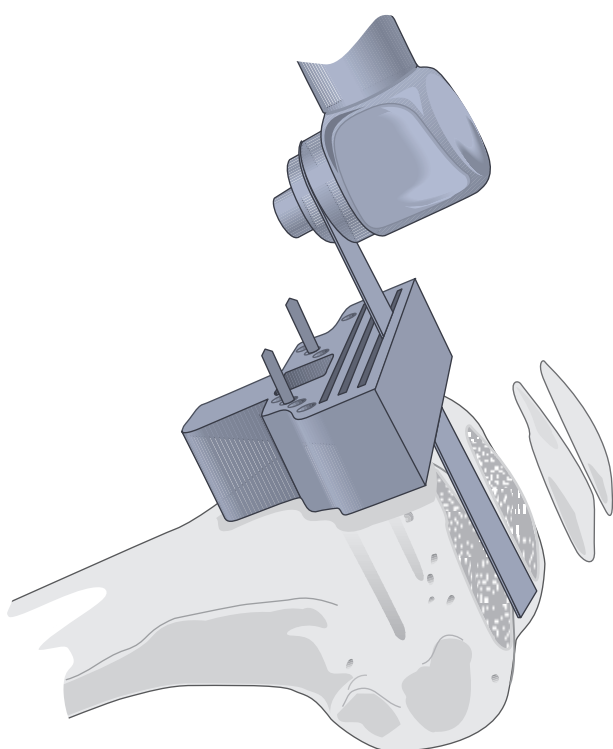
**Note: For P.F.C.® Sigma Femoral components, the following distal resection is recommended: Sizes 1.5 through 5: 9 mm distal resection, size 6: 10 mm distal resection.**

# The Distal Femoral Cut

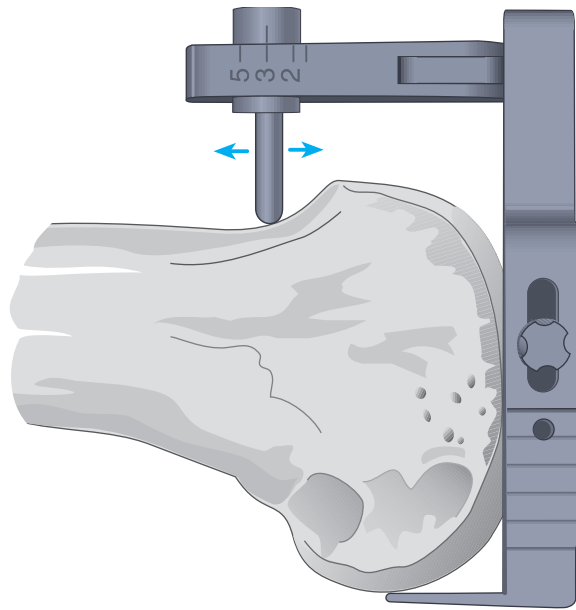


The locating device and intramedullary rod are disengaged from the cutting block by depressing the right button on the cutting block. The holes on the block are designated -2, 0, and +2 indicating in mm the amount of bone resection each will yield supplemental to that indicated on the calibrated outrigger.

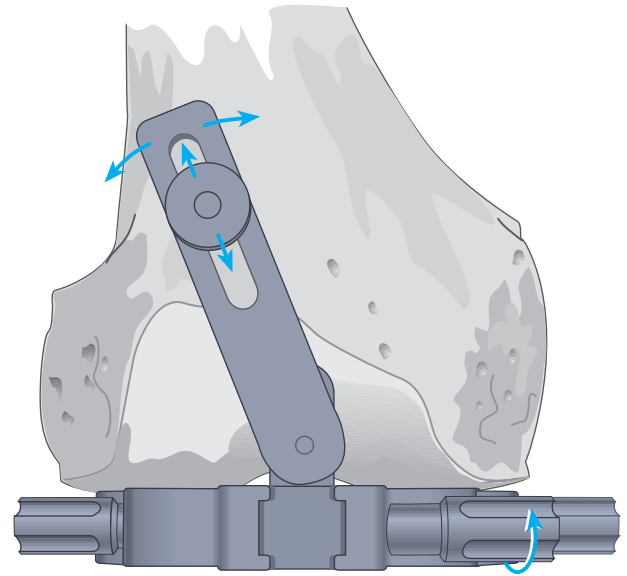
The oscillating saw blade is positioned through the slot, or, where applicable, the blade is positioned flush to the top cutting surface of the block. The condyles are resected and the surface checked for accuracy.



# The Femoral Sizing Guide



The guide is seated flush and centred on the prepared distal femoral surface. The stylus is allowed to move freely within the guide and moved proximal to the articular surface.



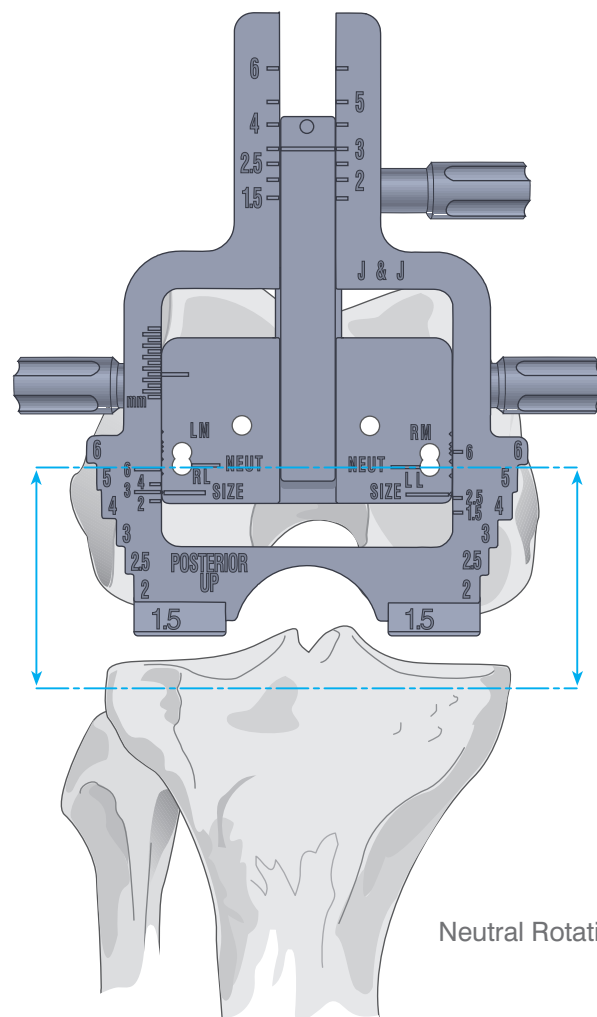
The stylus is passed over the anterior cortex immediately proximal to the articular surface. At the appropriate level where the stylus is not impeded, turn the stylus locking knob clockwise until tight, to fix its position.

# Rotational Alignment

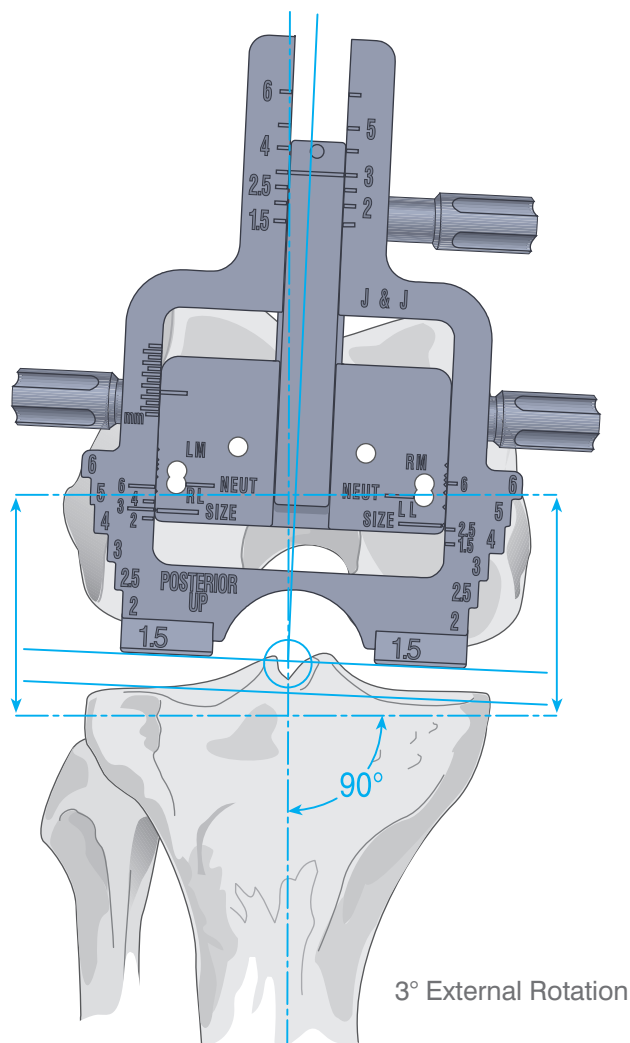
The sizing guide skids are positioned against the posterior condyles. This determines rotational alignment. Where either condyle is deficient, the guide is rotated such that it lies perpendicular to the mechanical axis of the tibia.

**Note: Alternatively, the tibia may be prepared first, wherein the A/P femoral cuts are based on the relationship of the condyles to the prepared tibial surface.**

Where the appropriate position of the stylus is determined, secure the stylus arm in position by tightening the arm clockwise. The actual size of the femur is indicated on the vertical shaft of the stylus arm.



Neutral Rotation



Where, as in most cases, the tibia is resected at 90° to its mechanical axis, the femoral component is positioned in approximately 3° of external rotation to produce flexion gap symmetry. Accordingly, the lateral posterior and medial anterior holes are selected, yielding 8 mm lateral and 10-11 mm medial resection. The cutting block thus positioned will yield a cut in 3° of external rotation, enhancing patellar tracking and promoting flexion gap symmetry. It will reduce soft-tissue release for tight medial flexion gap and allow commensurate rotation of the tibial component.

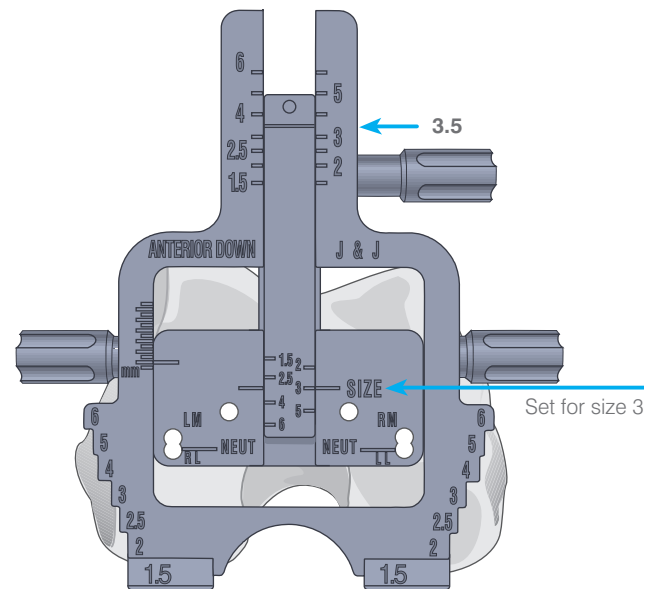
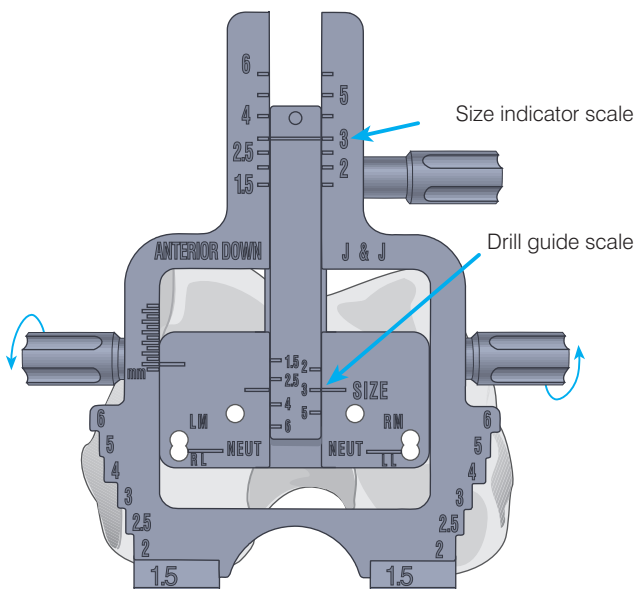
Occasionally, more than 3° of external rotation is indicated for flexion gap symmetry. Following removal of peripheral osteophytes, with 90° of flexion and the collateral ligaments tensed with laminar spreaders, the external tibial alignment device is positioned with its upper platform raised to the level of the holes made through the drill guide, which should lie parallel to the platform. Where more external rotation is indicated, the medial hole is repositioned anteriorly. In valgus deformity with lateral condylar hypoplasia, the lateral hole is repositioned posteriorly.

# Femoral Sizing

The femoral sizing guide is available in two formats: Anterior Reference and Posterior Reference.

## Anterior Reference Guide

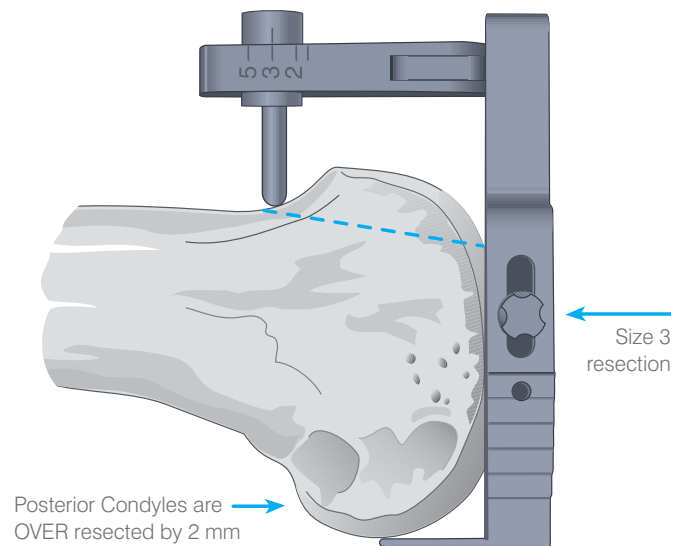
The sizing guide will position the femoral A/P chamfer cutting block such that the anterior flange of the prosthesis will generally fit flush with the anterior cortex of the femur. When the sizing device indicates a whole size, 8 mm will be resected from the posterior condyles, corresponding to the posterior condyle thickness of the prosthesis. The serrated edges of the drill guide show the M/L dimensions of the femoral component.



Where the femur measures between sizes, a decision needs to be made whether to “up-size” or “down-size” the femoral component.

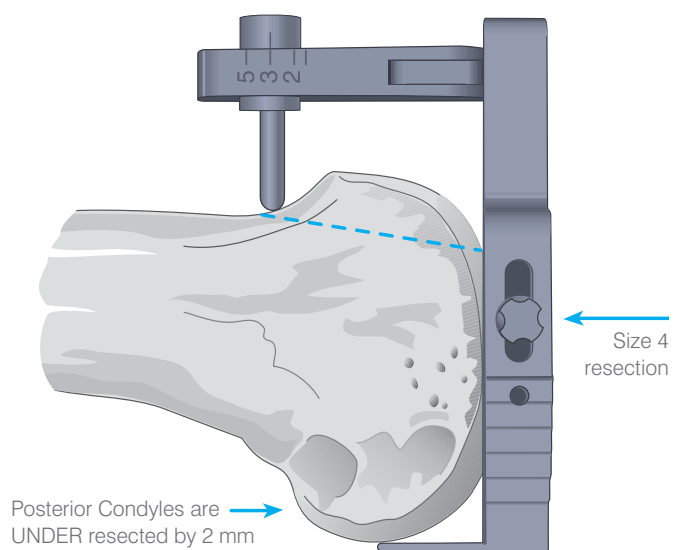
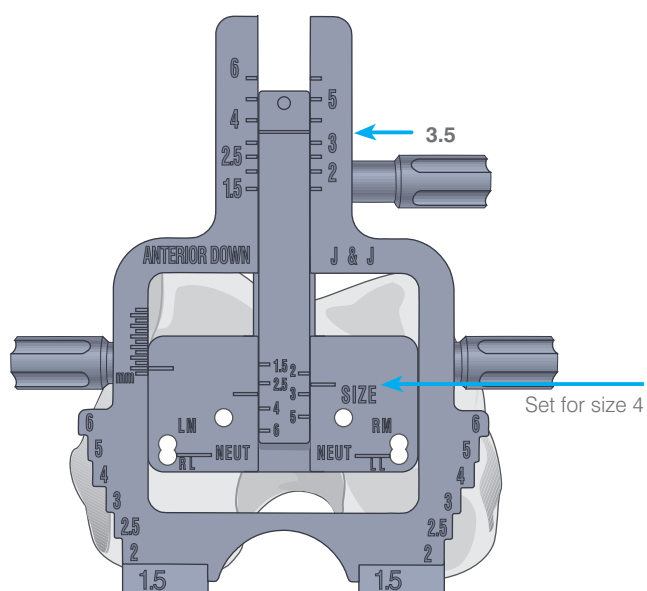
For whole sizes the guide will normally resect 8 mm from the posterior condyles, however when the femur measures between sizes, this amount of resection will vary depending on whether the femur is up-sized or down-sized.

For example if the size scale reads 3.5, and the decision is made to down-size, the drill guide is set to size 3, and a size 3 A/P cutting block is used. The guide uses the anterior cortex as a datum, the anterior cut remains constant and more bone will be resected from the posterior condyles.



If the decision is made to up-size, the drill guide needs to be set to size 4 in this example, and a size 4 A/P cutting block used. The anterior cut will remain constant, but less bone is removed from the posterior condyles.

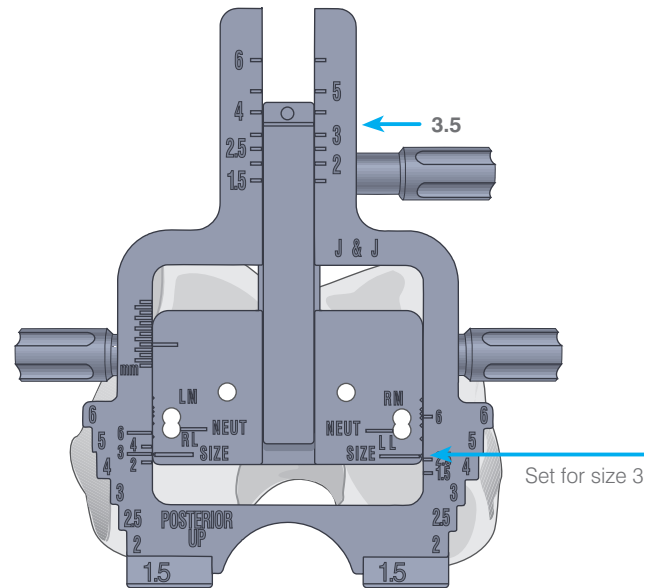
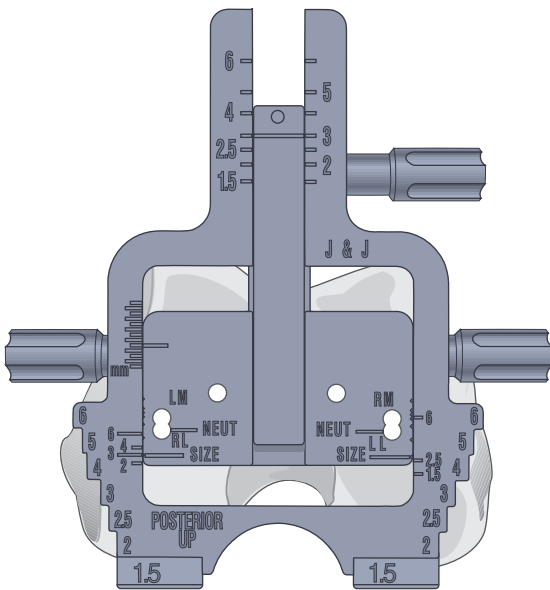
In both cases the under or over resection of the posterior condyles will affect the flexion gap, and therefore care must be taken to ensure that the flexion/extension gap is correctly balanced.





## Posterior Reference Guide

The posterior reference sizing guide measures the femur in the same way as the anterior reference guide, the sizing guide will position the femoral A/P chamfer cutting block such that 8 mm will be resected from the posterior condyles, corresponding to the posterior condyle thickness of the prosthesis. However in this case referencing takes place from the posterior condyles as opposed to the anterior cortex.

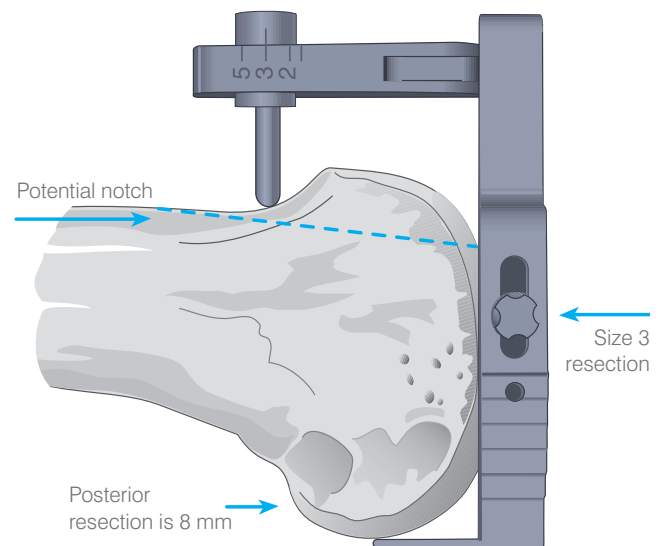


Where the femur measures between sizes, for example 3.5, there are three possible options:

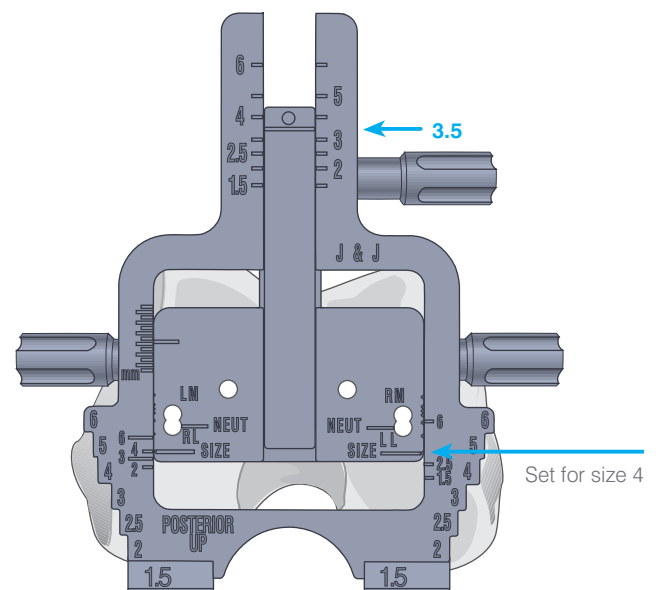
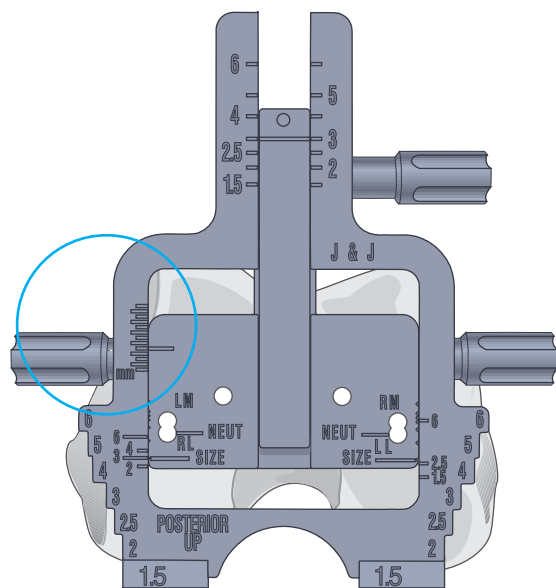
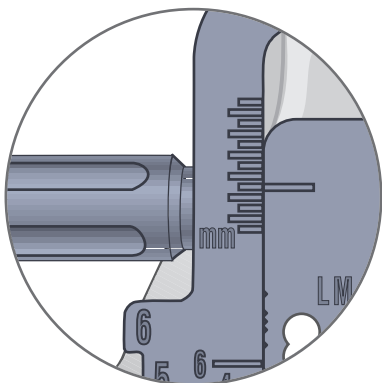
1. Down-sizing, set the drill guide to size 3 and use a size 3 cutting block.

This will give an 8 mm posterior resection

As this option increases the amount of anterior resection, care should be taken to avoid notching the anterior femoral cortex. This check can be made using the reference guide (966530) in conjunction with the A/P cutting guide.

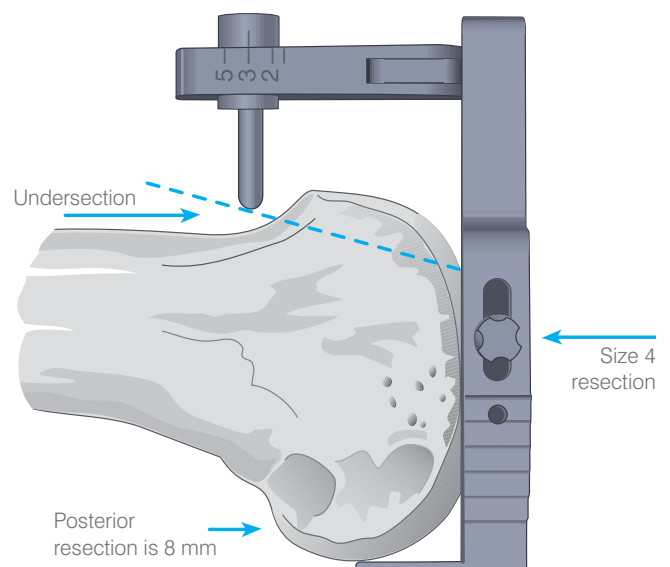


The millimetre scale on the side of the drill guide can be used to 'ease' the anterior cut by moving the drill guide anteriorly. This will increase the posterior cut and thereby the flexion gap size. Care should be taken to keep a balance between the anterior cut and the flexion space.



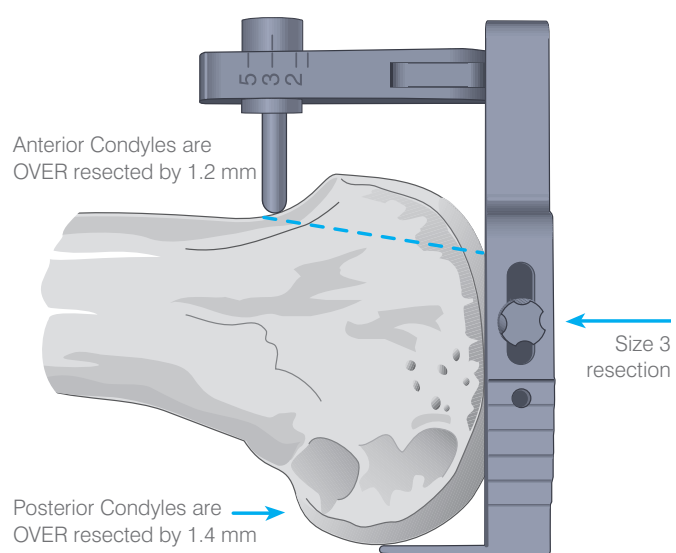
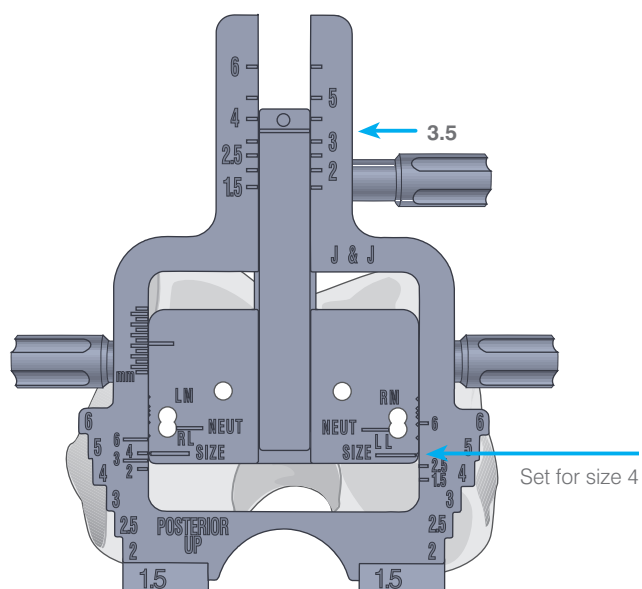
2. Up-sizing, set the drill guide size to size 4 and use a size 4 cutting block. This again will resect 8 mm from the posterior condyles but less anteriorly.

As this option decreases the amount of anterior resection, care should be taken to avoid tightness in patellar/femoral tracking which may occur with under-resection of the anterior surface of the femur.



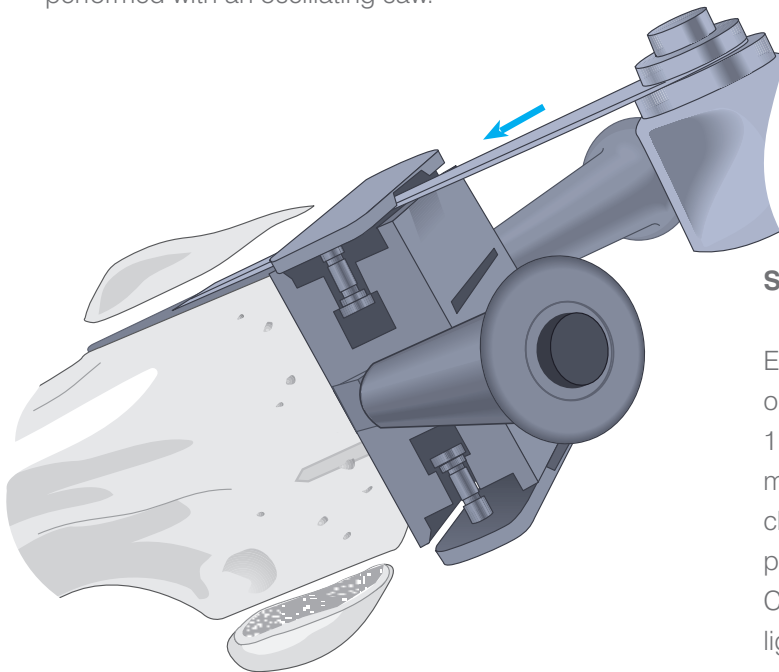
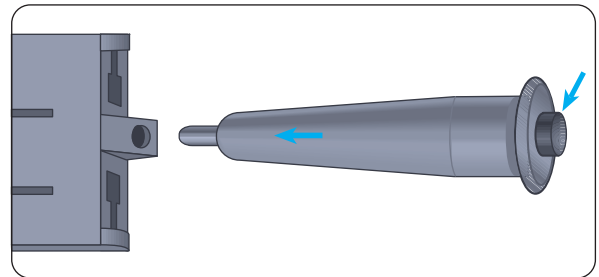
- The third option is to divide the extra bone resection involved in down sizing between the anterior and posterior cuts.

This can be achieved by setting the drill guide to 4 and using the size 3 cutting block. This will increase the posterior resection by 1.4 mm and the anterior by 1.2 mm.



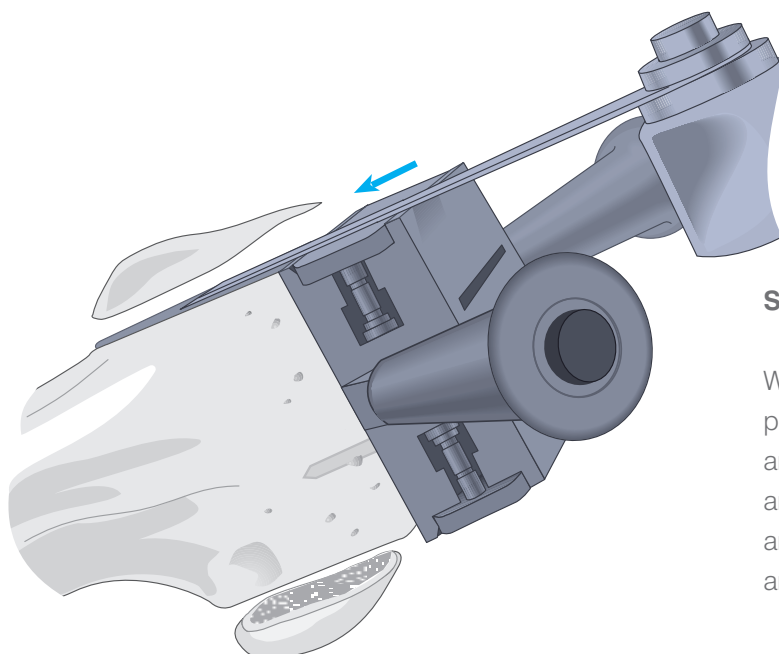
# Anterior, Posterior and Chamfer Cuts

The drill guide is removed and the corresponding A/P chamfer cutting block selected. Assemble the removable handles by depressing the button and inserting the handle into the receptacle and turning until locked into position. The A/P chamfer cutting block is seated into the drill holes and flush to the prepared surface. The anterior, posterior and chamfer cuts are performed with an oscillating saw.



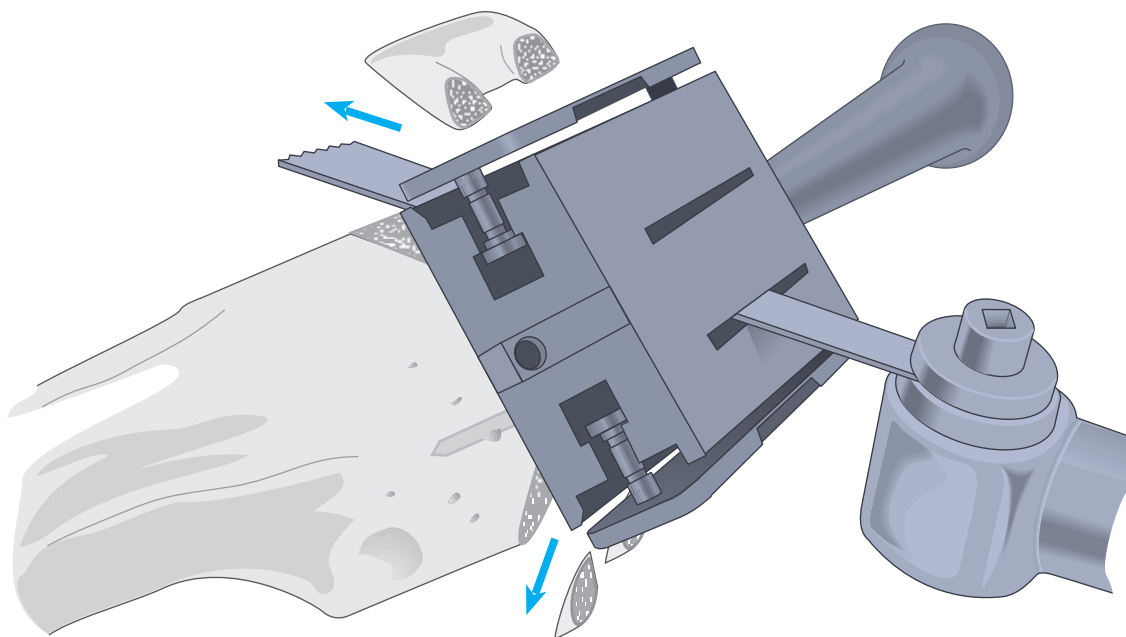
## Slotted A/P Chamfer Cutting Blocks

Extend the anterior and posterior plates to create slots on the block. Insert the blade of the oscillating saw (a 1.19 mm saw blade is recommended) to the femur and make the anterior and posterior cuts. The anterior chamfer cut is made through the posterior slot and the posterior chamfer cut is made through the anterior slot. Care is taken that the posterior cruciate and collateral ligaments are protected.

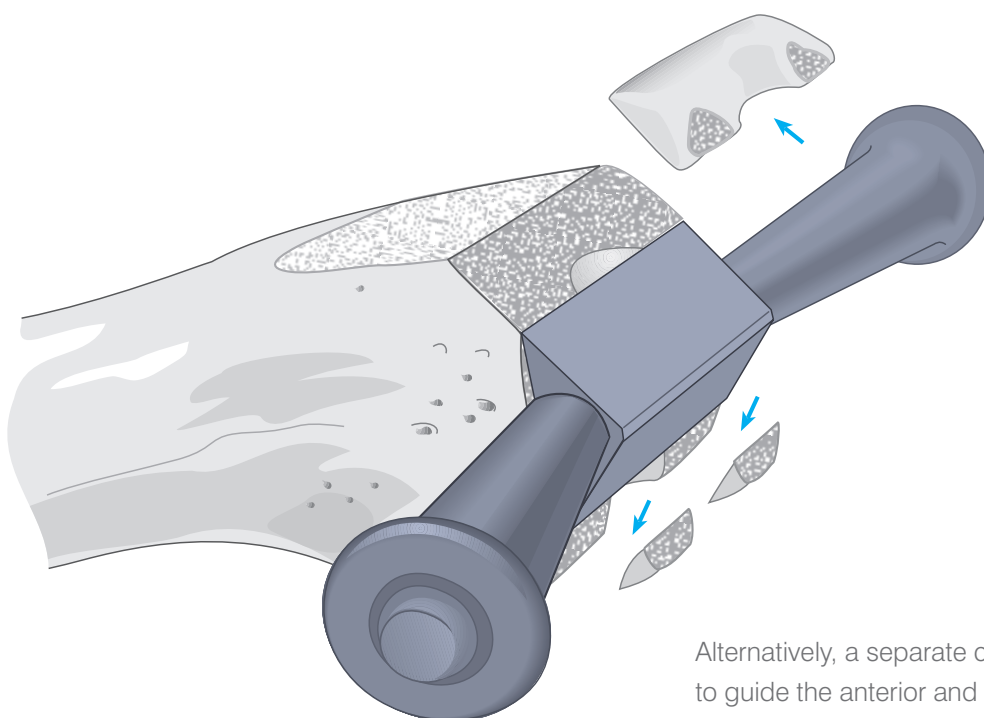


## Surface A/P Chamfer Cutting Blocks

With the anterior and posterior plates in their retracted position, make the anterior and posterior cuts. The anterior chamfer cut is made through the posterior slot and the posterior chamfer cut is made through the anterior slot. Care is taken that the posterior cruciate and collateral ligaments are protected.



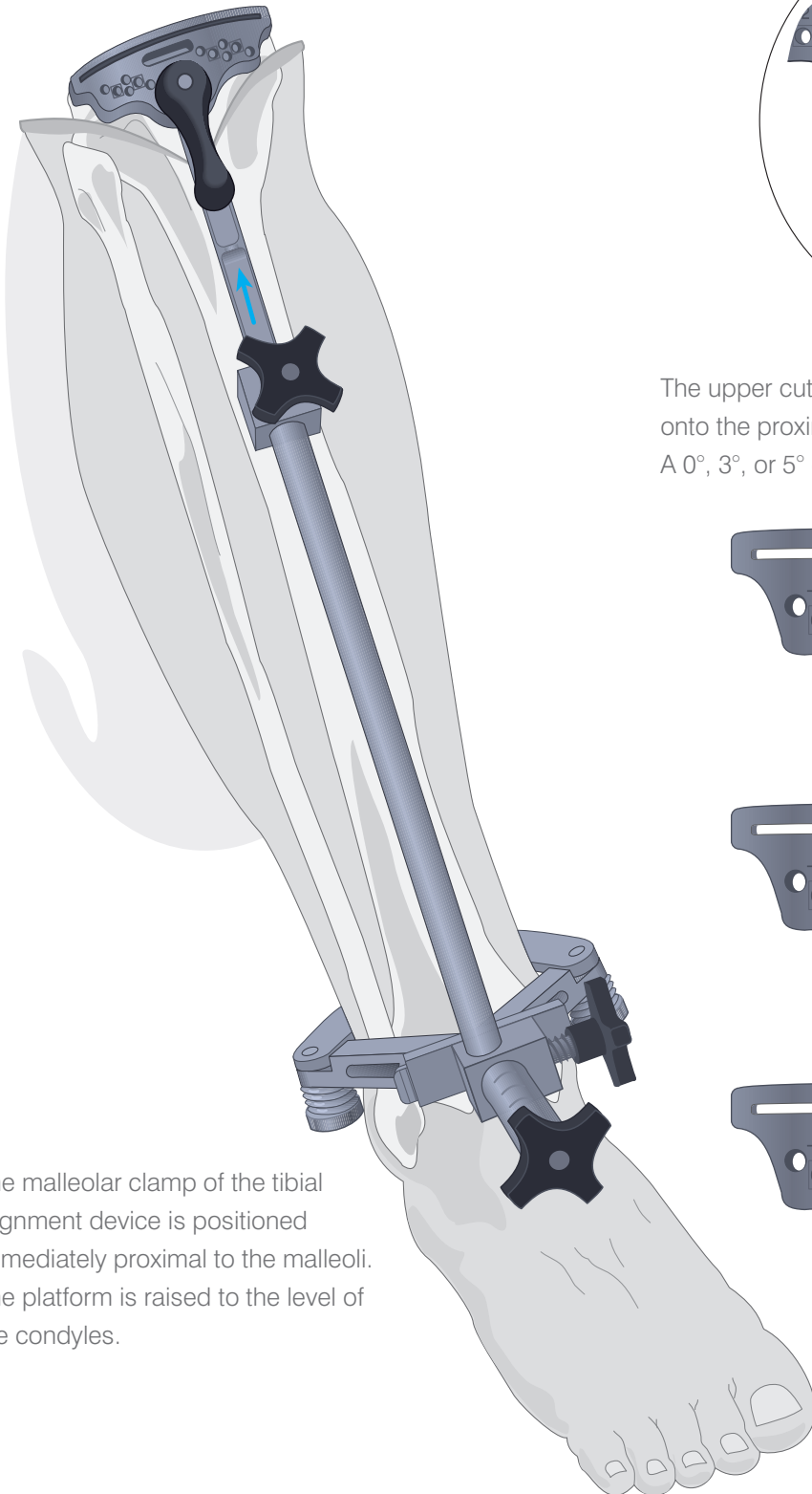
The chamfers are made through the slotted A/P block.



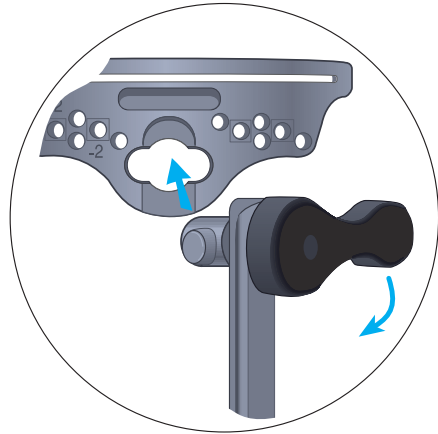Alternatively, a separate chamfer block can be used to guide the anterior and posterior chamfer resections.

# Tibial Alignment

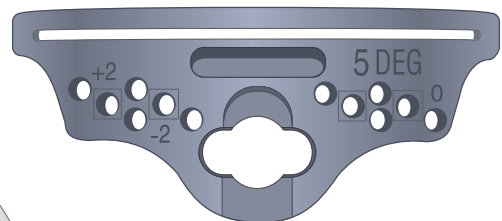
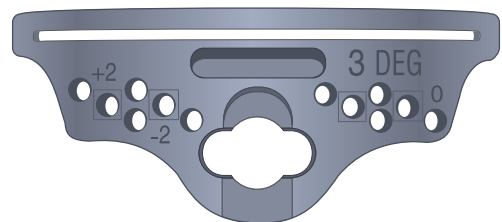
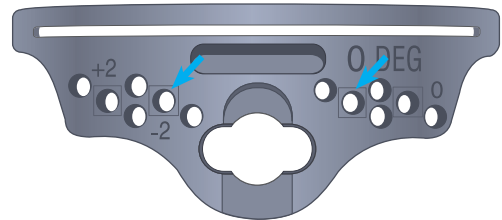
The knee is placed in maximal flexion with the tibia distracted anteriorly and stabilised.



The malleolar clamp of the tibial alignment device is positioned immediately proximal to the malleoli. The platform is raised to the level of the condyles.

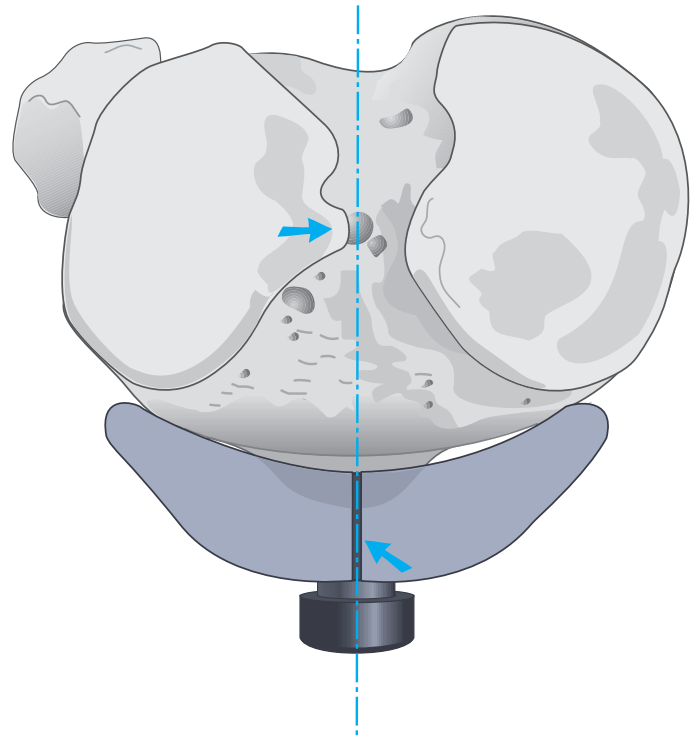


The upper cutting platform is assembled and secured onto the proximal uprod of the tibial alignment device. A 0°, 3°, or 5° cutting block can be chosen.

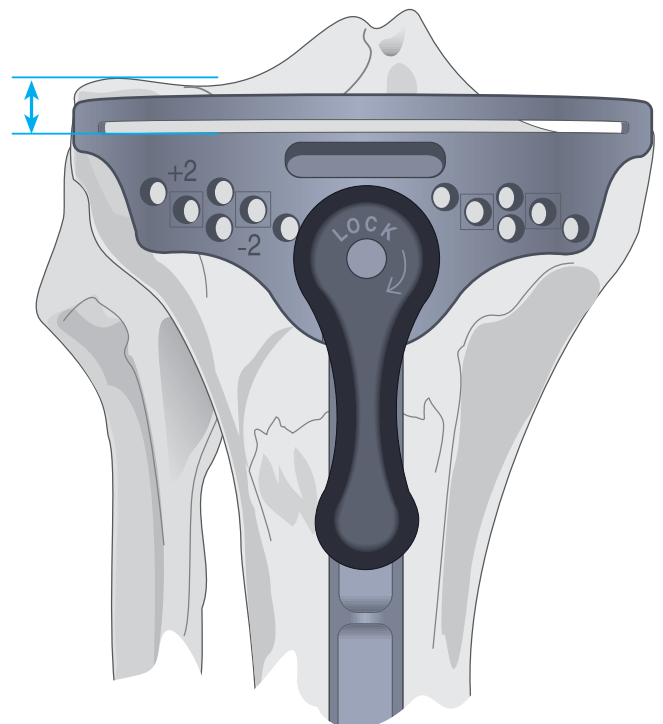


# The Upper Platform

The upper platform is aligned with the medial third of the tibial tubercle and medial margin of the lateral intercondylar eminence with the extremities of the cutting surface against the anterior cortex.

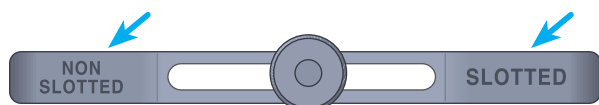


The exact level of resection will vary according to patient anatomy. As the mediolateral transverse plane of the tibial plateau is usually 3° from the perpendicular and the projected cut is perpendicular to the anatomic axis, more bone is typically removed from the lateral condyle.



# The Tibial Stylus

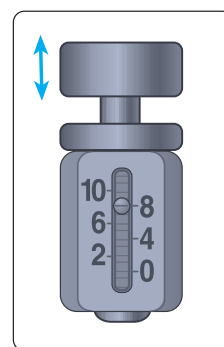
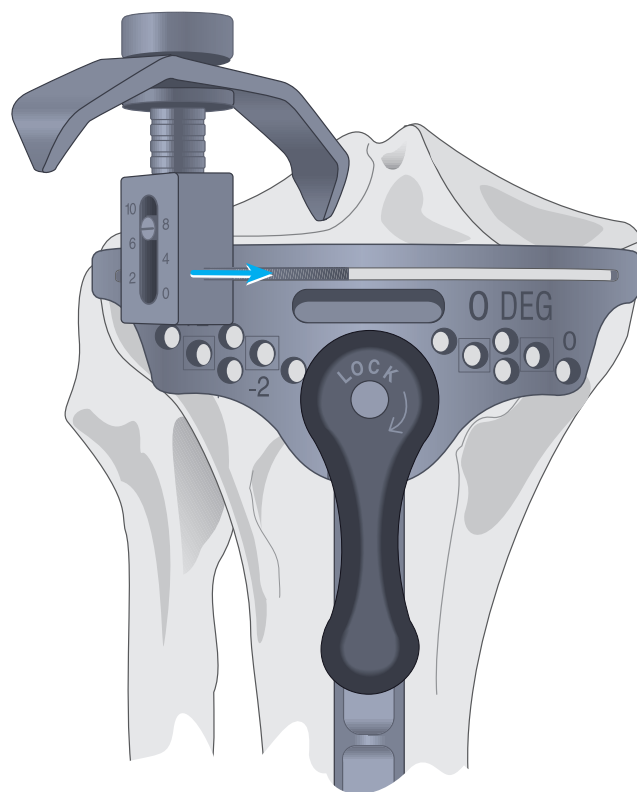
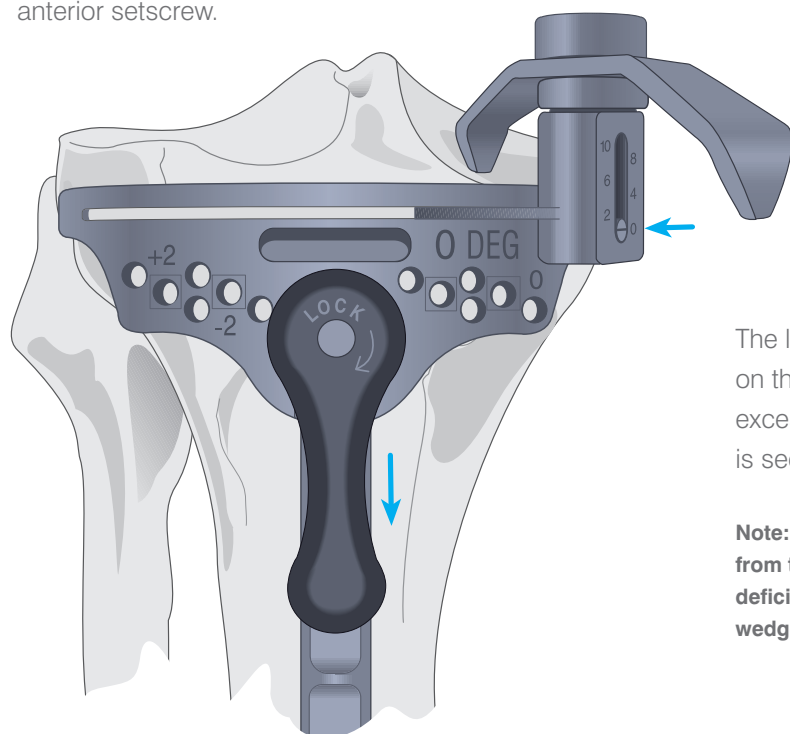
The stylus determines the exact level of resection.



The outrigger of the stylus is marked non-slotted and slotted at either end. When the tibial resection is performed from the surface of the block, choose the non-slotted end of the outrigger; conversely, when the resection is performed through the slots, choose the slotted end of the outrigger. There is a 4 mm difference between the top surface and the slot.

The cylinder foot is inserted into the slot of the cutting block and adjusted to the appropriate level. It is calibrated in 2 mm increments, indicating the amount of bone and residual cartilage to be resected.

A level of 8 mm or 10 mm is suggested where resection is based on the less involved condyle. The block is adjusted such that the stylus rests on the centre of the condyle and the cutting block is secured by the large anterior setscrew.

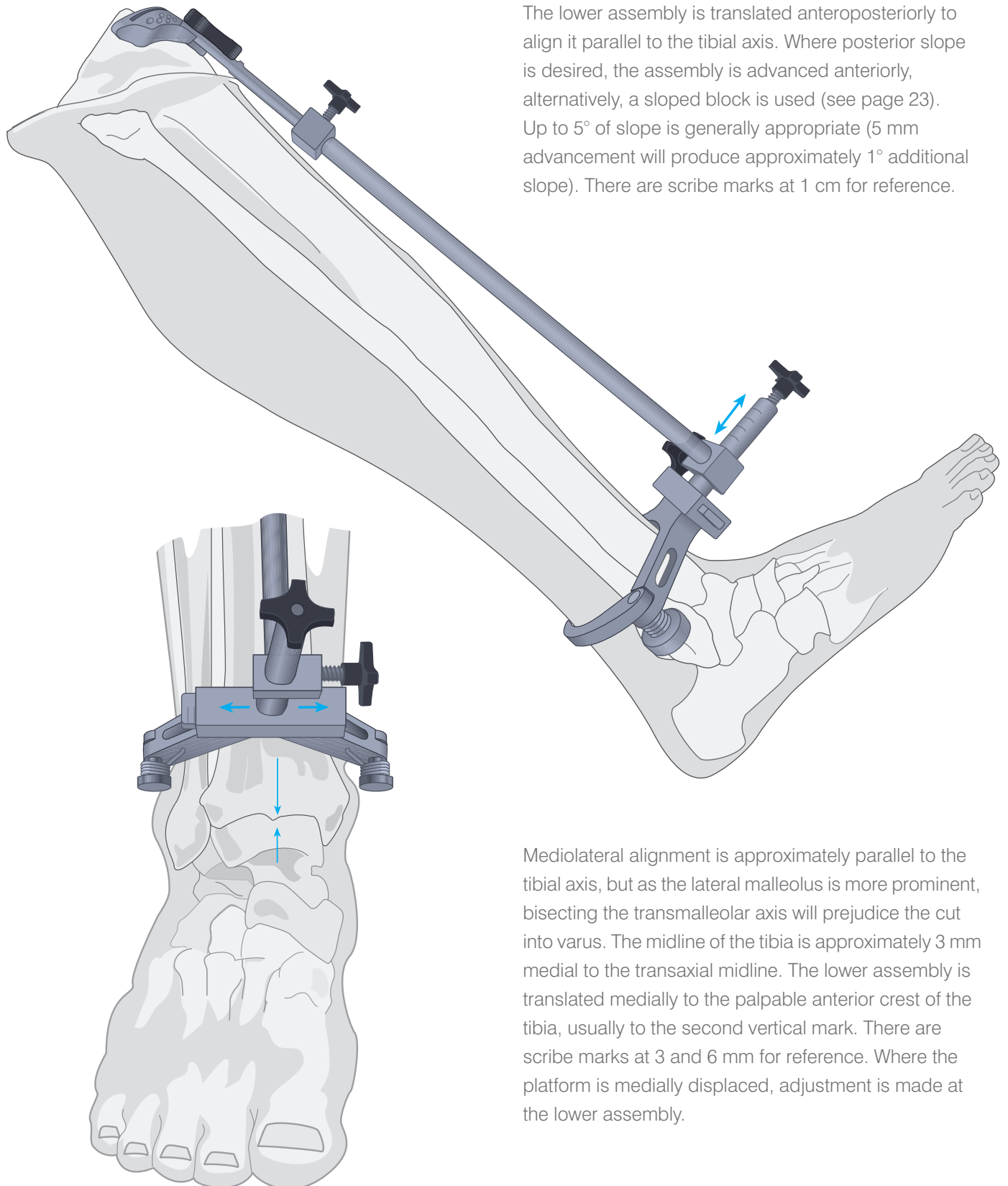


The level of 0 is selected where resection is based on the more involved condyle and does not result in excessive contralateral resection. The cutting block is secured by the large anterior setscrew.

**Note:** Where this indicates greater than 10 mm of resection from the contralateral condyle, a higher level is indicated. The deficiency is augmented with cement, bone graft or a modular wedge, as the situation dictates.



# Lower Alignment

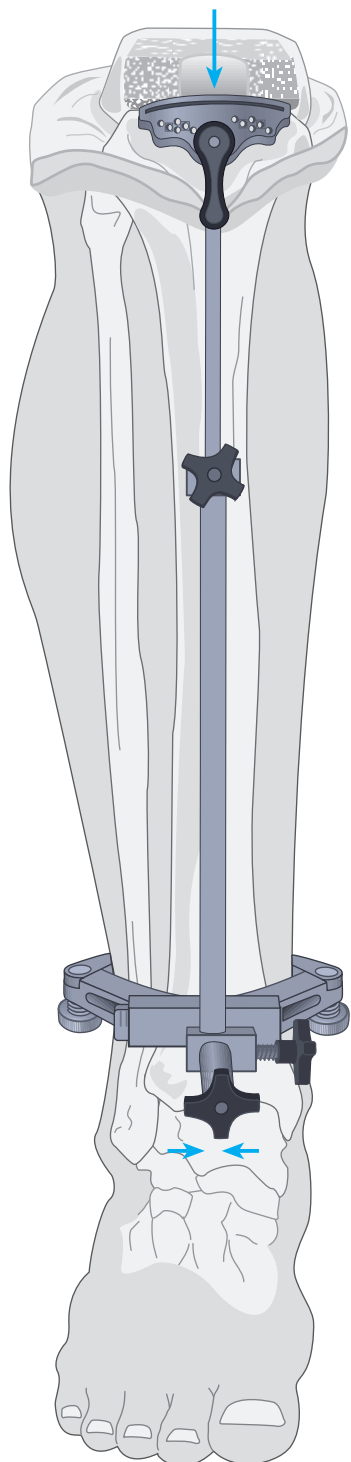


The lower assembly is translated anteroposteriorly to align it parallel to the tibial axis. Where posterior slope is desired, the assembly is advanced anteriorly, alternatively, a sloped block is used (see page 23). Up to 5° of slope is generally appropriate (5 mm advancement will produce approximately 1° additional slope). There are scribe marks at 1 cm for reference.

Mediolateral alignment is approximately parallel to the tibial axis, but as the lateral malleolus is more prominent, bisecting the transmalleolar axis will prejudice the cut into varus. The midline of the tibia is approximately 3 mm medial to the transaxial midline. The lower assembly is translated medially to the palpable anterior crest of the tibia, usually to the second vertical mark. There are scribe marks at 3 and 6 mm for reference. Where the platform is medially displaced, adjustment is made at the lower assembly.

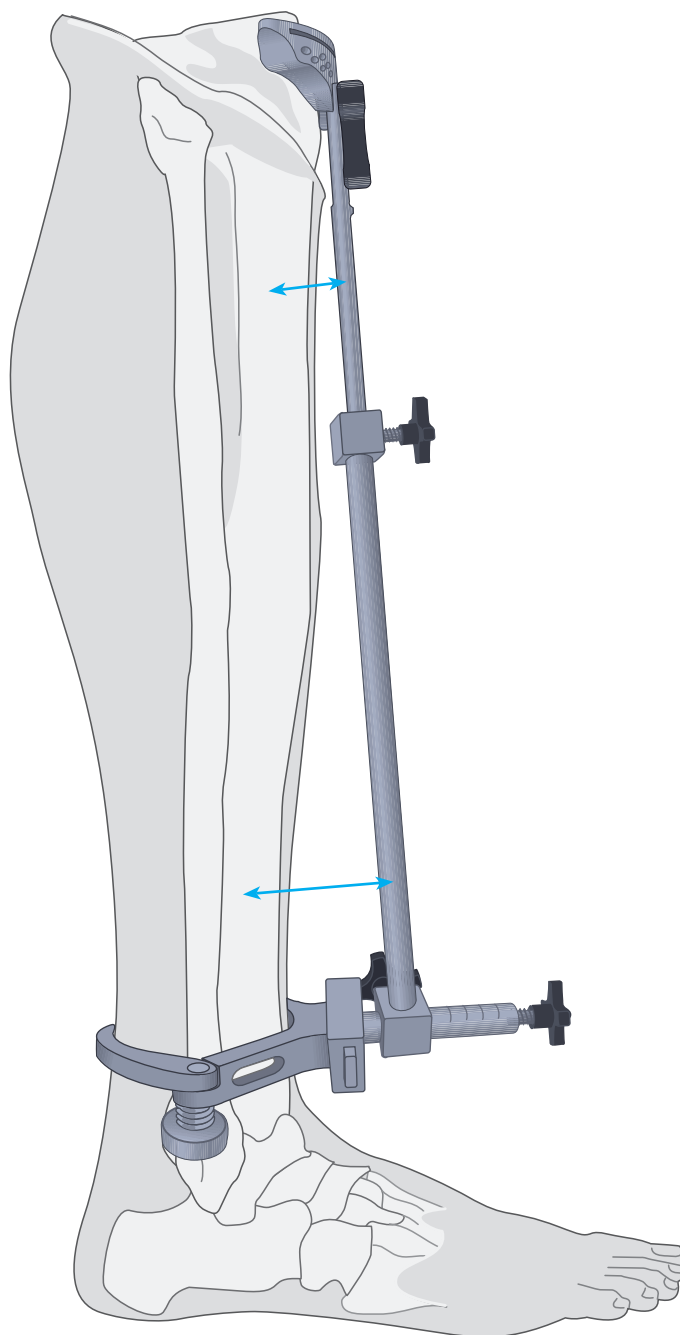
# The Tibial Alignment

The distal portion of the long arm of the tibial alignment device should align with the centre of the talus.



Lateral alignment is similarly confirmed.

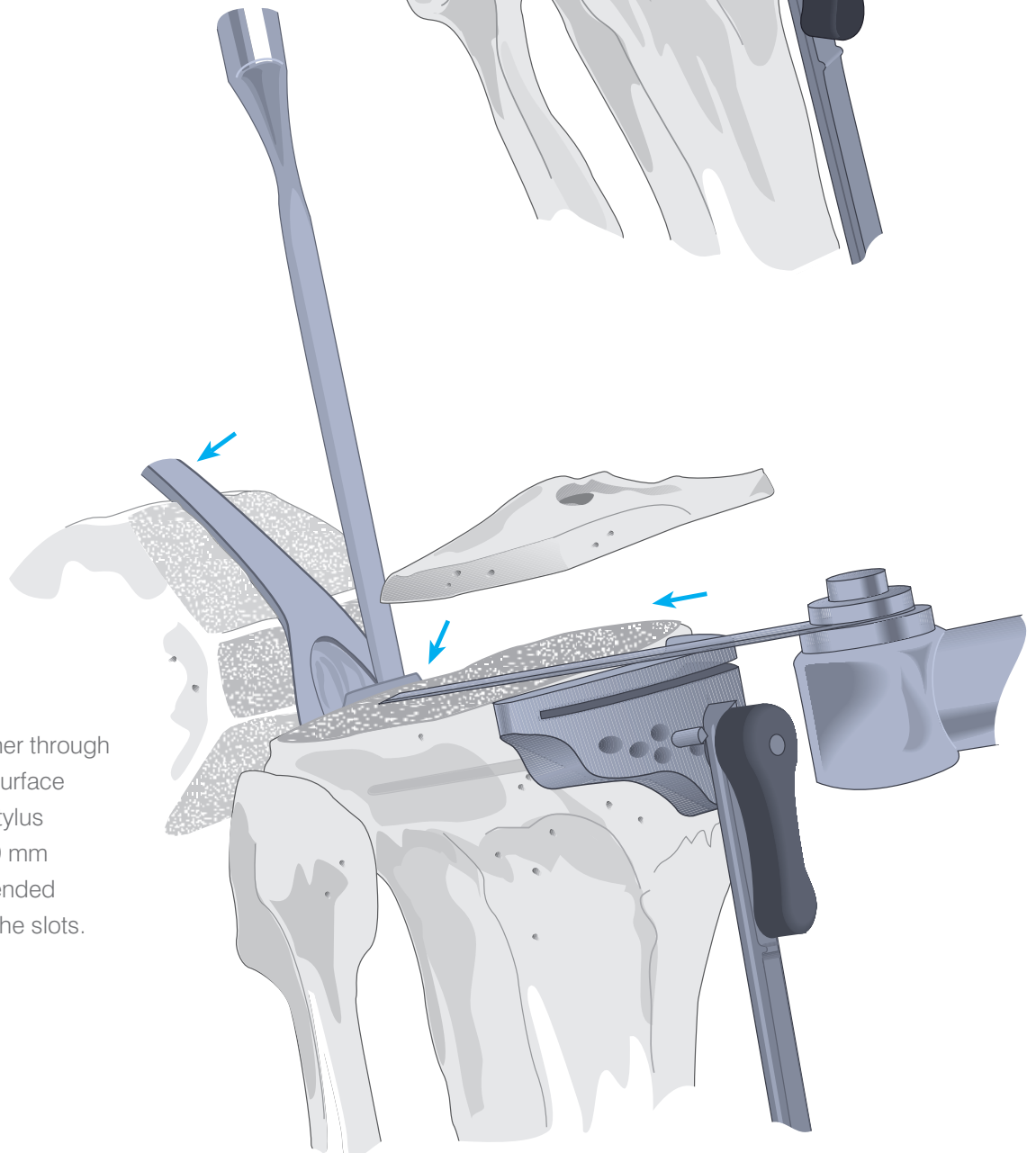
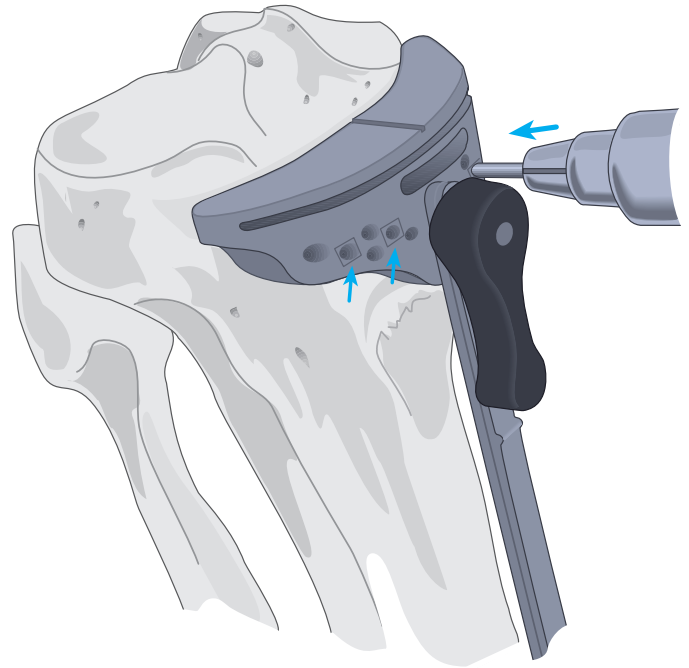
**Note:** Where indicated, varus/valgus corrections are made by sliding the distal portion of the tibial alignment to the appropriate location.



# Securing the Platform and Tibial Resection

Steinmann pins or  $\frac{1}{8}$ " drill bits are introduced through the central holes marked with a □, into the tibia stopping well short of the posterior cortex. The tibial alignment device can either be removed by first unlocking the cutting block, or left in place for additional stability.

An entry slot is cut with a narrow oscillating saw into the intercondylar eminence anterior to the attachment of the PCL and an osteotome positioned to shield the ligament.



Resection is made either through the slot or on the top surface depending upon the stylus reference used. A 1.19 mm saw blade is recommended when cutting through the slots.

# Patellar Resurfacing

It is important that the sagittal dimension and accurate tracking are maintained and that adequate bone stock is preserved. Problems will arise from inadequate or oblique resection resulting in greater thickness to the complex, asymmetric positioning of the implant, subsequent patellar tilt and implant wear.

It is important that sufficient soft tissue be freed at the prepatellar bursa to position the calipers at the anterior cortex.

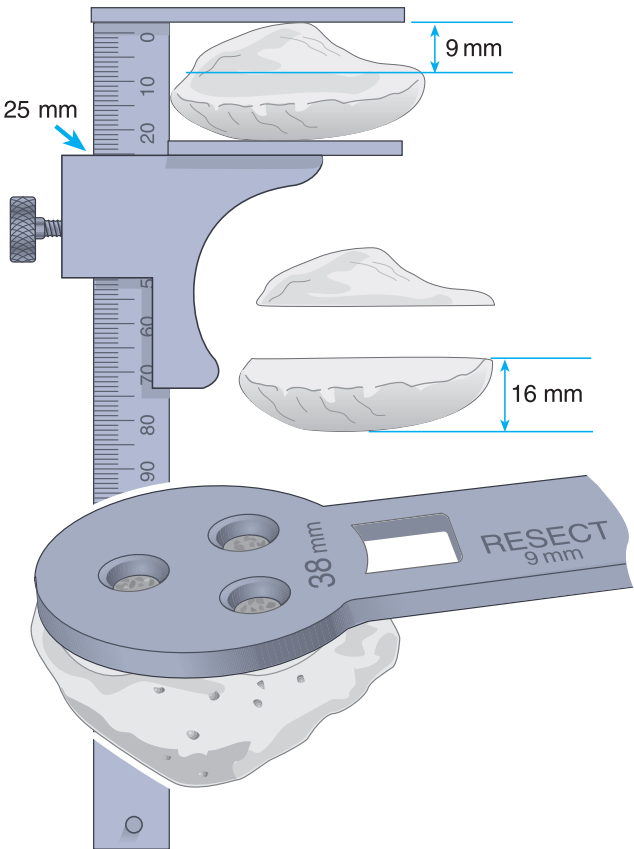
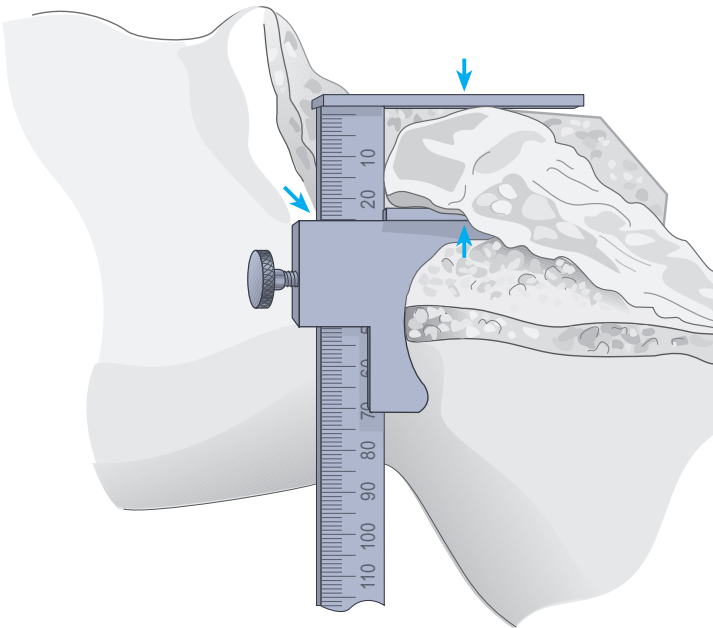
The greatest sagittal dimension is at the median ridge. The normal range is 20-30 mm. The dimension is established and an amount corresponding to the size of the selected implant subtracted. The remainder equals the target dimension following resection. Where the patella is small, a minimal residual dimension of 12 mm should be maintained.

**Example:** (for a 38 mm size dome or oval/dome patella) From a patella 25 mm thick, 9 mm of articular surface is resected, yielding 16 mm of residual bone to accommodate the 9 mm thick implant.

The template is selected that most adequately covers the articular surface without overhang. The handle is positioned on the medial side of the everted patella. Where bone is deficient on the lateral side, the next smaller size is selected, but positioned slightly to the medial side to enhance patellar tracking.

The amount of appropriate bone resection, as indicated on the template, is noted.

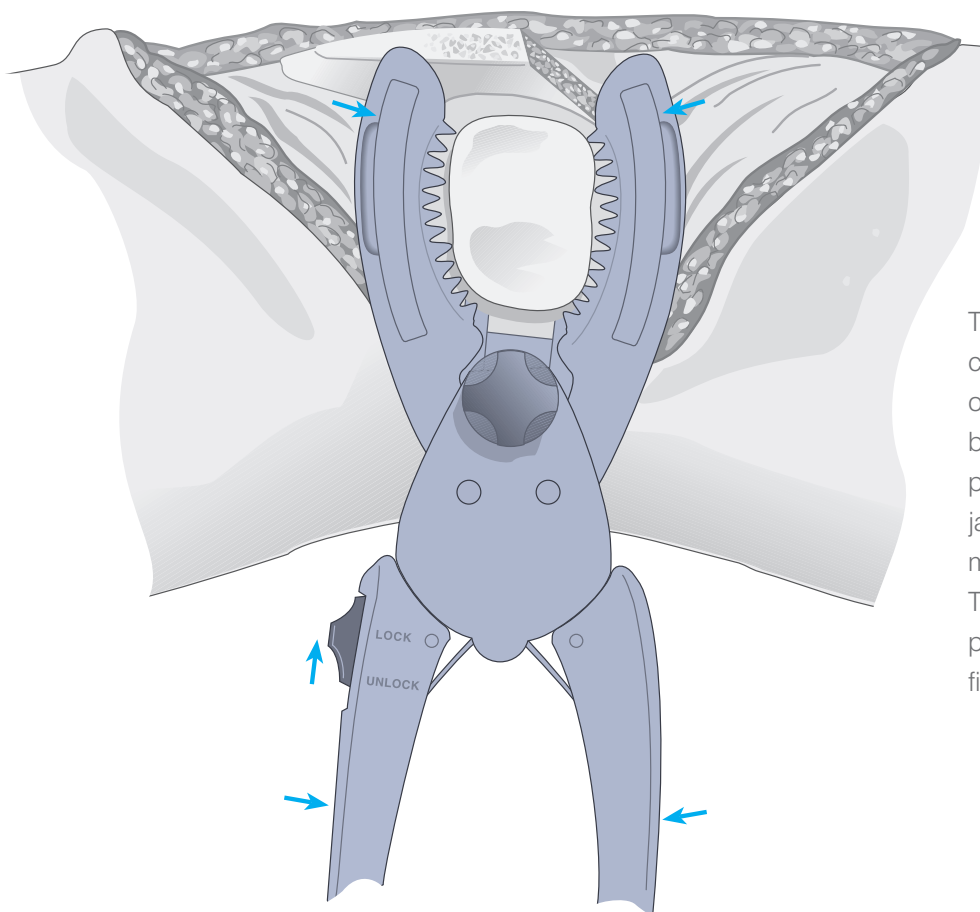
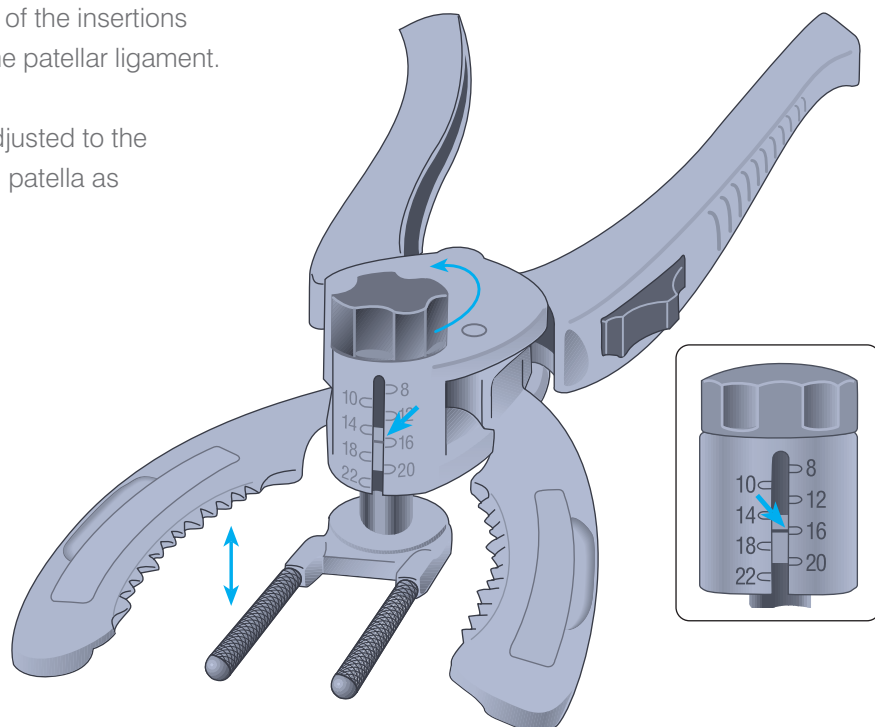
Patellar size	Resection
32 mm	8.0 mm
35 mm	8.5 mm
38 mm	9.0 mm
41 mm	11.5 mm



# The Patellar Cutting Guide

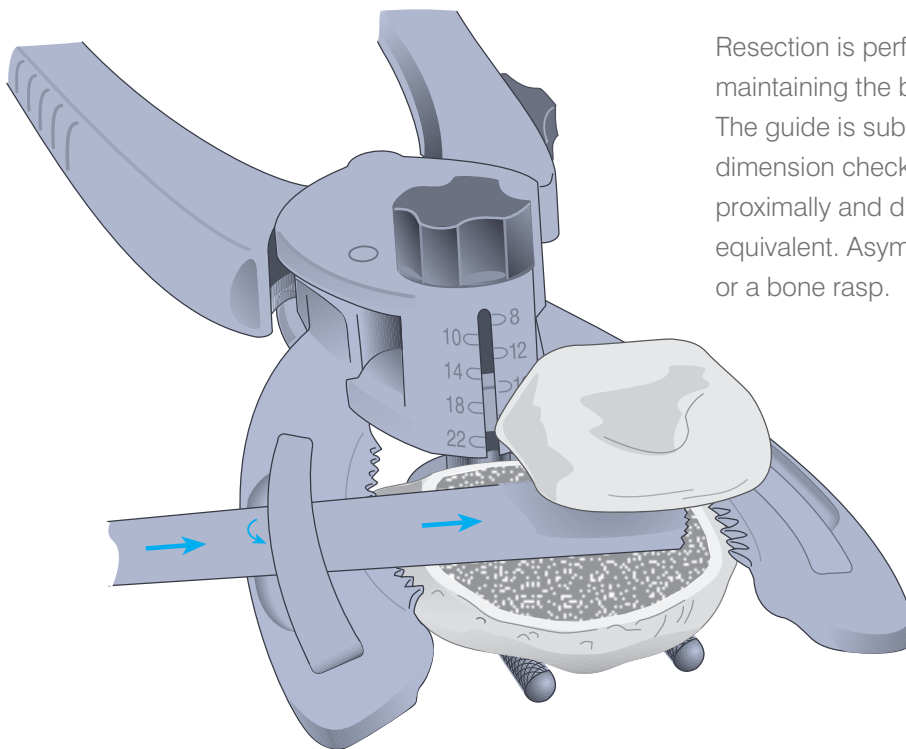
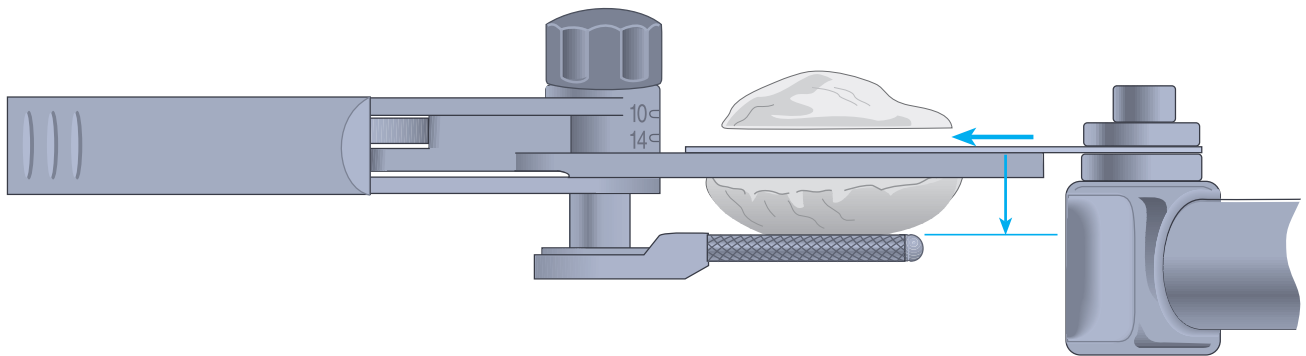
Synovial tissue is cleared to the level of the insertions of the quadriceps mechanism and the patellar ligament.

The prongs of the knurled fork are adjusted to the predetermined dimension of residual patella as indicated on the calibrated column.



The leg is placed in extension, the cutting guide positioned with prongs of the fork deep to the prepatellar bursa and against the anterior patellar cortex with the serrated jaws at the superior and inferior margins of the articular surface. The switch is placed to the LOCK position and the jaws closed to firmly engage the patella.

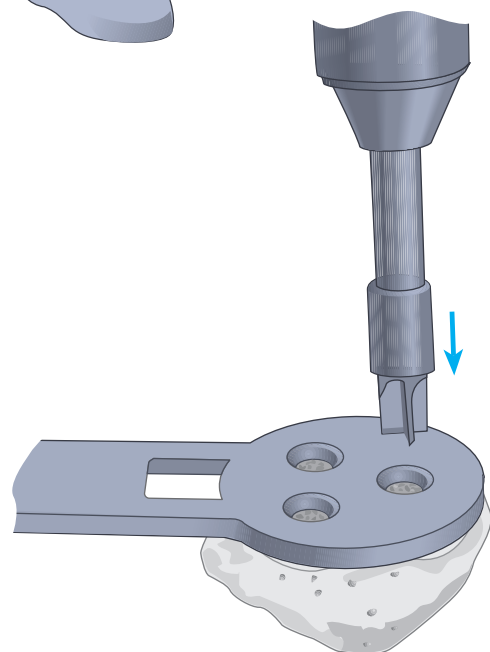
# Resection and Drilling



Resection is performed with an oscillating saw, maintaining the blade flush to the cutting surface. The guide is subsequently removed and the residual dimension checked with calipers, laterally, medially, proximally and distally. All measurements should be equivalent. Asymmetry is addressed with the saw or a bone rasp.

Alternatively, the saw blade is inserted into the well of the cutting surface of either of the jaws. The insert is lifted and the blade thereby confined within the slot created, ensuring that the cut will remain flush to the cutting surface. A 1.19 mm saw blade is recommended.

The previously selected template is positioned onto the cut surface with the handle positioned on the medial side of the everted patella, such that two drill holes lie at the medial side, one at the lateral. The template is firmly engaged to the resected surface and holes fashioned with the appropriate drill bit.

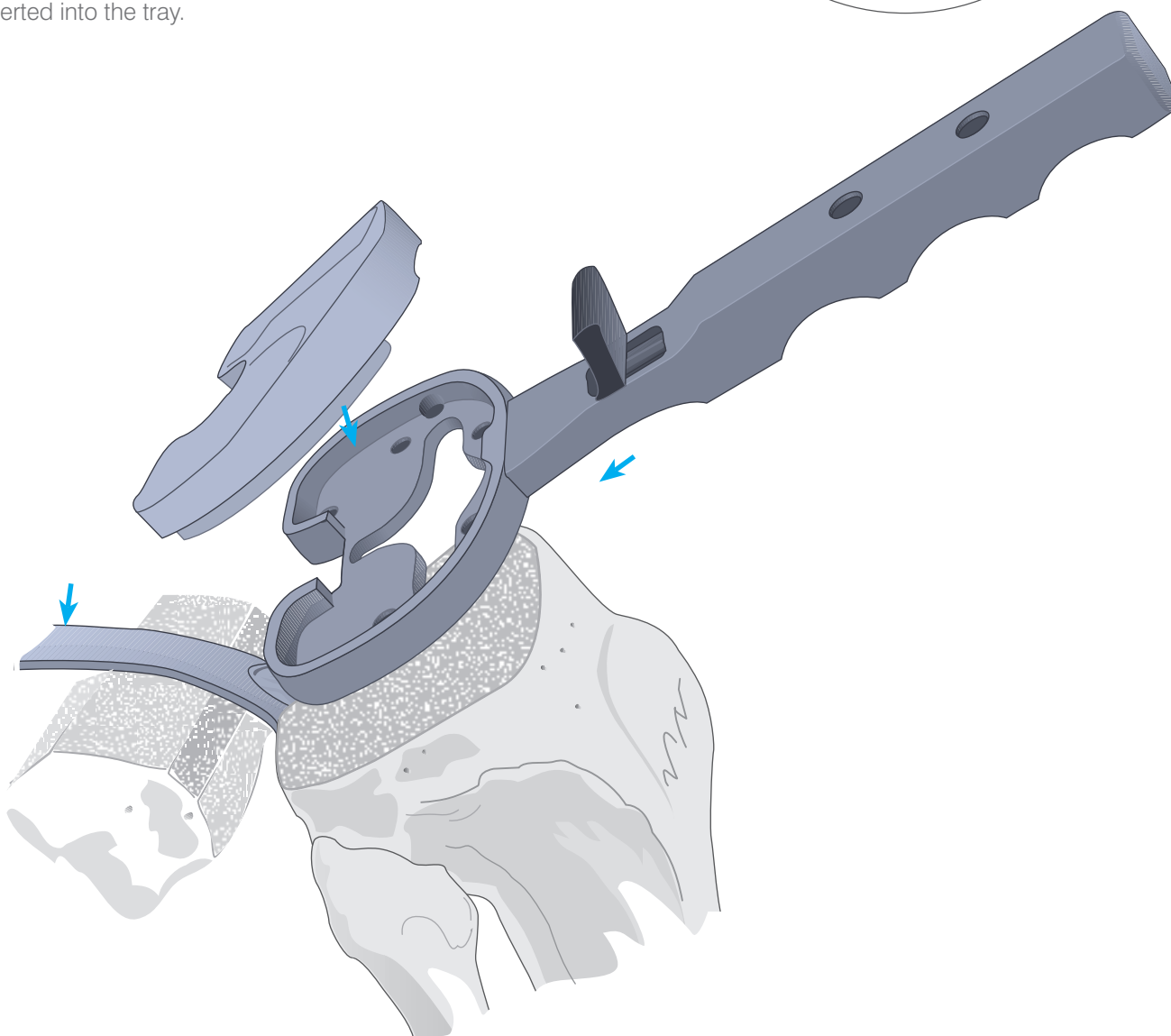
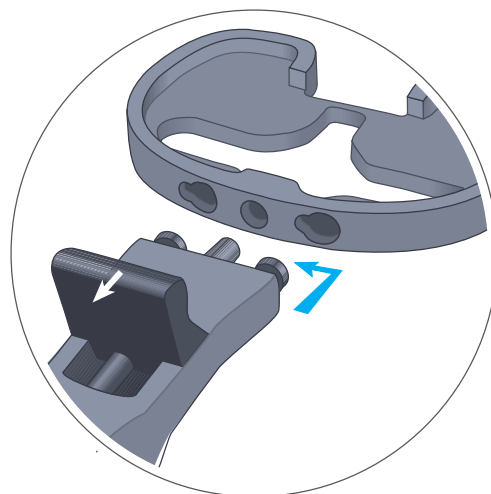

# The Trial Tibial Component

The knee is placed in maximal flexion, the tibia subluxed anteriorly with the tibial retractor. The tibial tray is selected which provides the greatest coverage of the prepared surface without overhang anterior to the midcoronal plane.

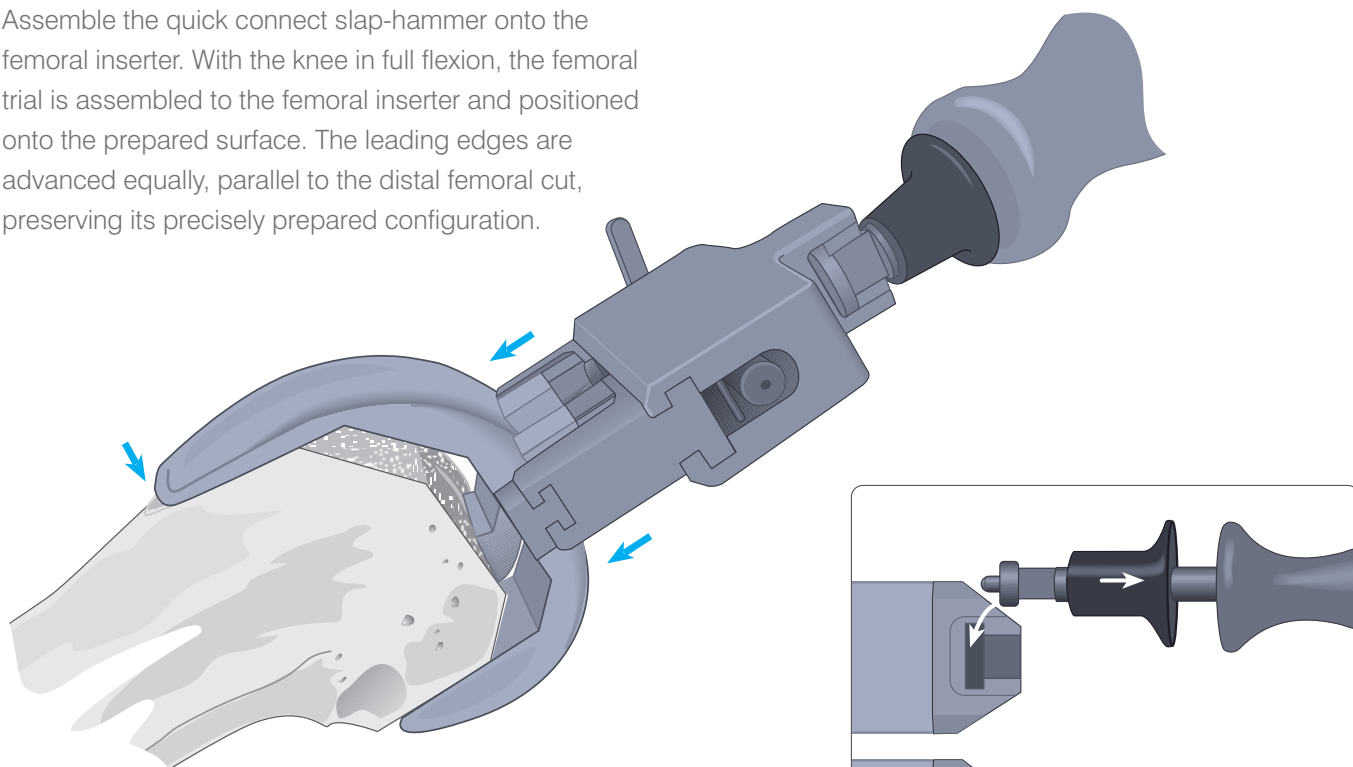
The tibial tray alignment handle is connected to the tibial tray trial by retracting the knob, inserting the two pins into the anterior portion of the tray trial, indexing the handle to the left and releasing the knob.

The matching colour-coded plastic trial is selected and inserted into the tray.

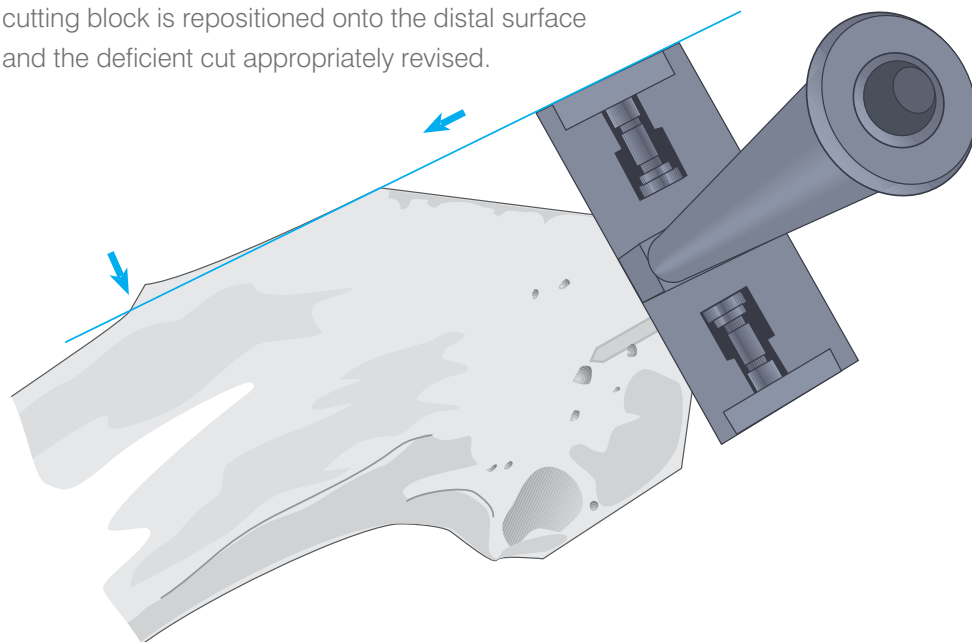


# The Trial Femoral Component

Assemble the quick connect slap-hammer onto the femoral inserter. With the knee in full flexion, the femoral trial is assembled to the femoral inserter and positioned onto the prepared surface. The leading edges are advanced equally, parallel to the distal femoral cut, preserving its precisely prepared configuration.



Where there is a tendency for the trial to rock posteriorly (into flexion), the most common cause is upward sloping of the anterior cut or failure to resect adequately at the anterior aspect. Less commonly, the posterior condyles have been under-resected. The A/P chamfer cutting block is repositioned onto the distal surface and the deficient cut appropriately revised.

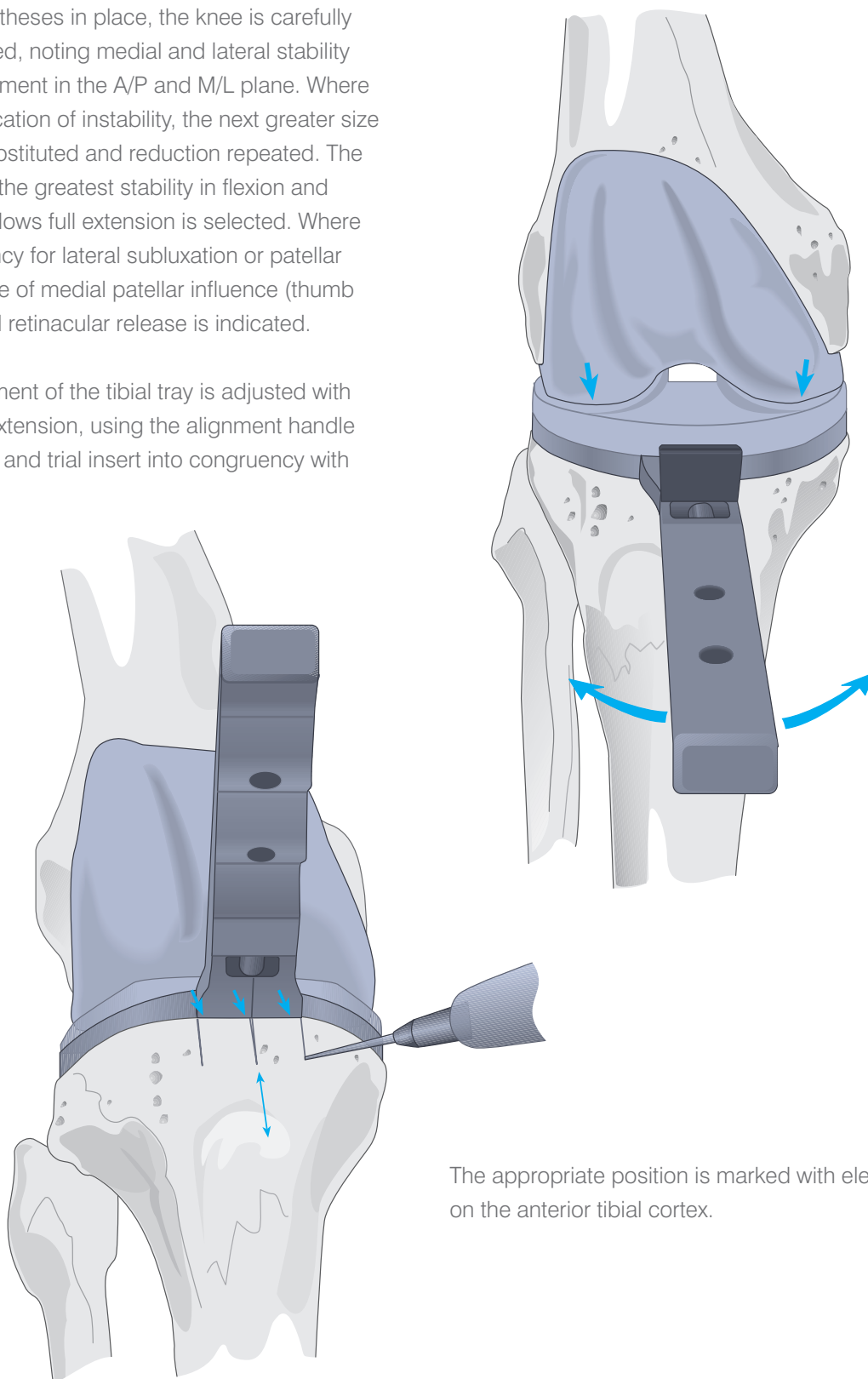




# Trial Reduction

With all trial prostheses in place, the knee is carefully and fully extended, noting medial and lateral stability and overall alignment in the A/P and M/L plane. Where there is any indication of instability, the next greater size tibial insert is substituted and reduction repeated. The insert that gives the greatest stability in flexion and extension and allows full extension is selected. Where there is a tendency for lateral subluxation or patellar tilt in the absence of medial patellar influence (thumb pressure), lateral retinacular release is indicated.

Rotational alignment of the tibial tray is adjusted with the knee in full extension, using the alignment handle to rotate the tray and trial insert into congruency with the femoral trial.

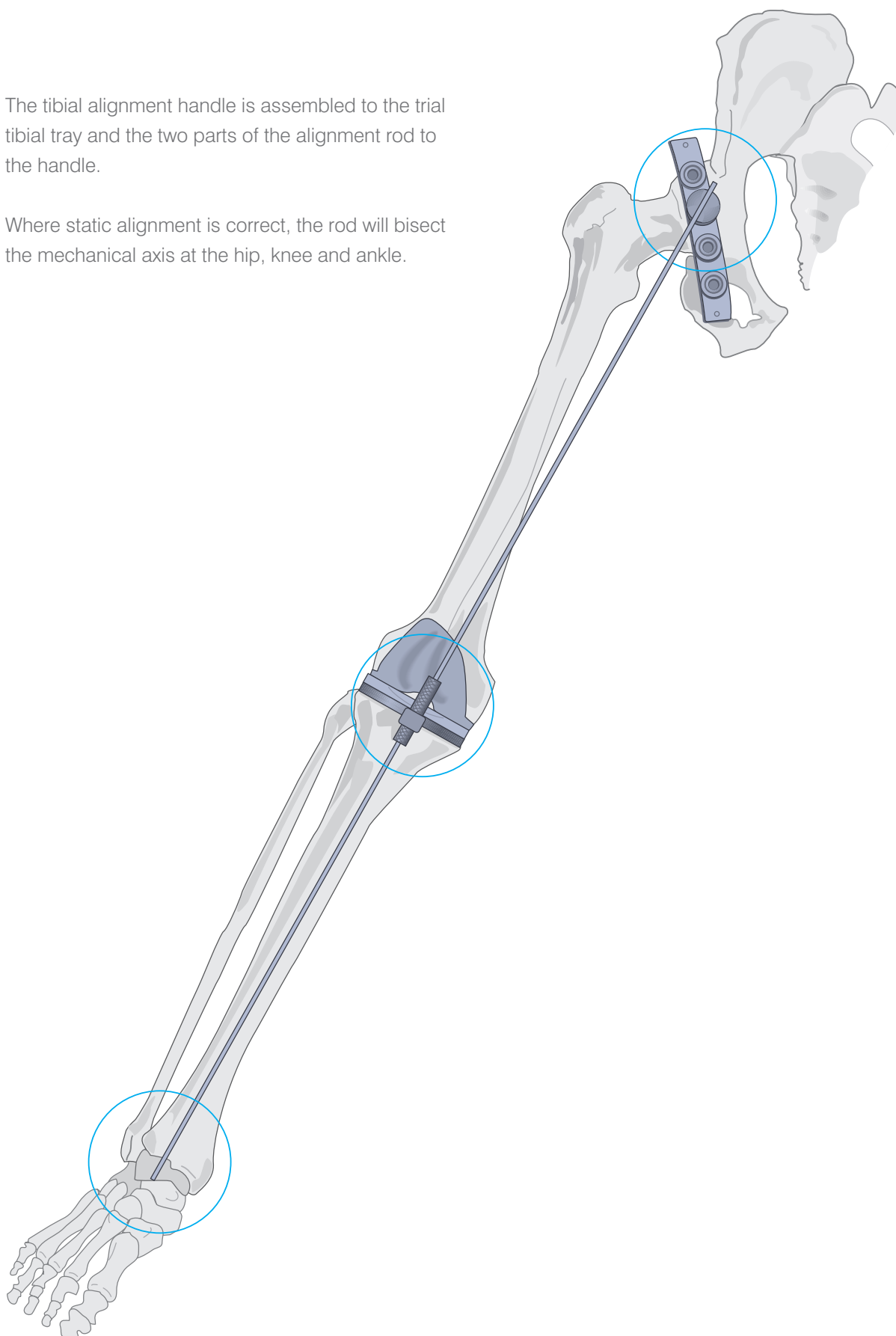


The appropriate position is marked with electrocautery on the anterior tibial cortex.

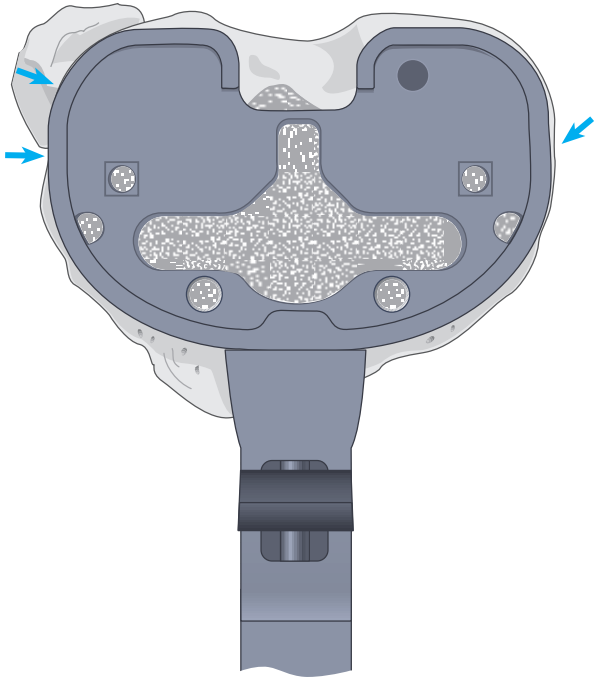
# Overall Alignment

The tibial alignment handle is assembled to the trial tibial tray and the two parts of the alignment rod to the handle.


Where static alignment is correct, the rod will bisect the mechanical axis at the hip, knee and ankle.

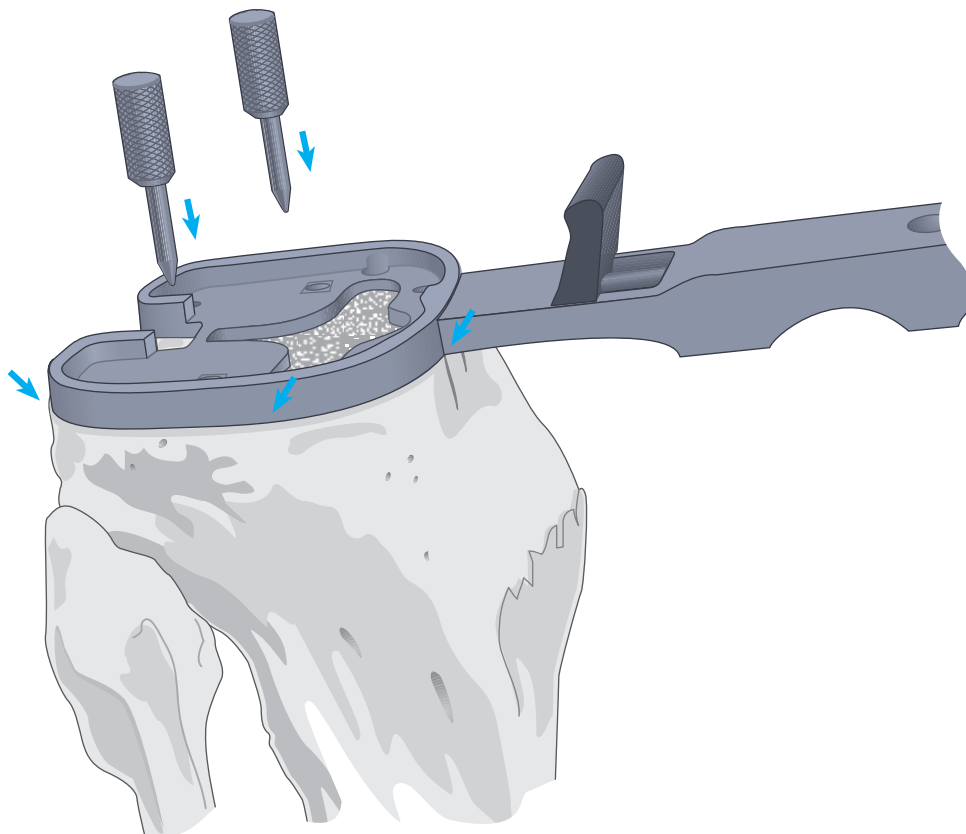


# Plateau Preparation

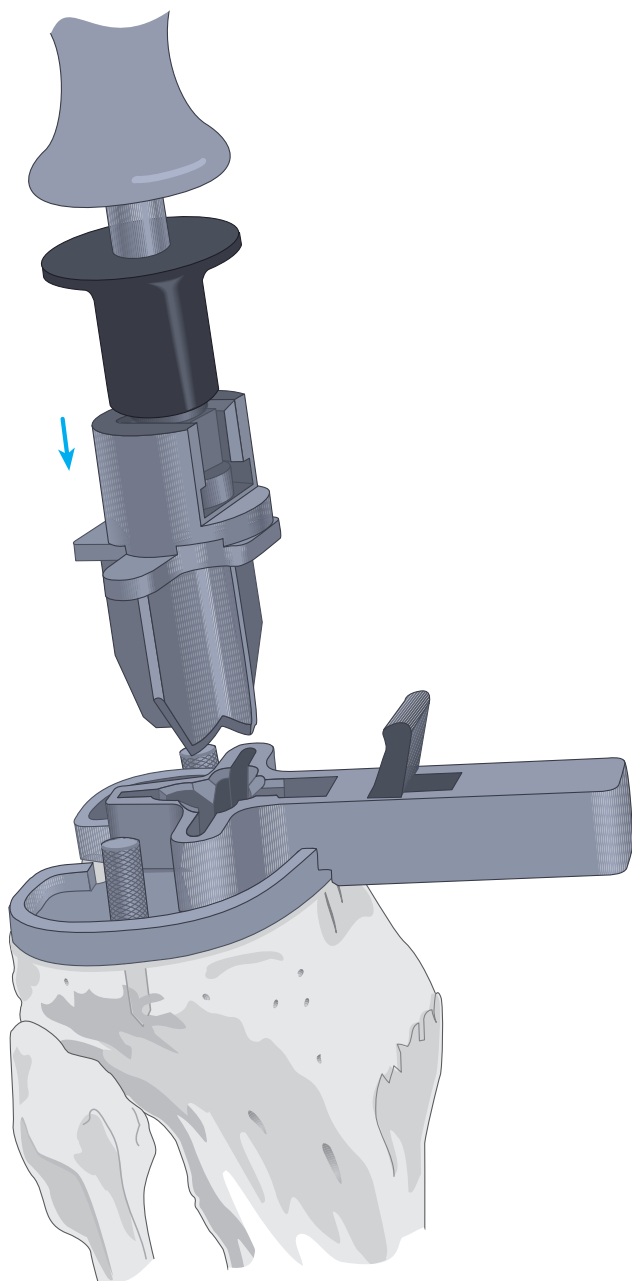


With the knee in full flexion and the tibia subluxed anteriorly, the trial tray is assembled to the alignment handle and placed onto the resected tibial surface. Care is taken that proper rotational alignment with the electrocautery marks is established.

The tray is secured with two short fixation pins inserted through the holes designated .



# P.F.C.® Cruciform Keel Tray Preparation

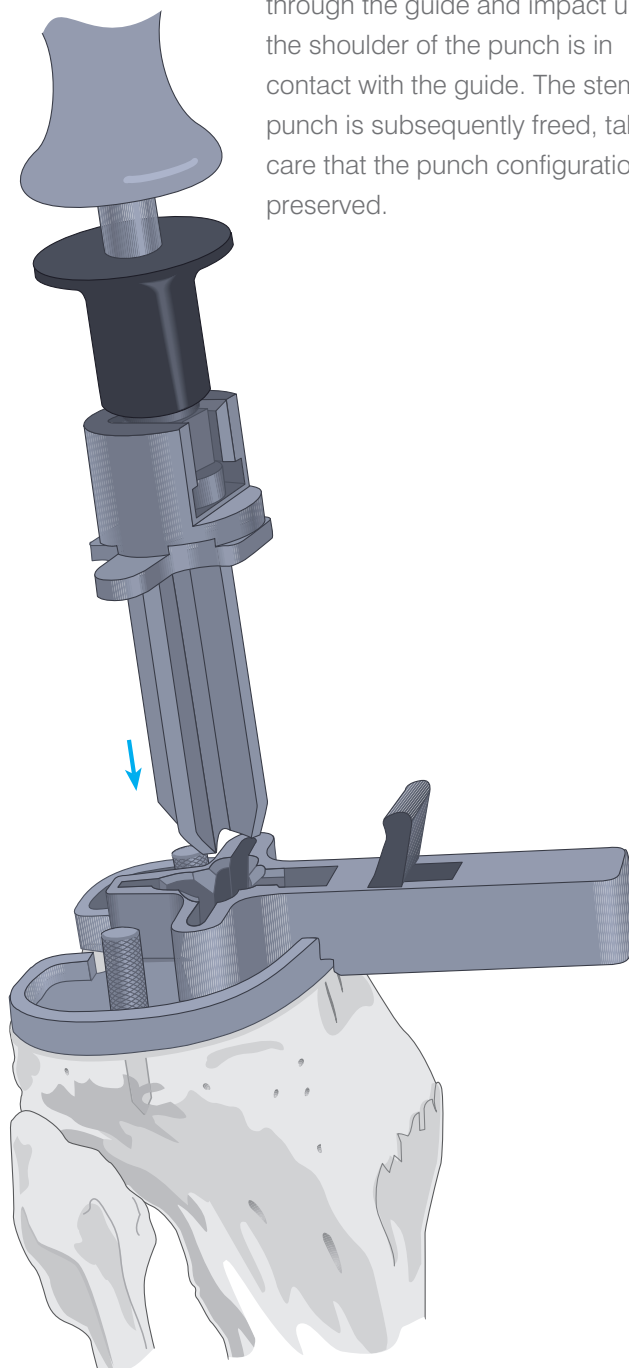


Where the cemented tray is to be implanted, assemble an appropriately sized cemented keel stem punch onto the slap-hammer and insert the punch through the guide and impact until the shoulder of the punch is in contact with the guide. The cemented stem punch is subsequently freed, taking care that the punch configuration is preserved.

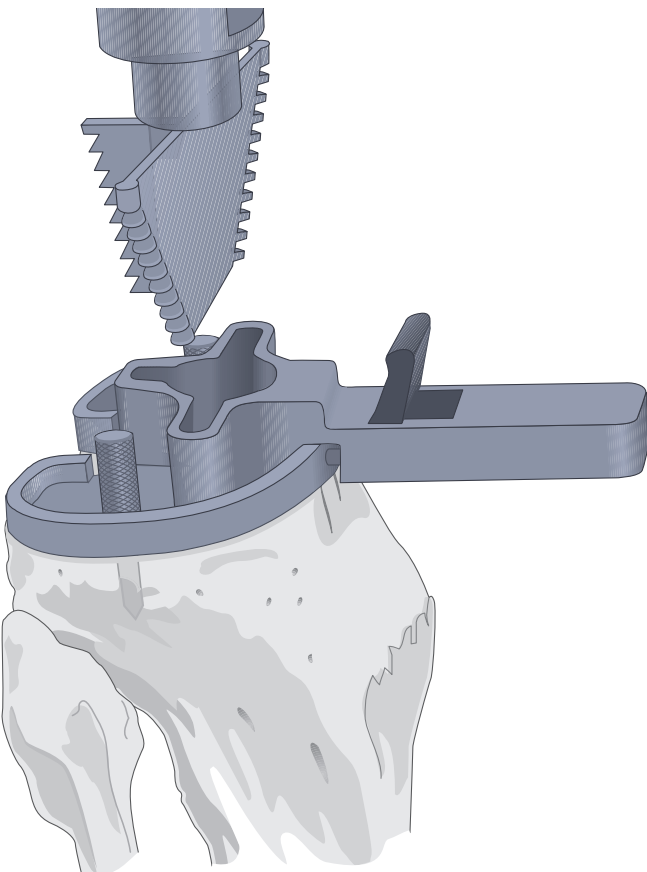
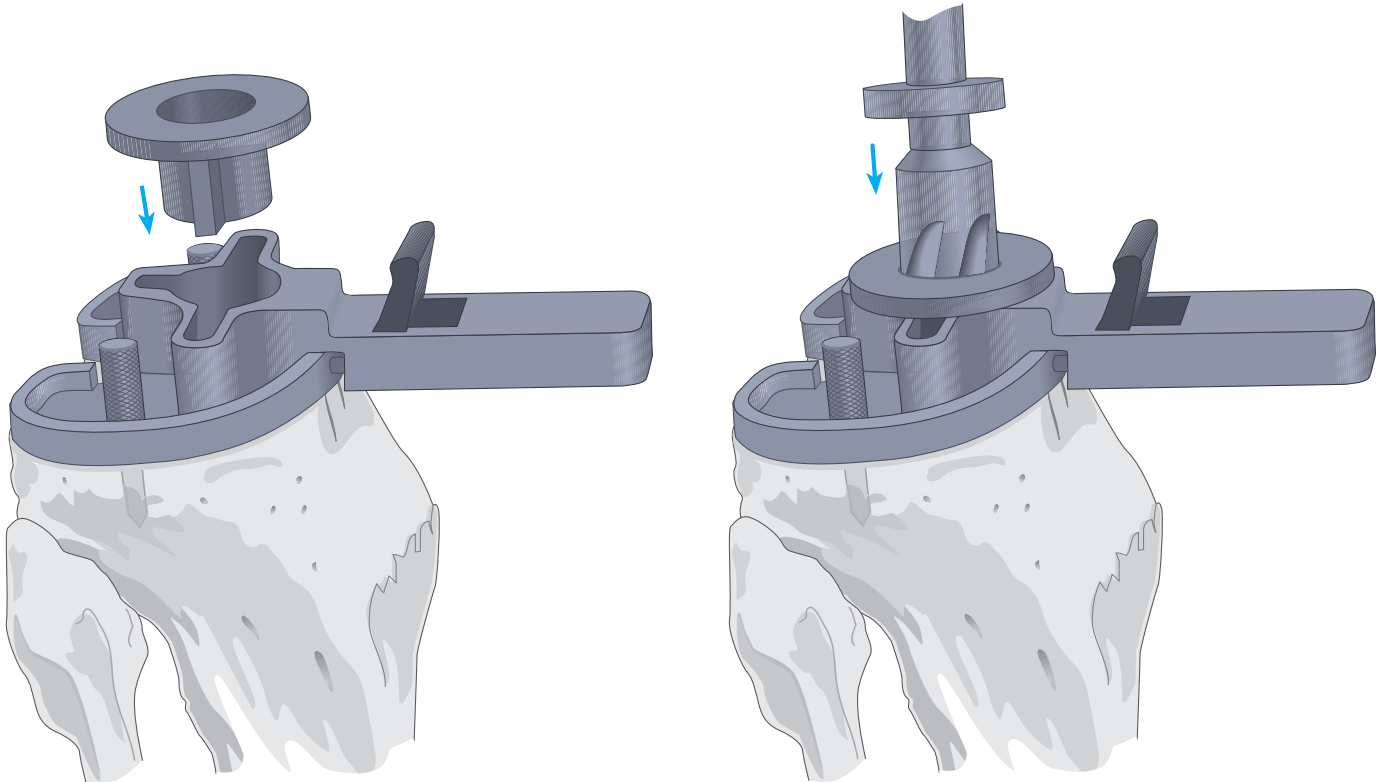
Remove the alignment handle from the tray trial and assemble the appropriately sized cruciform keel punch guide to the tray trial.

Where the non-cemented tray is to be implanted, assemble an appropriately sized non-cemented keel punch onto the slap-hammer and insert the punch

through the guide and impact until the shoulder of the punch is in contact with the guide. The stem punch is subsequently freed, taking care that the punch configuration is preserved.



# P.F.C.® Modular Tray & UHMWPE\* Tibia Preparation



Select the appropriate punch guide, drill bushing, drill and modular keel punch system. Remove the alignment handle from the tray trial and assemble the appropriately sized modular tray punch guide to the tray trial.

Seat the appropriately sized drill bushing into the modular tray punch guide.

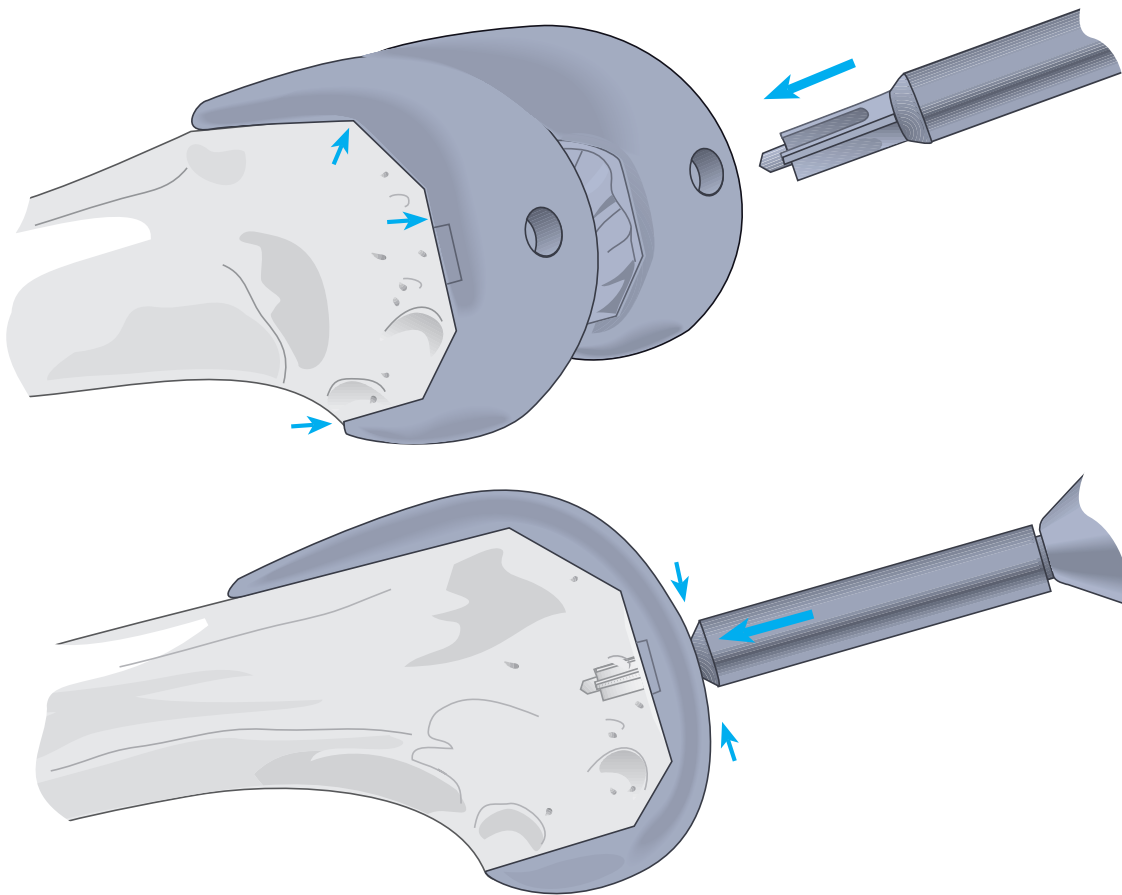
The matching drill is fully advanced through the drill bushing into the cancellous bone.

The appropriately sized modular tray keel punch is subsequently positioned through the guide and impacted until the shoulder of the punch is in contact with the guide. The modular tray keel punch is subsequently freed, taking care that the punch configuration is preserved.

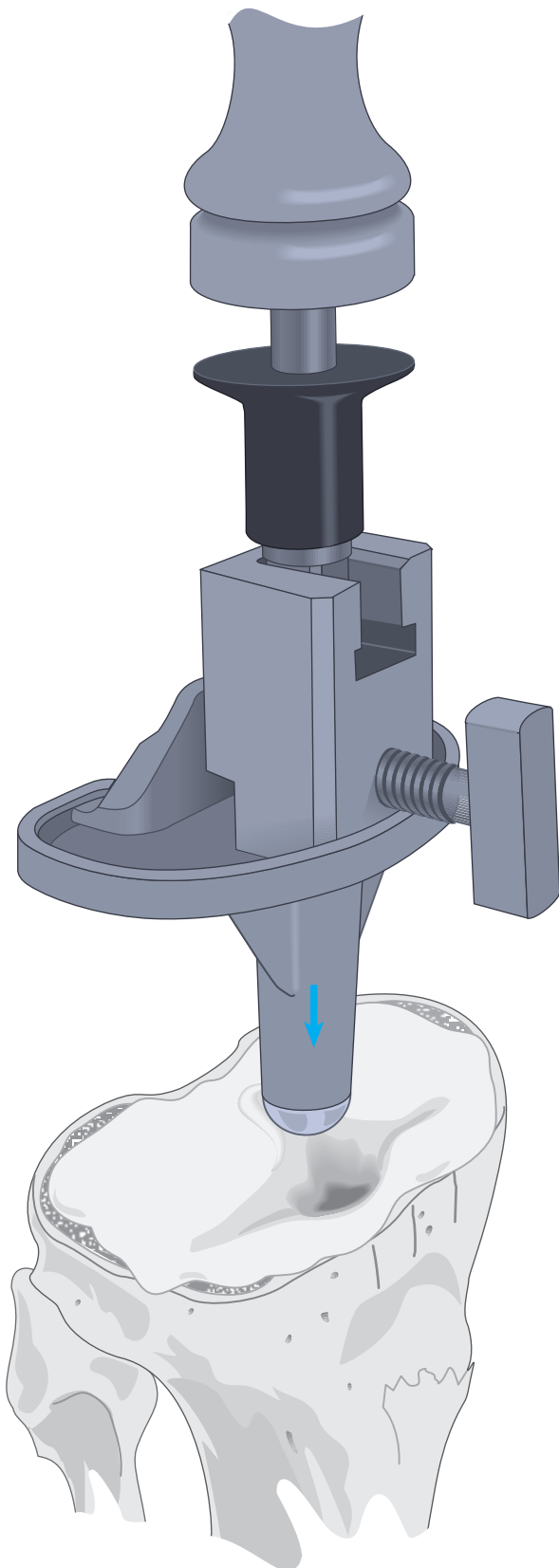
**\*UHMWPE (All-Poly)**

# The Femoral Lug Drill

Mediolateral positioning of the femoral trial component is confirmed and receptacles prepared for the implant lugs by advancing the femoral drill through the appropriate holes.



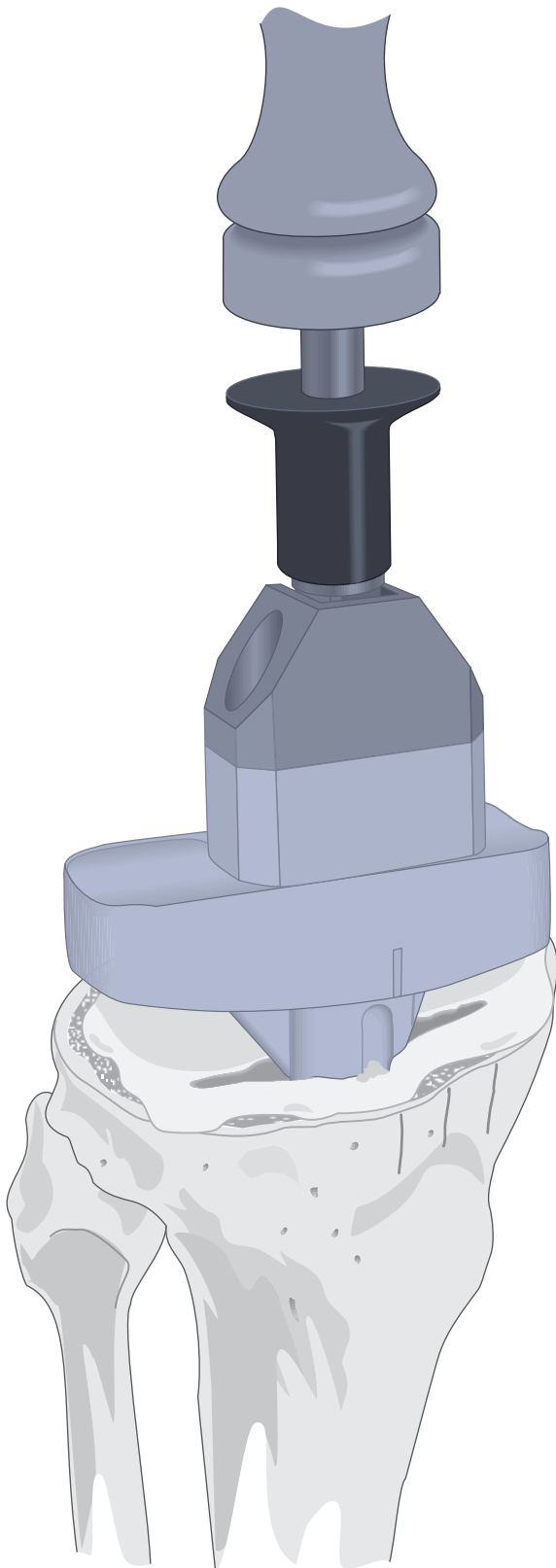
# Implanting the Components



## The Tibial Component

The entire site is thoroughly cleansed with pulsatile lavage. Methyl methacrylate cement is prepared and applied by syringe or digital pressure in its low viscous state to assure maximal penetration into the trabecular bone.

The universal handle is assembled onto the universal tibial tray inserter and assembled onto the tibial tray. The tray is carefully inserted, **avoiding malrotation**. When it is fully seated, several mallet blows are delivered to the top of the universal handle. The nylon tibial tray impactor may be used to further impact the tibial tray.



### **UHMWPE Tibial Component**

Alternatively, when implanting an all-UHMWPE tibial component, place the component in appropriate orientation and impact the flat central proximal portion of the component with the nylon tibial tray impactor. Excess cement is removed from the periphery of the tibial plateau, and a final impaction is performed to ensure complete seating of the component.

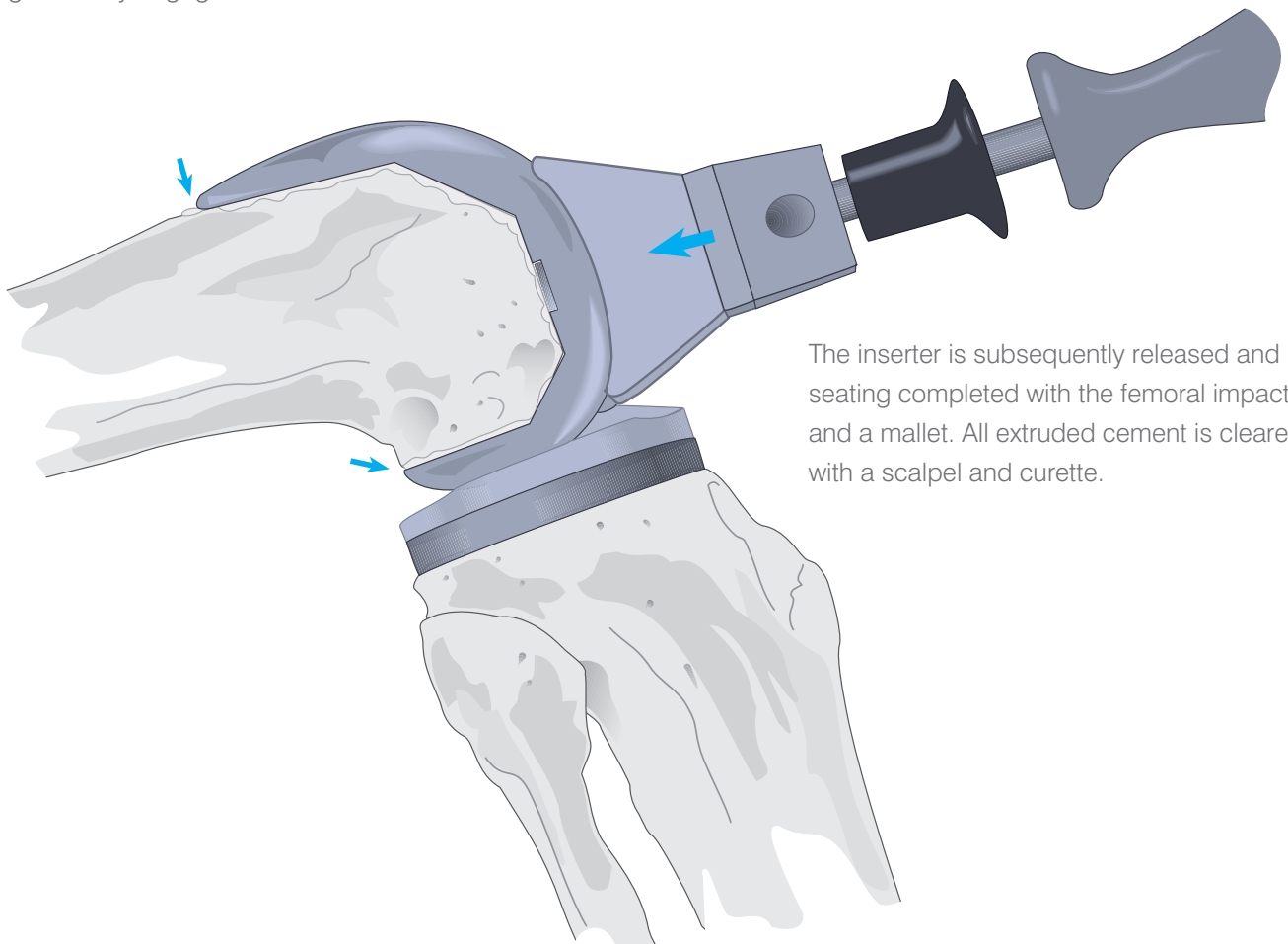
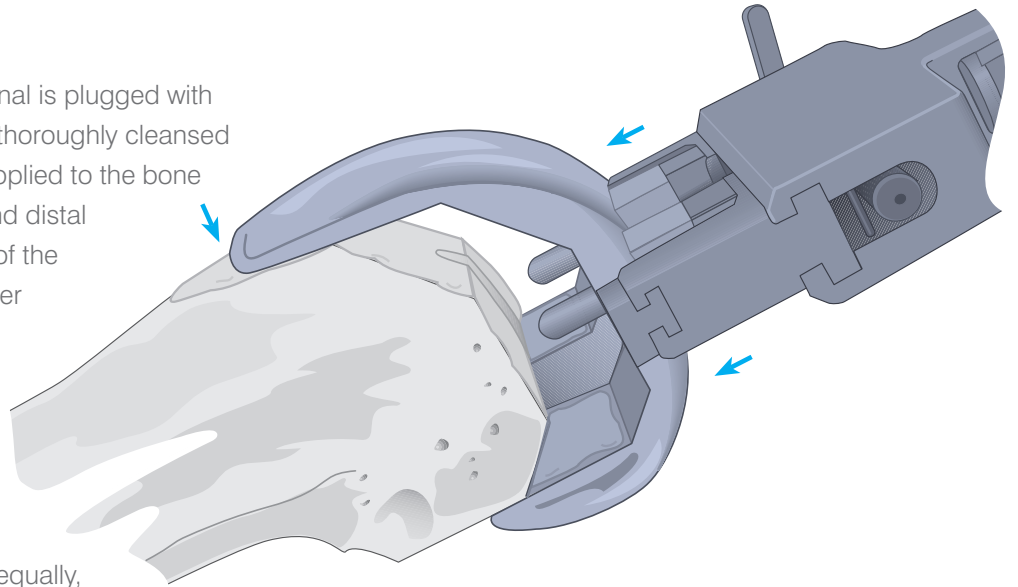
### **Cement Pressurisation**

As the cement polymerises, a trial component is positioned on the prepared femur. The knee is placed in full extension to maintain pressure at the bone/tibial implant interface. Slight valgus stress is maintained to ensure that the tibial implant does not tilt into varus. When the cement has set, the knee is placed in flexion and the trial femoral component removed. All extruded cement is carefully removed with special attention to the posterior compartment.



## The Femoral Component

The entry hole at the medullary canal is plugged with cancellous bone. All surfaces are thoroughly cleansed with pulsatile lavage. Cement is applied to the bone at the anterior, anterior chamfer and distal surfaces and to the inner surface of the component at the posterior chamfer and posterior condylar recesses. Care is taken to avoid the articular surface of the implant. The implant is assembled onto the femoral inserter. Care is taken that it is correctly oriented. The leading edges are advanced equally, parallel to the distal surface and protecting the carefully configured surfaces, until the lugs are fully engaged.

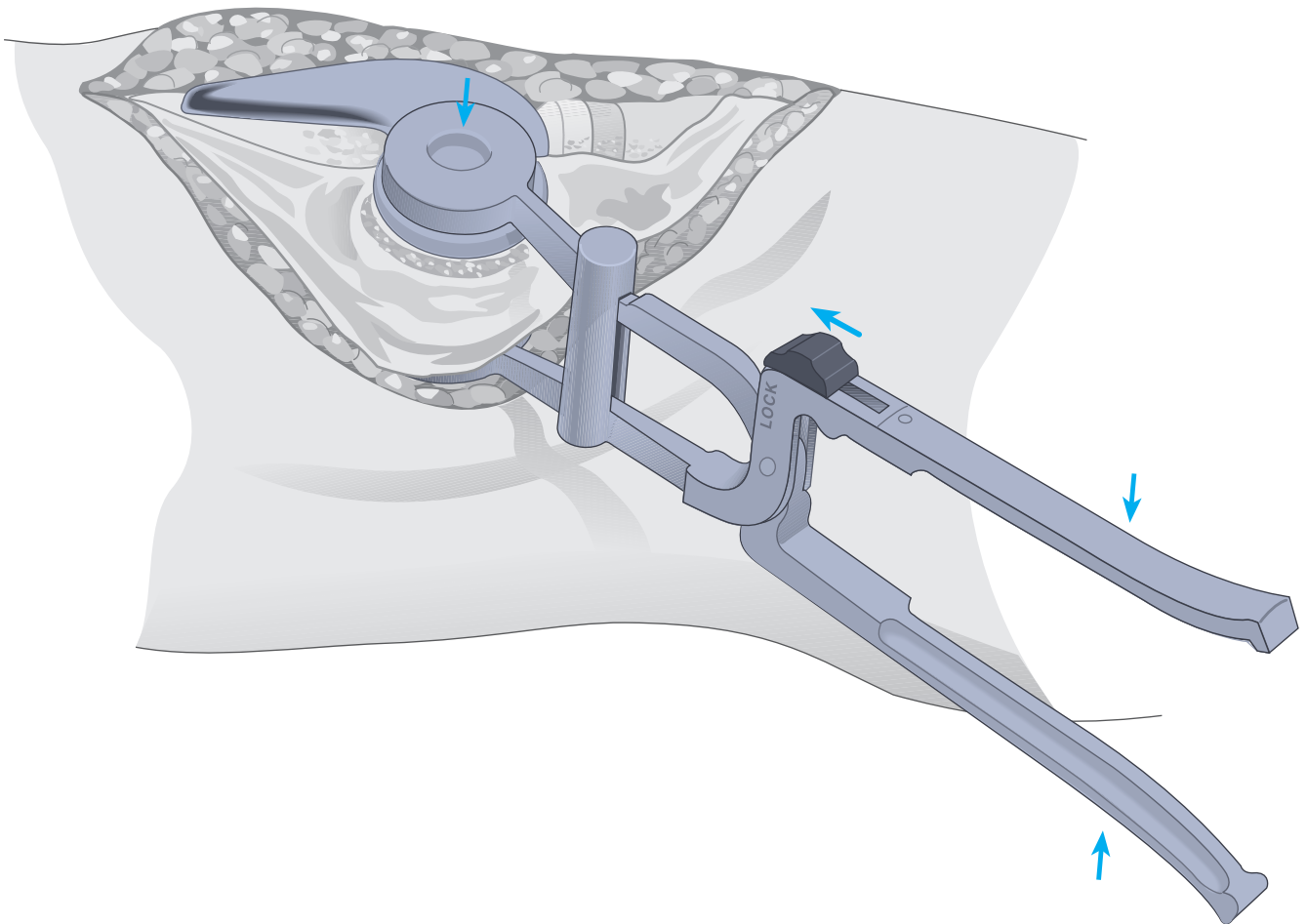


The inserter is subsequently released and seating completed with the femoral impactor and a mallet. All extruded cement is cleared with a scalpel and curette.

## The Patellar Component

The patellar implant may be cemented at the surgeon's convenience with either of the other components. The cut surface is thoroughly cleansed with pulsatile lavage. Cement is applied to the surface and the component inserted.

The patellar clamp is designed to fully seat and stabilise the implant as the cement polymerises. It is positioned with the silicon O-ring centred over the articular surface of the implant and the metal backing plate against the anterior cortex, avoiding skin entrapment. When snug, the handles are closed and held by the ratchet until polymerisation is complete. Excessive compression is avoided as it can fracture osteopenic bone. All extruded cement is removed with a curette. To release the clamp, place the locking knob in the unlocked position and squeeze the handles together to release the pawl.



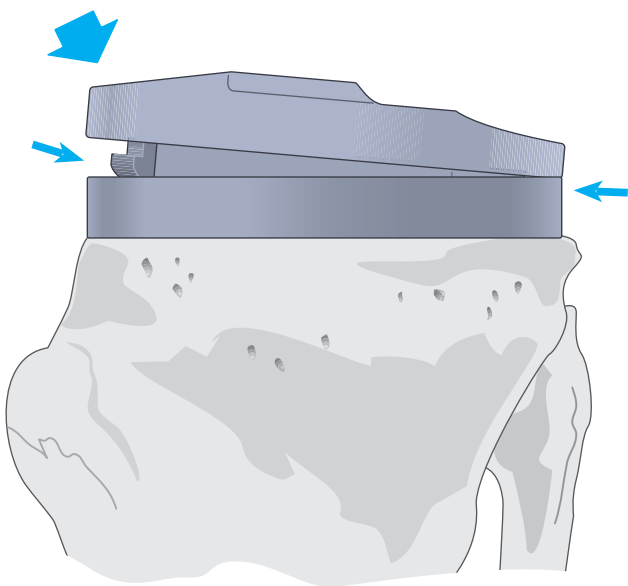
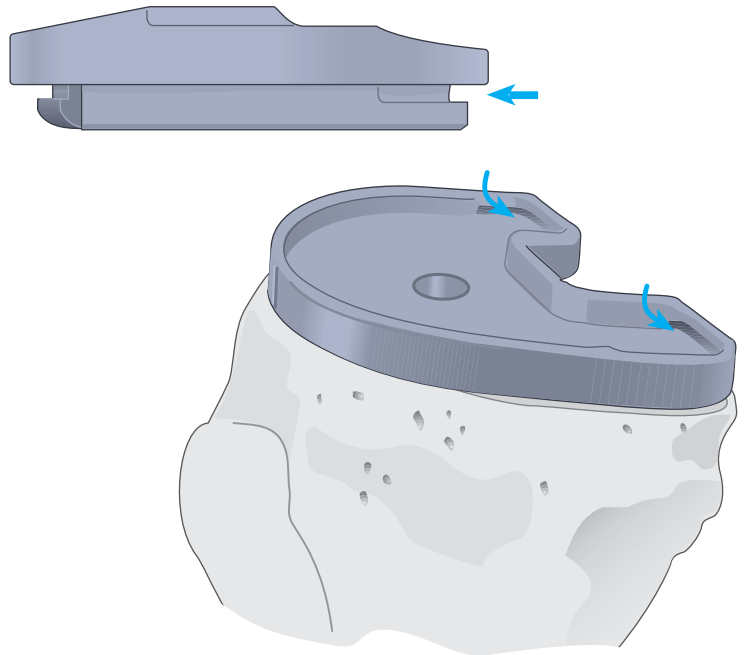
## The Tibial Insert

The trial insert is removed and the permanent insert introduced into the implanted tibial tray and seated posteriorly, its anterior margin resting on the lip.

The anterior margin is tapped with a nylon mallet, deflecting it past the lip of the tray into position. Seating is confirmed by circumferential inspection.

Alternatively, the permanent insert may be inserted at any convenient time during the cementing procedure.

When a curved insert topography is utilised and the flexion gap is snug, it may be difficult to extract a trial insert and introduce the permanent one. In such a case, the permanent insert should be implanted prior to cementing the femoral component.



## Closure

The tourniquet is released and bleeding controlled by electrocautery. A closed-wound suction drain is placed in the suprapatellar pouch and brought out through the lateral retinaculum. The fat pad, quadriceps mechanism, patella tendon, and medial retinaculum are reapproximated with interrupted sutures.

The knee is put through a range of motion from full extension to full flexion to confirm patellar tracking and the integrity of the capsular closing. The final flexion against gravity is noted for postoperative rehabilitation.

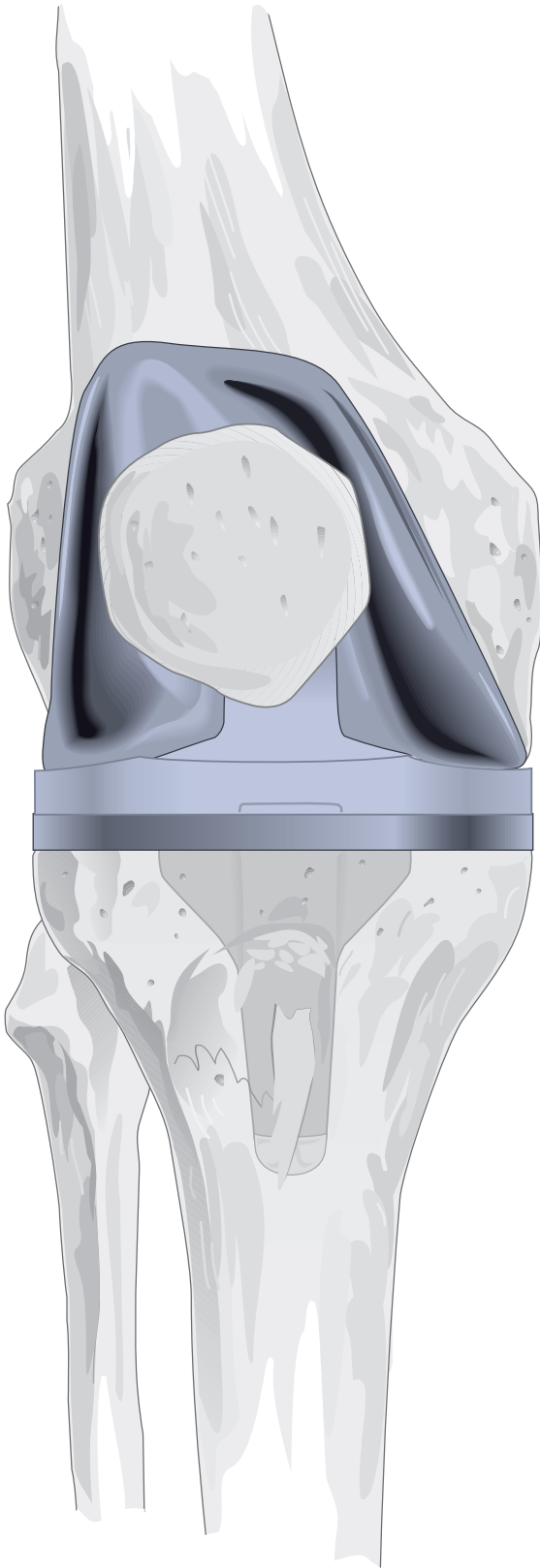
Subcutaneous tissue is reapproximated and the skin closed with sutures or staples.

# Primary Cruciate-Substituting Procedure

**Chitranjan S. Ranawat, M.D.**

Clinical Professor of Orthopaedic Surgery  
Cornell University Medical College

Director, Orthopaedic Surgery  
Centre for Total Joint Replacement  
Lenox Hill Hospital  
New York, New York

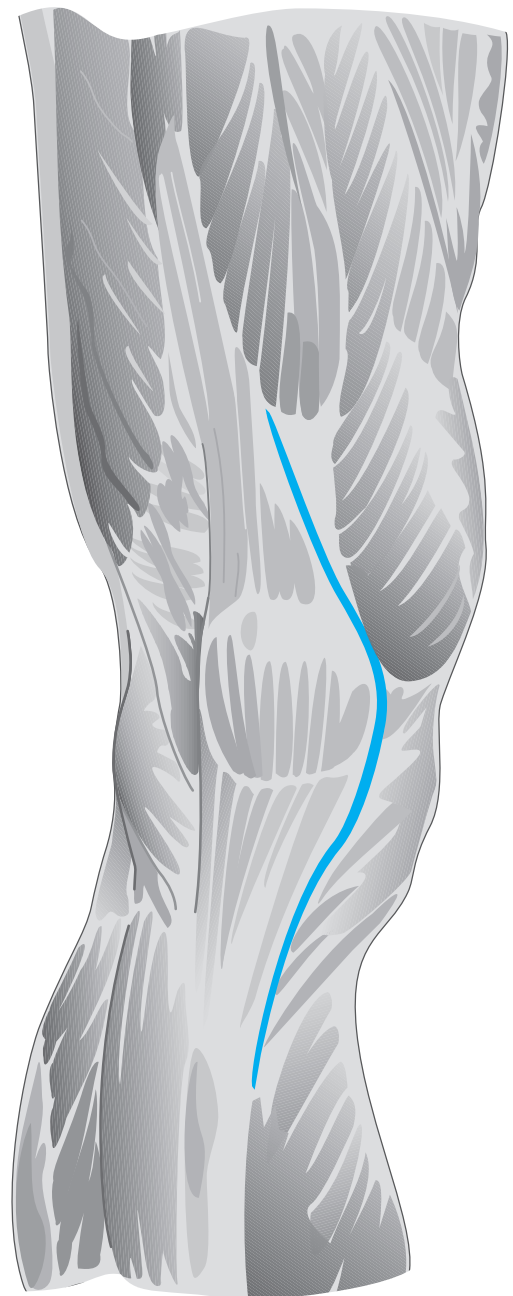
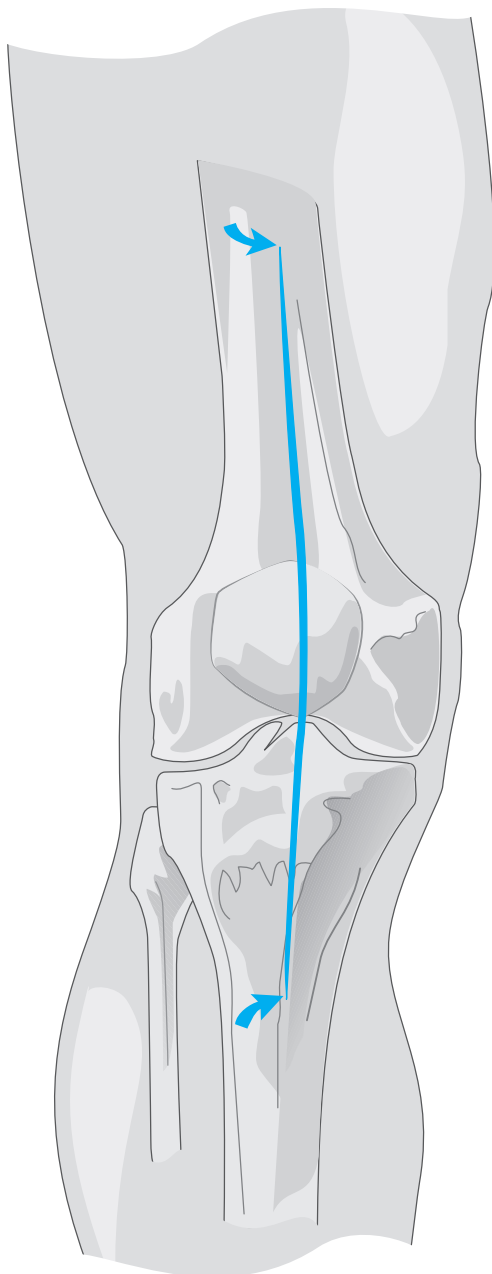


# The Surgical Approach

The extremity is appropriately prepared and draped. A tourniquet is applied and, following application of an Esmarch bandage, inflated.

A long straight incision is initiated 12 cm proximal to the superior margin of the patella and an equivalent distance distal to its inferior margin. Reducing, thereby, the degree of skin retraction and lowering the risk of subsequent adipose tissue necrosis.

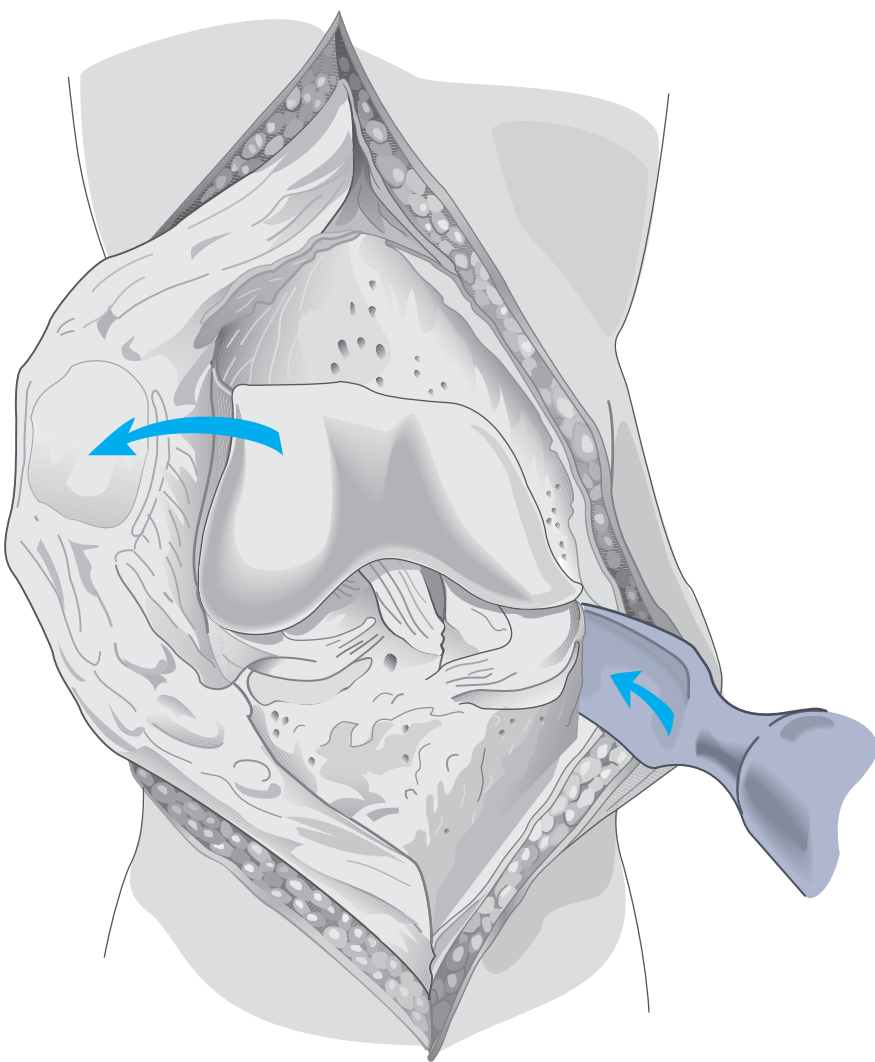
The incision is developed at the deep fascial level to the tendon of the rectus femoris and the patellar tendon. Undermining of the bilateral skin flaps is avoided. The tendon of the rectus femoris is incised and the incision carried 2-3 mm medial to the medial margin of the patella, the patellar tendon and, subperiosteally, 5 cm distal to the superior margin of the tibial tubercle.



# Exposure

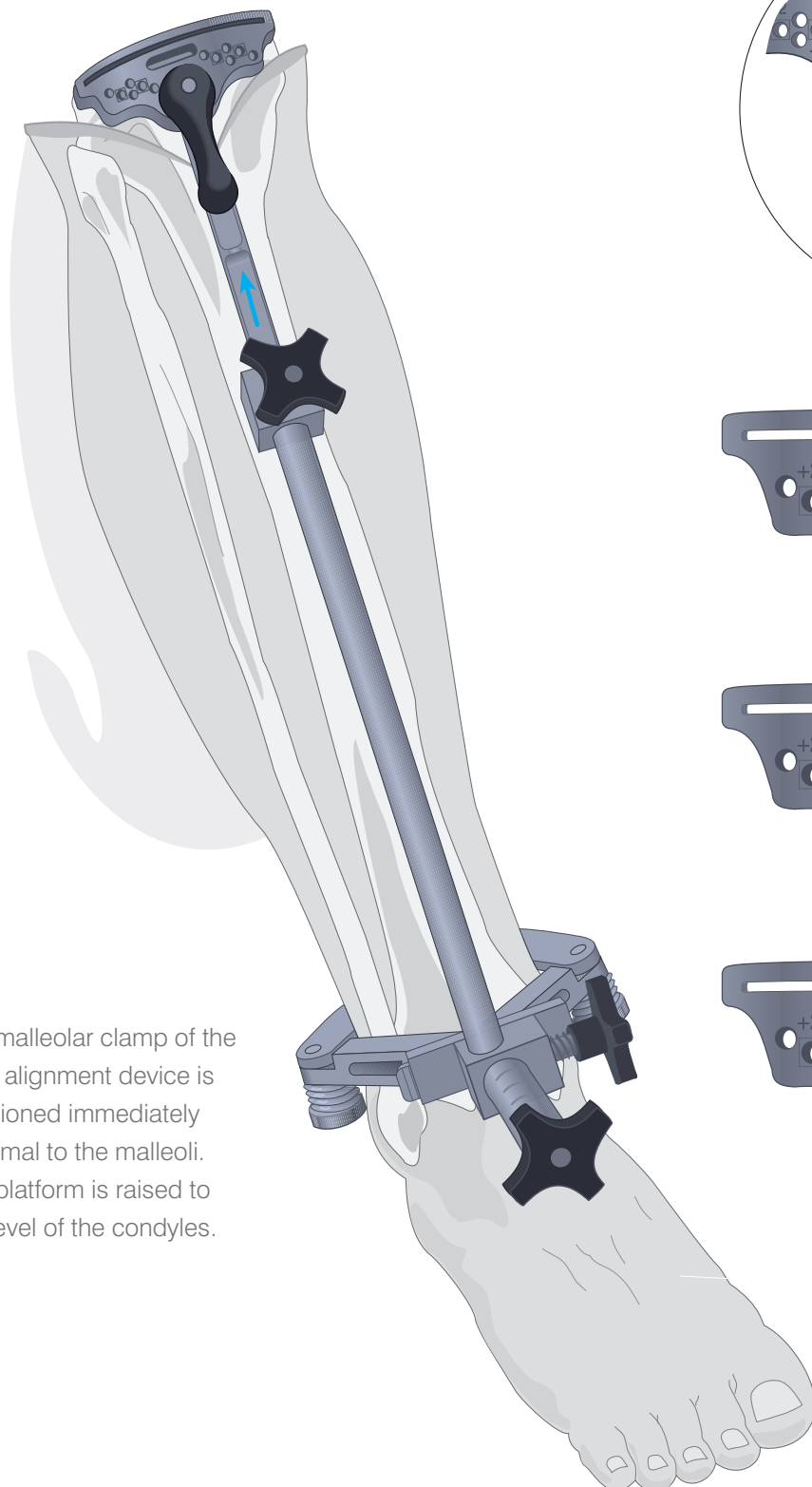
The patella is everted laterally and the knee placed in full flexion. The cruciate ligaments and the menisci are excised (see appendix I, **pages 85 and 89**). Where indicated, preliminary soft-tissue release is performed. Where the knee is tight and in varus, a curved osteotome is passed along the medial tibial border posterior to the midcoronal plane to release the meniscotibial ligament and promote anterior subluxation of the tibia.

**Note: For discussion of soft-tissue balancing, see Appendix I**

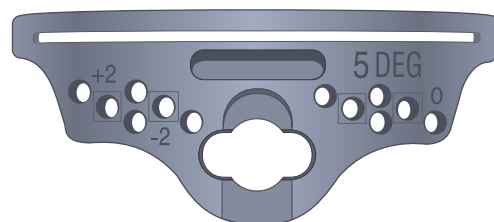
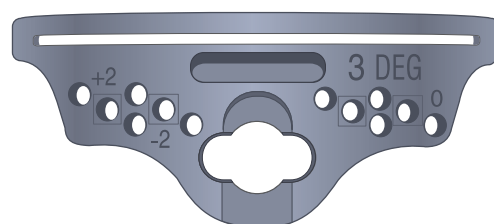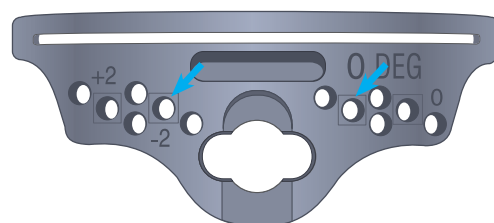

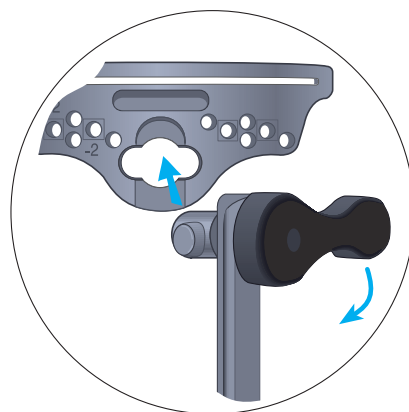
# Tibial Alignment

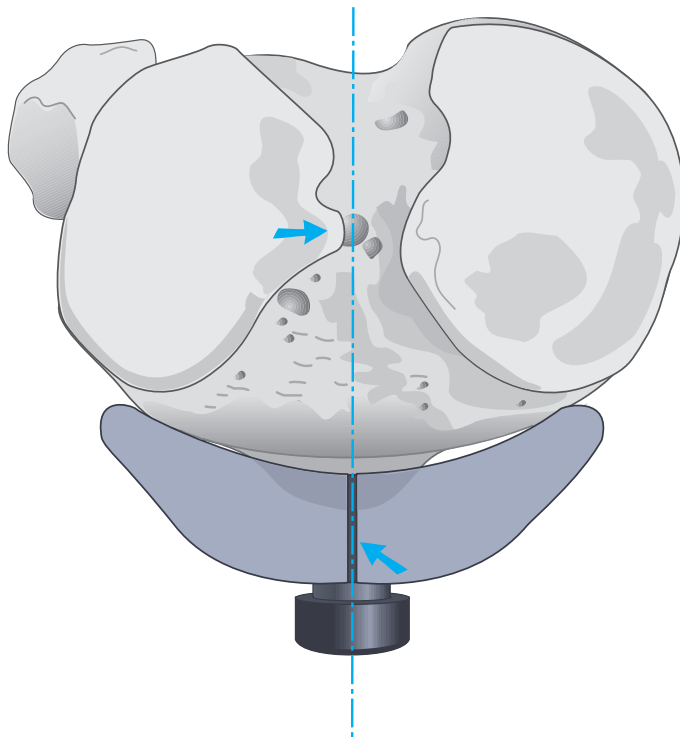
The knee is placed in maximal flexion with the tibia distracted anteriorly and stabilised.



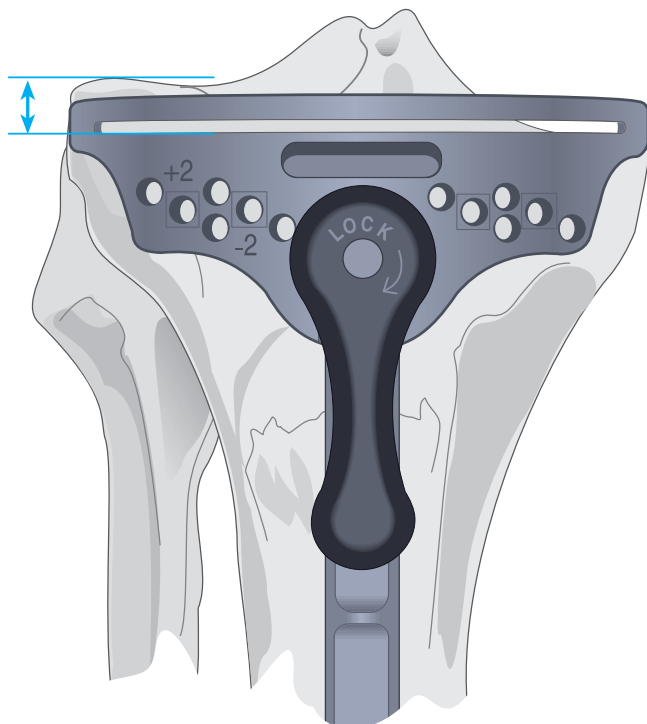
The malleolar clamp of the tibial alignment device is positioned immediately proximal to the malleoli. The platform is raised to the level of the condyles.



# The Upper Platform



The upper platform is aligned with the medial third of the tibial tubercle and the medial margin of the lateral intercondylar eminence with the extremities of the cutting surface against the anterior cortex.

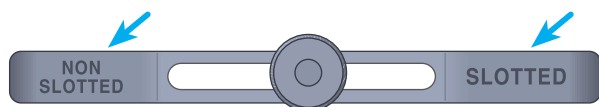


The exact level of resection will vary according to patient anatomy. As the mediolateral transverse plane of the tibial plateau is usually  $3^\circ$  from the perpendicular and the projected cut is perpendicular to the anatomic axis, more bone is typically removed from the lateral condyle.



# The Tibial Stylus

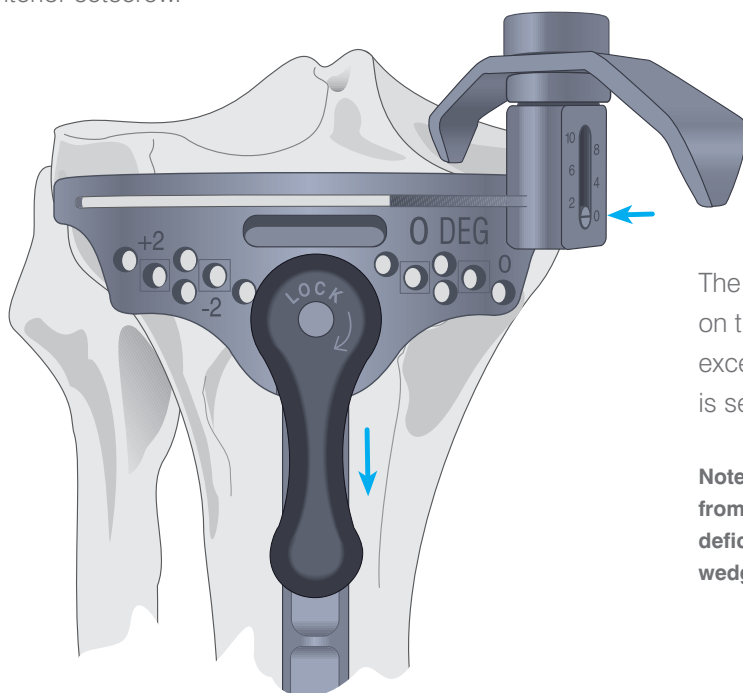
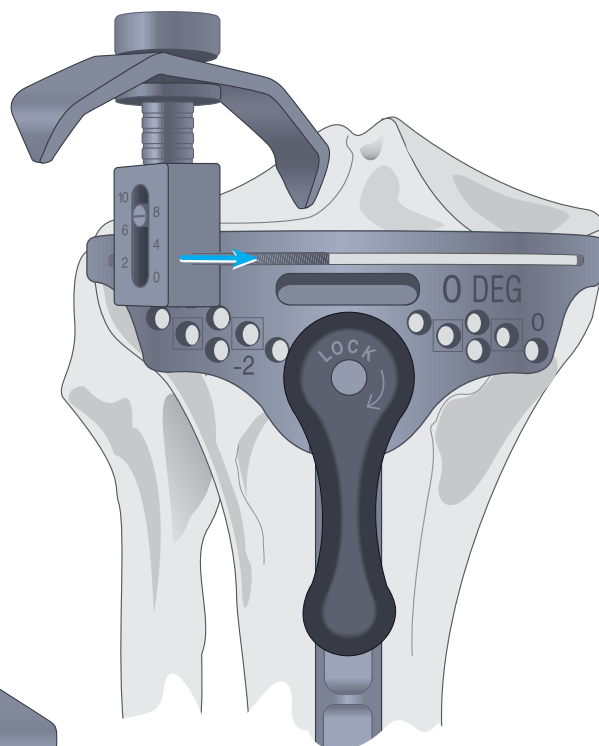
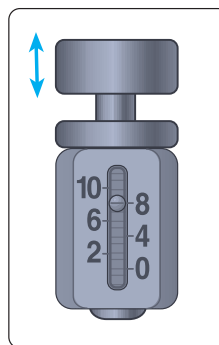
The stylus determines the exact level of resection.



The outrigger of the stylus is marked non-slotted and slotted at either end. When the tibial resection is performed from the surface of the block, choose the non-slotted end of the outrigger, conversely, when the resection is performed through the slots, choose the slotted end of the outrigger. There is a 4 mm difference between the top surface and the slot.

The cylinder foot is inserted into the slot of the cutting block and adjusted to the appropriate level. It is calibrated in 2 mm increments, indicating the amount of bone and residual cartilage to be resected.

A level of 8 mm or 10 mm is suggested where resection is based on the less involved condyle. The block is adjusted such that the stylus rests on the centre of the condyle and the cutting block is secured by the large anterior setscrew.

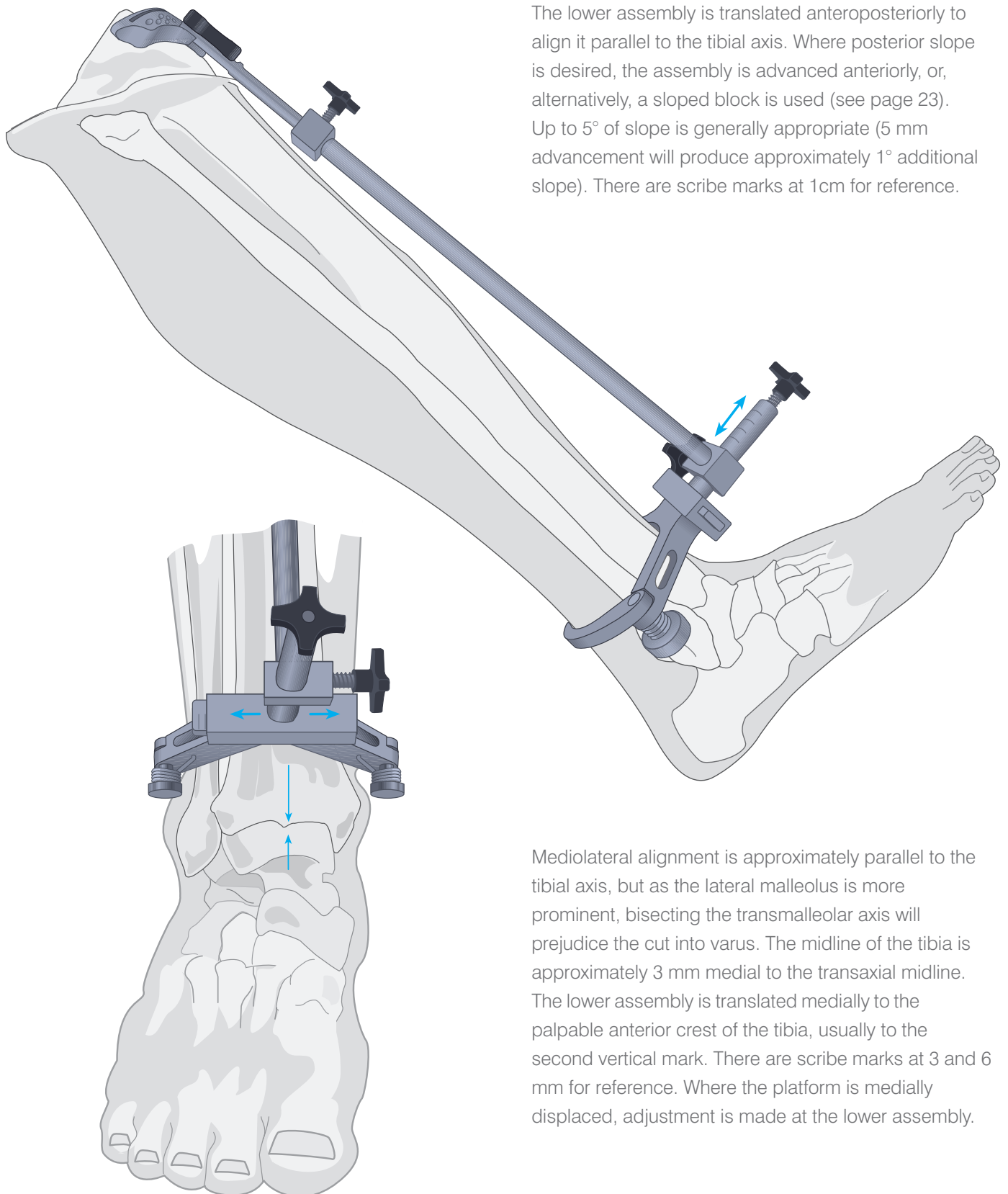


The level of 0 is selected where resection is based on the more involved condyle and does not result in excessive contralateral resection. The cutting block is secured by the large anterior setscrew.

**Note:** Where this indicates greater than 10 mm of resection from the contralateral condyle, a higher level is indicated. The deficiency is augmented with cement, bone graft or a modular wedge, as the situation dictates.

# Lower Alignment

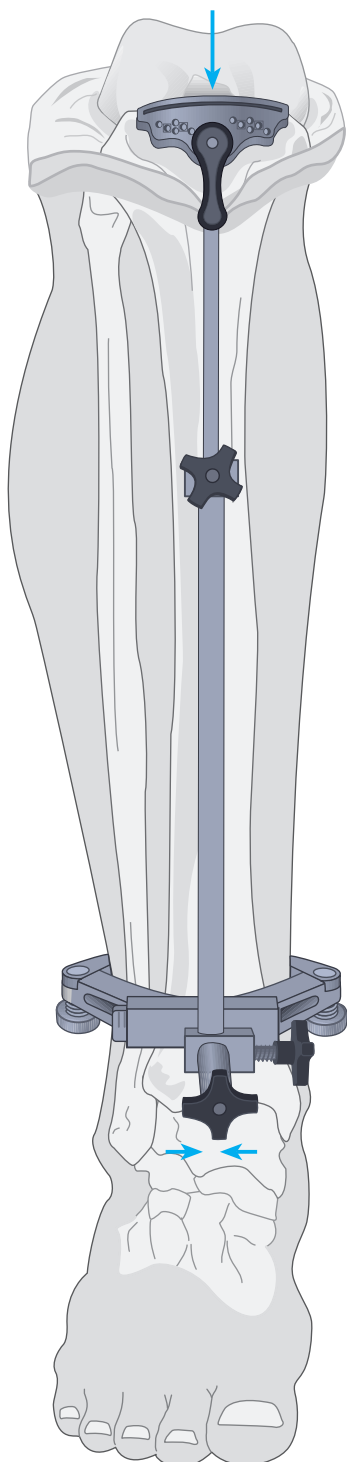
The lower assembly is translated anteroposteriorly to align it parallel to the tibial axis. Where posterior slope is desired, the assembly is advanced anteriorly, or, alternatively, a sloped block is used (see page 23). Up to 5° of slope is generally appropriate (5 mm advancement will produce approximately 1° additional slope). There are scribe marks at 1cm for reference.



Mediolateral alignment is approximately parallel to the tibial axis, but as the lateral malleolus is more prominent, bisecting the transmalleolar axis will prejudice the cut into varus. The midline of the tibia is approximately 3 mm medial to the transaxial midline. The lower assembly is translated medially to the palpable anterior crest of the tibia, usually to the second vertical mark. There are scribe marks at 3 and 6 mm for reference. Where the platform is medially displaced, adjustment is made at the lower assembly.

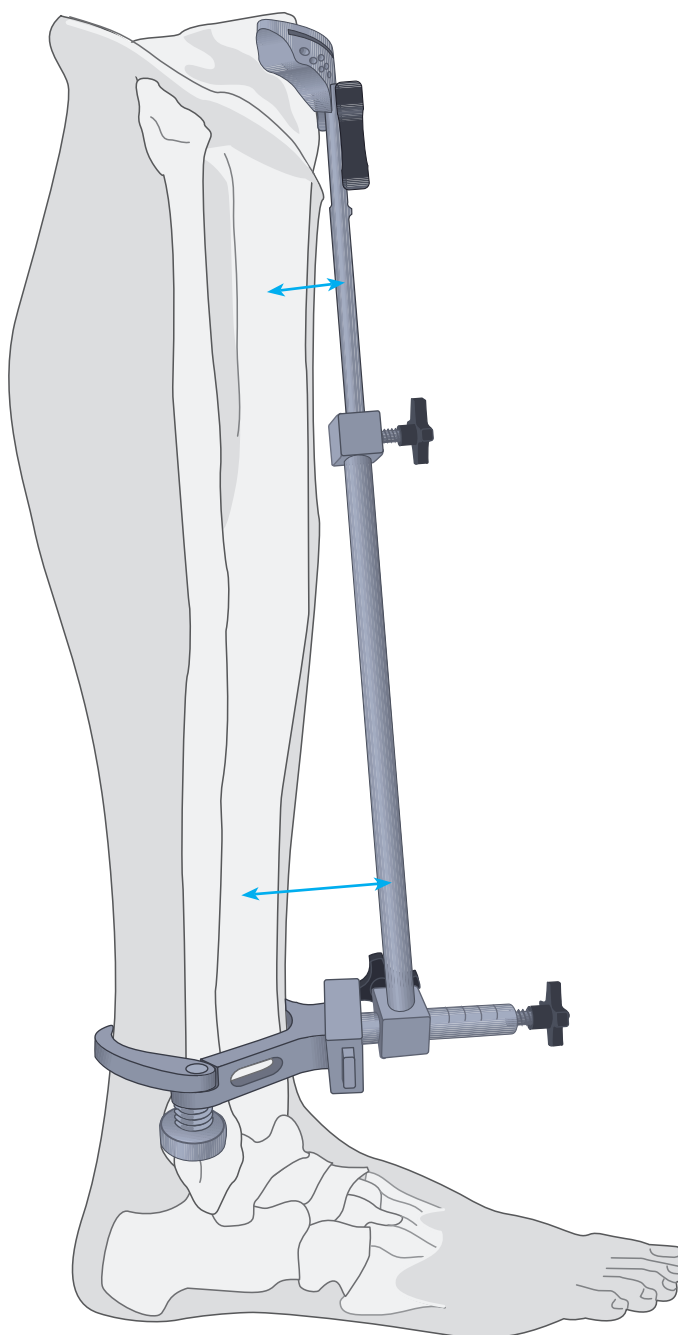
# The Tibial Alignment

The distal portion of the long arm of the tibial alignment device should align with the centre of the talus.




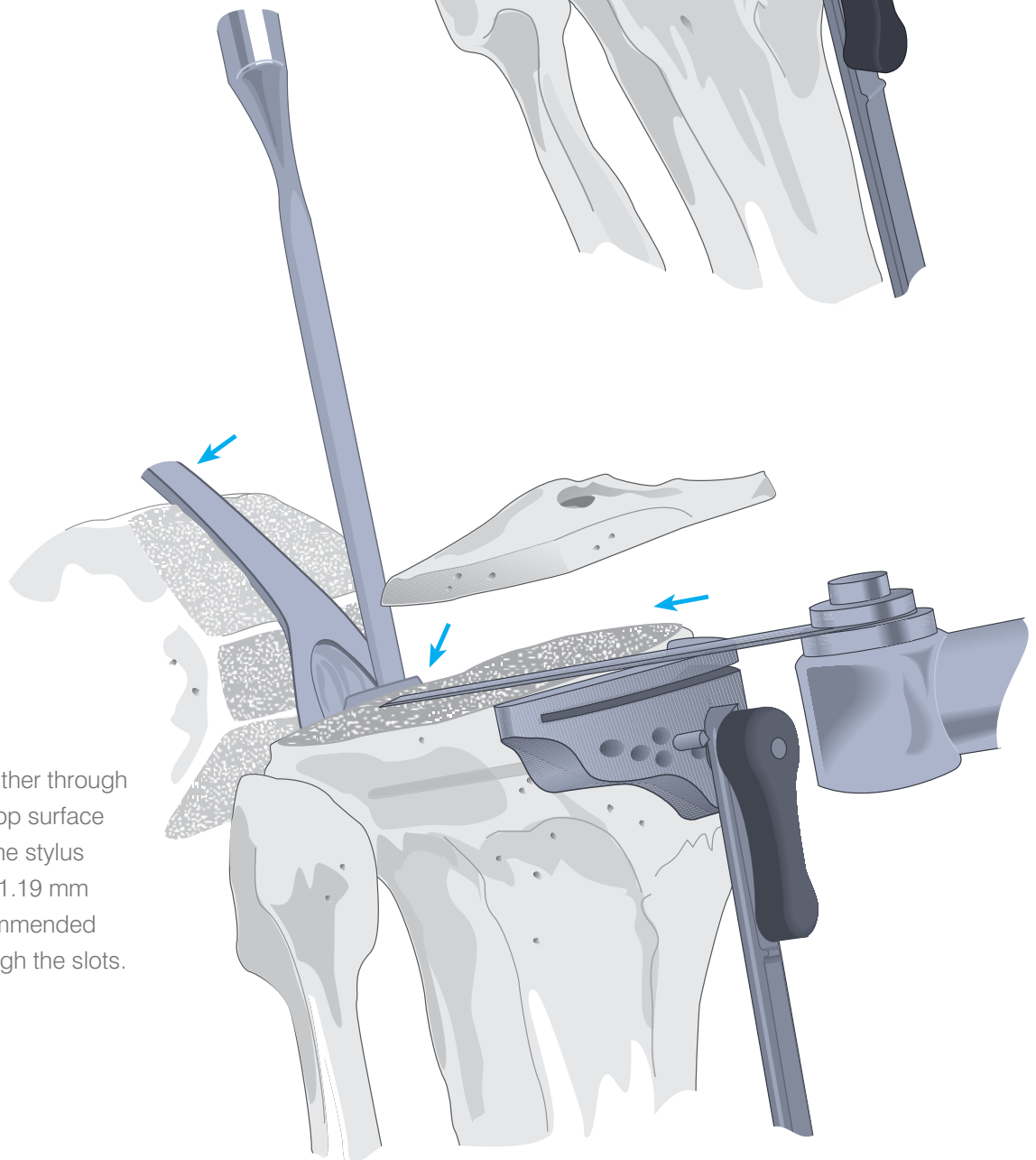
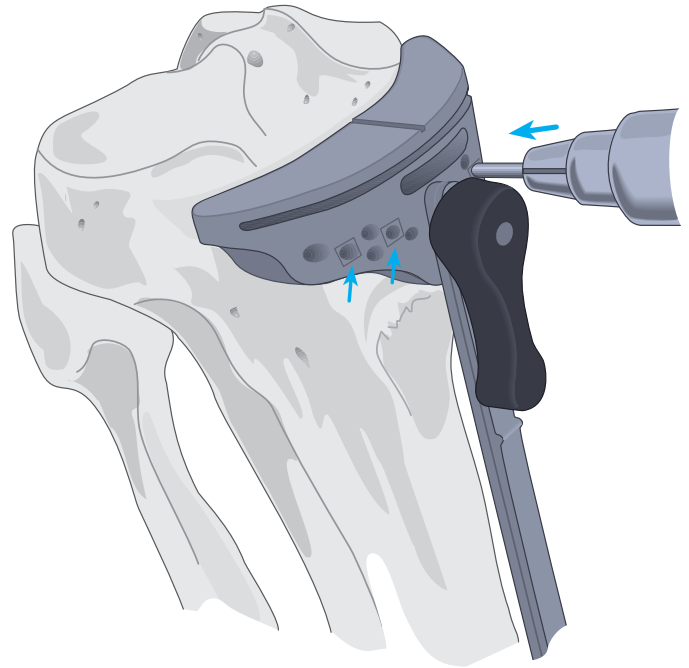
Lateral alignment is similarly confirmed.

**Note:** Where indicated, varus/valgus corrections are made by sliding the distal portion of the tibial alignment to the appropriate location.



# Securing the Platform and Tibial Resection

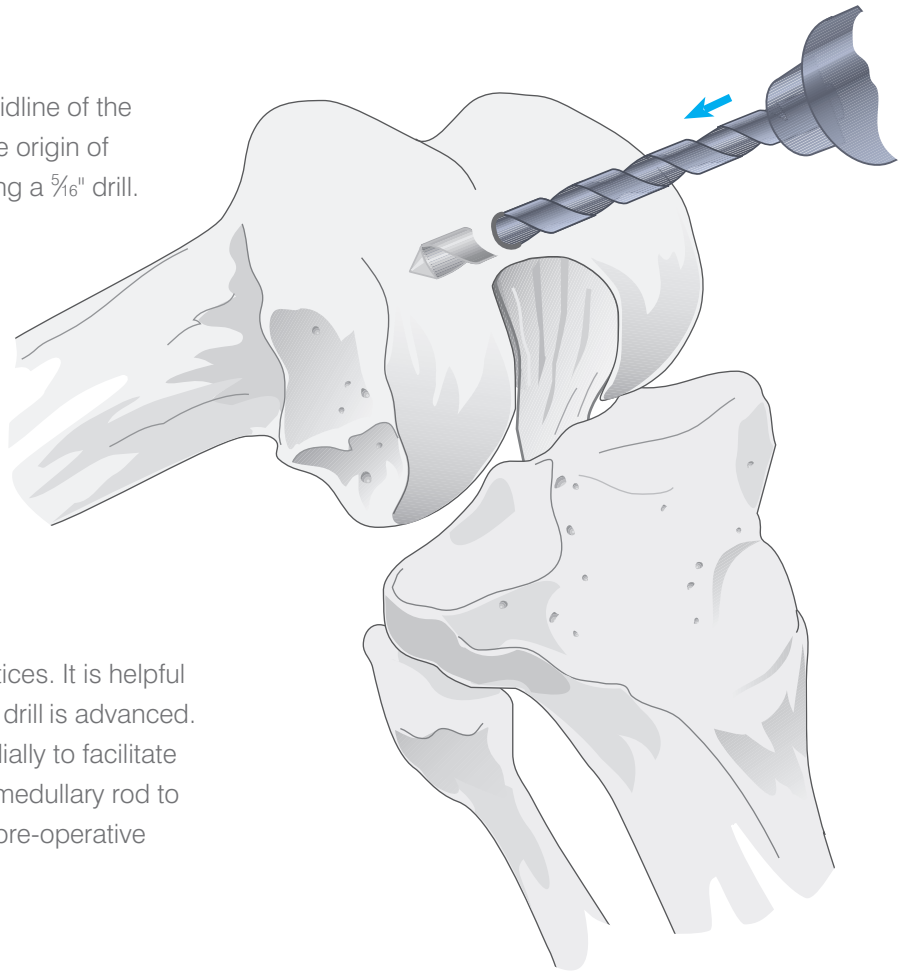
Steinmann pins or  $\frac{1}{8}$ " drill bits are introduced through the central holes marked with a , into the tibia stopping well short of the posterior cortex. The tibial alignment device can either be removed by first unlocking the cutting block, or left in place for additional stability.



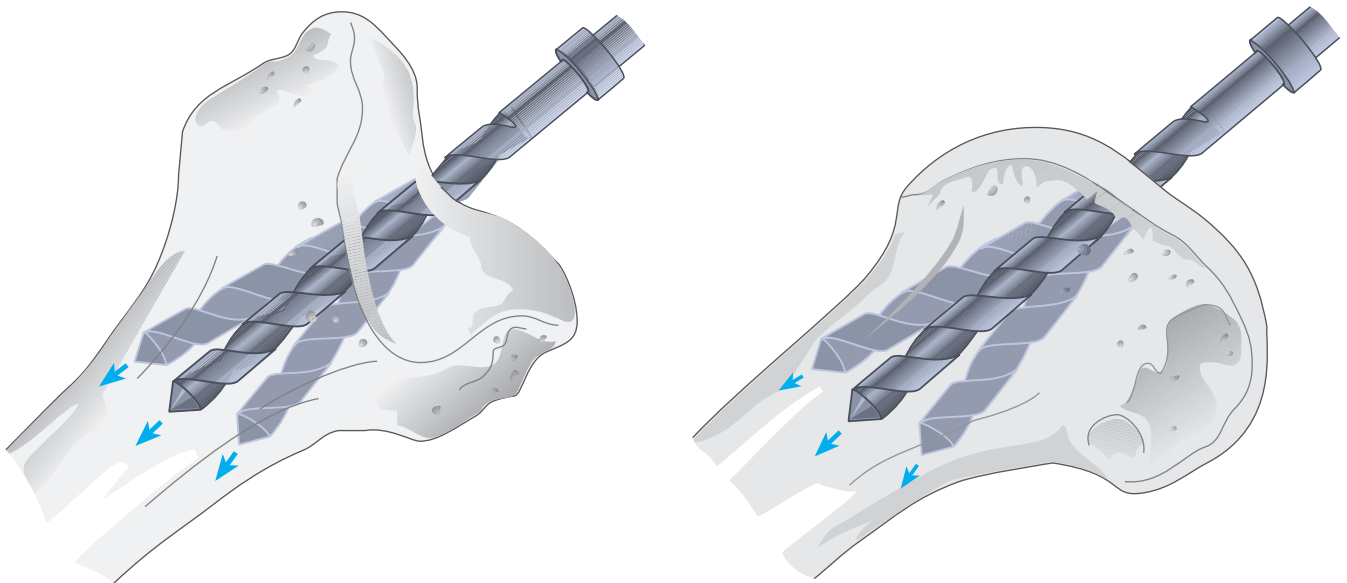
Resection made either through the slot or on the top surface depending upon the stylus reference used. A 1.19 mm saw blade is recommended when cutting through the slots.

# Entering the Medullary Canal

The medullary canal is entered at the midline of the femoral trochlea 7-10 mm anterior to the origin of the PCL to a depth of about 5-7 cm using a  $\frac{5}{16}$ " drill.

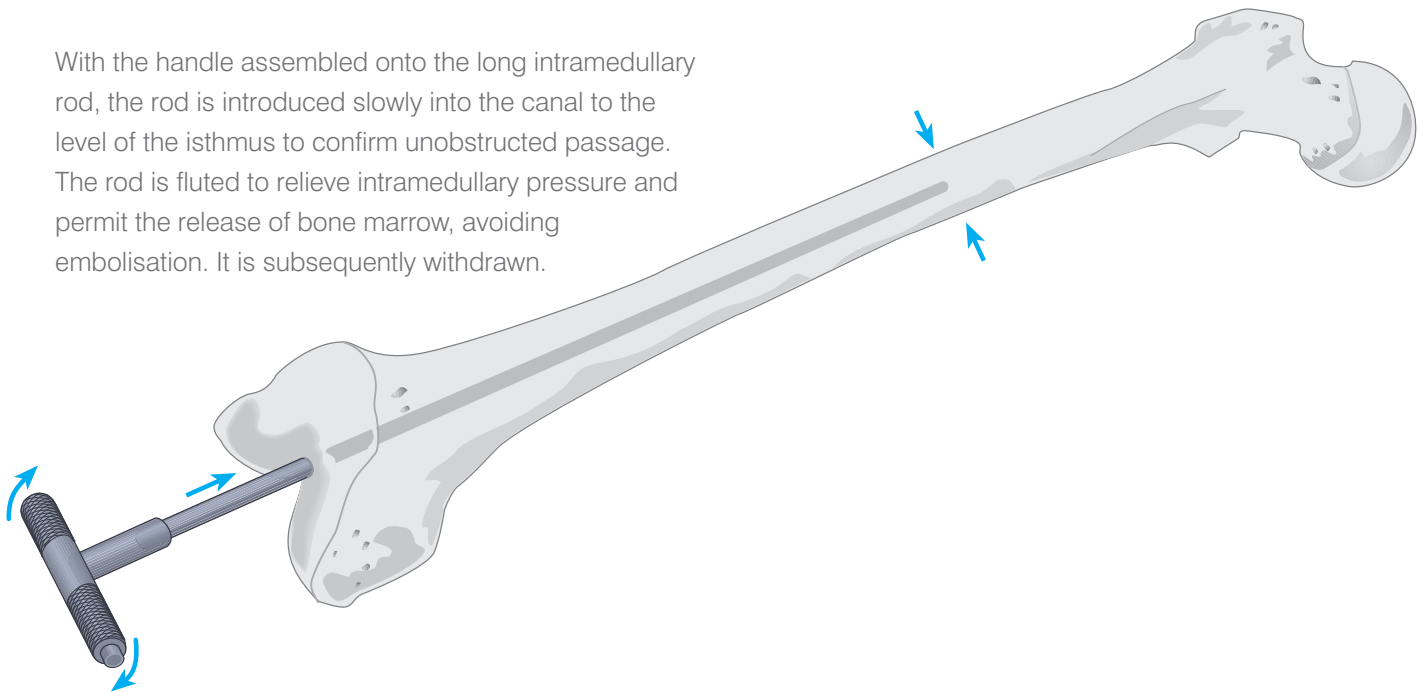


Care is taken that the drill avoid the cortices. It is helpful to palpate the distal femoral shaft as the drill is advanced. The drill hole may be biased anteromedially to facilitate unobstructed passage of the long intramedullary rod to the diaphyseal isthmus, if indicated by pre-operative x-rays.



# The Intramedullary Rod

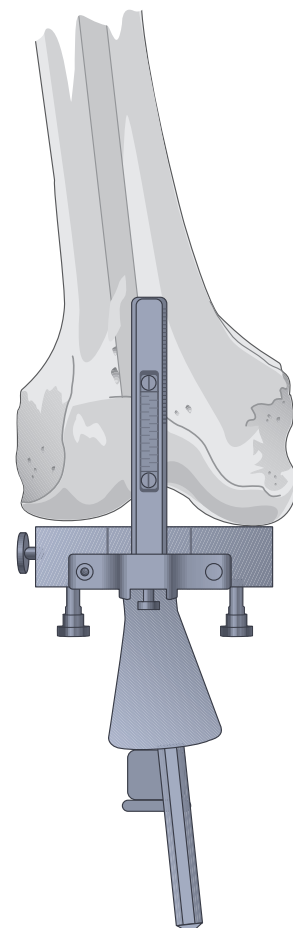
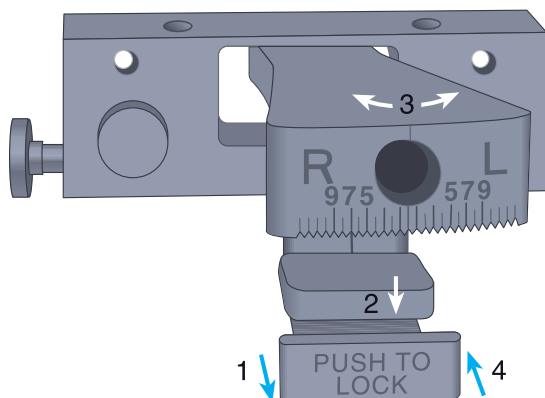
With the handle assembled onto the long intramedullary rod, the rod is introduced slowly into the canal to the level of the isthmus to confirm unobstructed passage. The rod is fluted to relieve intramedullary pressure and permit the release of bone marrow, avoiding embolisation. It is subsequently withdrawn.



# The Femoral Locating Device

The valgus angle with the appropriate Right/Left designation, as indicated on the pre-operative films, is set and locked into place on the front of the locating device. The angle can be set from 0° to 9° in 1° increments.

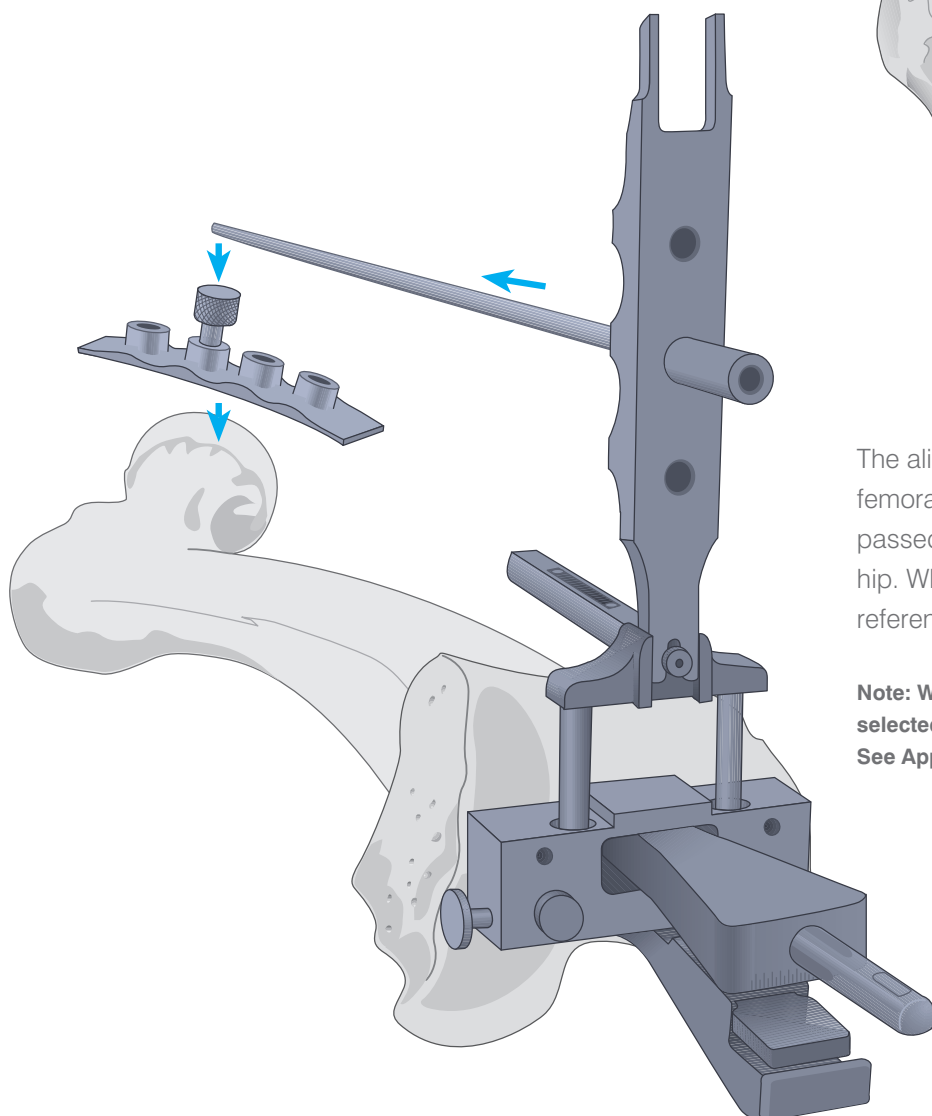
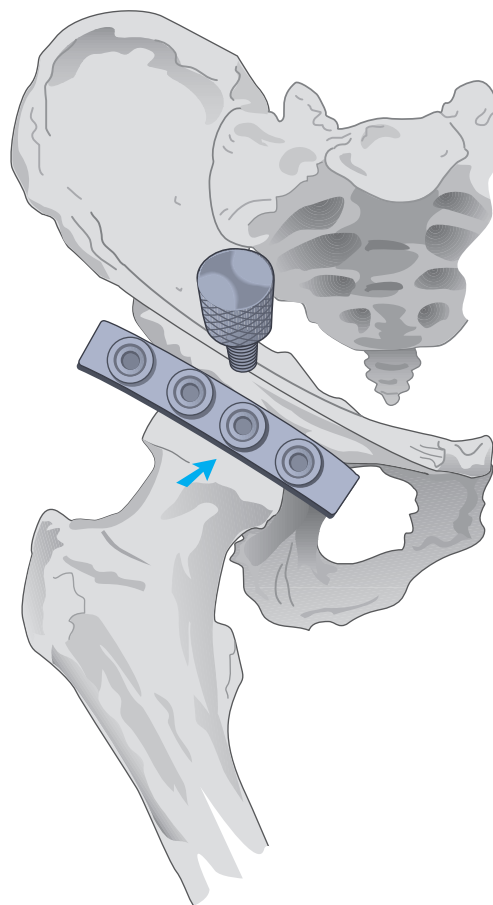
With the rod repositioned in the medullary canal, the handle is removed and the locating device is placed over the rod.



# The External Alignment System

A radiopaque marker is positioned over the ipsilateral hip, parallel and immediately distal to the inguinal ligament. An A/P roentgenogram indicates which of four markers most closely approximates the rotational centre.

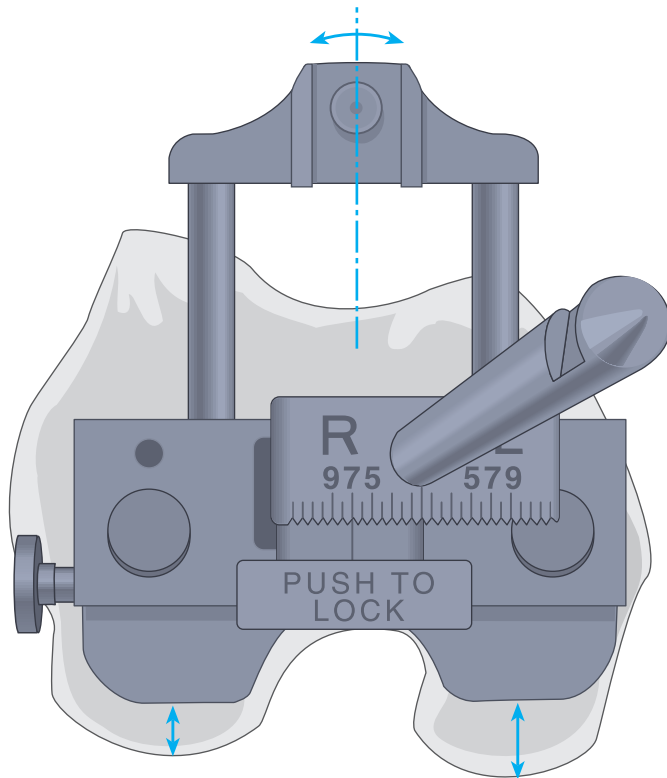
At surgery, the femoral-head locating strip is aligned with the markers. A target screw is introduced into the position overlying the rotational centre. Draping is such that the screw is readily palpated as the coxal reference points.



The alignment tower is assembled onto the femoral locating device. The alignment rod is passed through the hole and advanced to the hip. Where the rod fails to align with the coxal reference point, a different angle is selected.

**Note:** Where indicated, as in femoral deformity, 0° is selected and a short intramedullary rod is substituted. See Appendix II.

# Rotational Correction

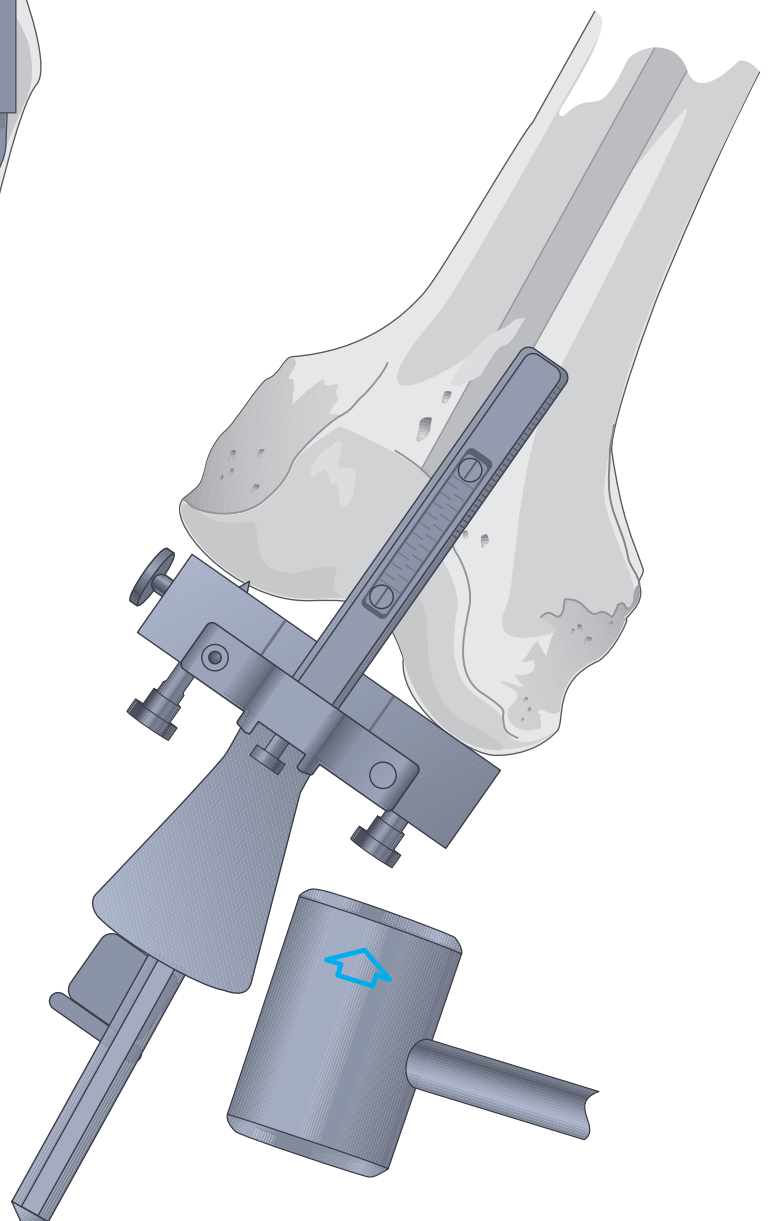


Orientation is initially determined with reference to the posterior femoral condyles, subject to subsequent correction at the A/P resection. The calibrated outrigger is centred at the femoral trochlea, placing it in slight external rotation and exposing a greater amount of medial condyle.

Alternatively, it may be externally rotated until perpendicular to the mechanical axis of the tibia in 90° of flexion.

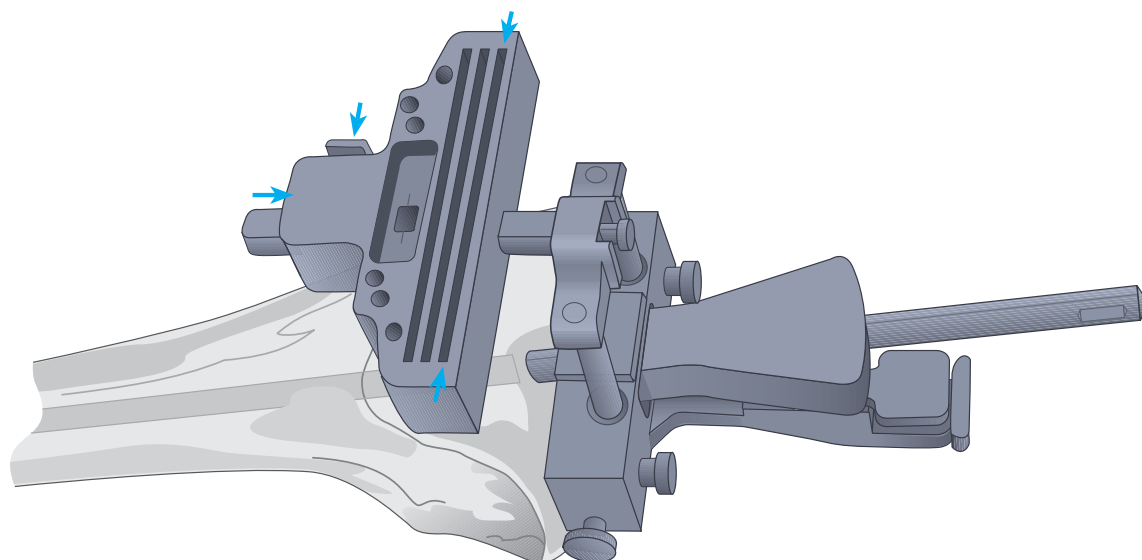
The femoral locating device is tapped into position at the more prominent condyle (usually the medial).

**Note: It is essential that firm contact be established at the subchondral level of the condyle, clear of any residual peripheral osteophytes.**





# The Distal Femoral Cutting Block

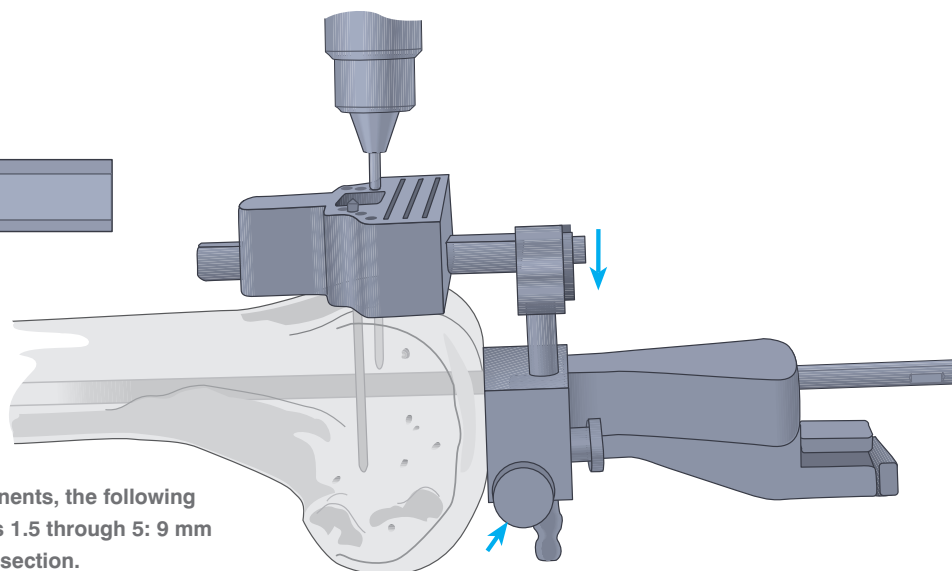
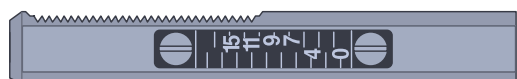

The cutting block is assembled onto the calibrated outrigger by depressing the button located on the right proximal end. The resection of the more prominent condyle, inclusive of residual cartilage, will correspond to the distal dimension of the femoral prosthesis. Where the femoral locating device rests on eburnated bone, resection is 2 mm less than the distal dimension of the femoral prosthesis to allow for absent cartilage and to avoid elevation of the joint line.

The scale for the numbers on the outrigger is even on the left and odd on the right. The number corresponding to the appropriate resection level is aligned with the inscribed line in the centre of the window of the distal femoral cutting block.

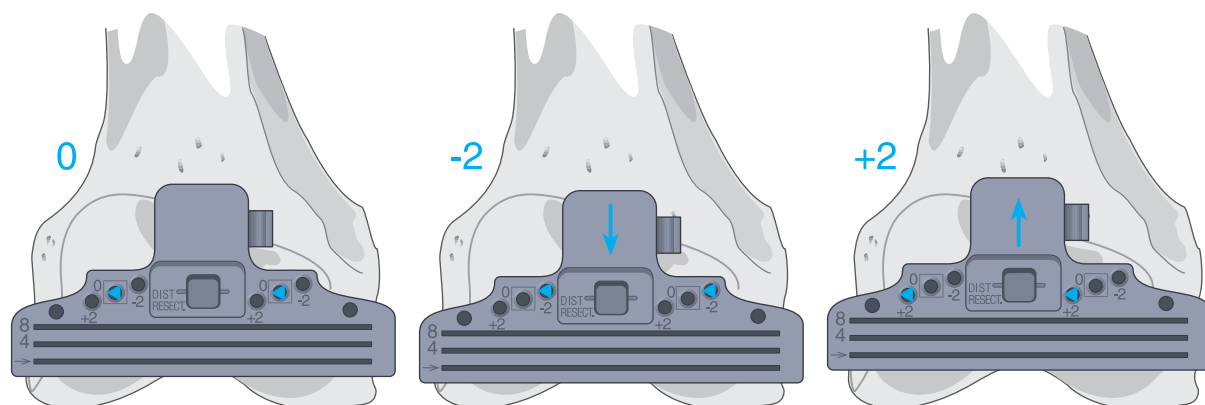
The base block is slotted; however, if used without the slot and the resection is initiated from the top of the block, 4 mm is added to the resection level. For example, if 9 mm is the desired resection level, add 4 mm to this and set the block at 13 mm and cut from the surface of the block. Note the top of the block is engraved "4 mm offset".

The outrigger and cutting block is lowered onto the anterior cortex by depressing the button on the left-hand side of the locating device. Either  $\frac{1}{8}$ " drill bits or Steinmann pins are introduced through the holes designated zero and enclosed in  's. They are advanced into the anterior cortex.



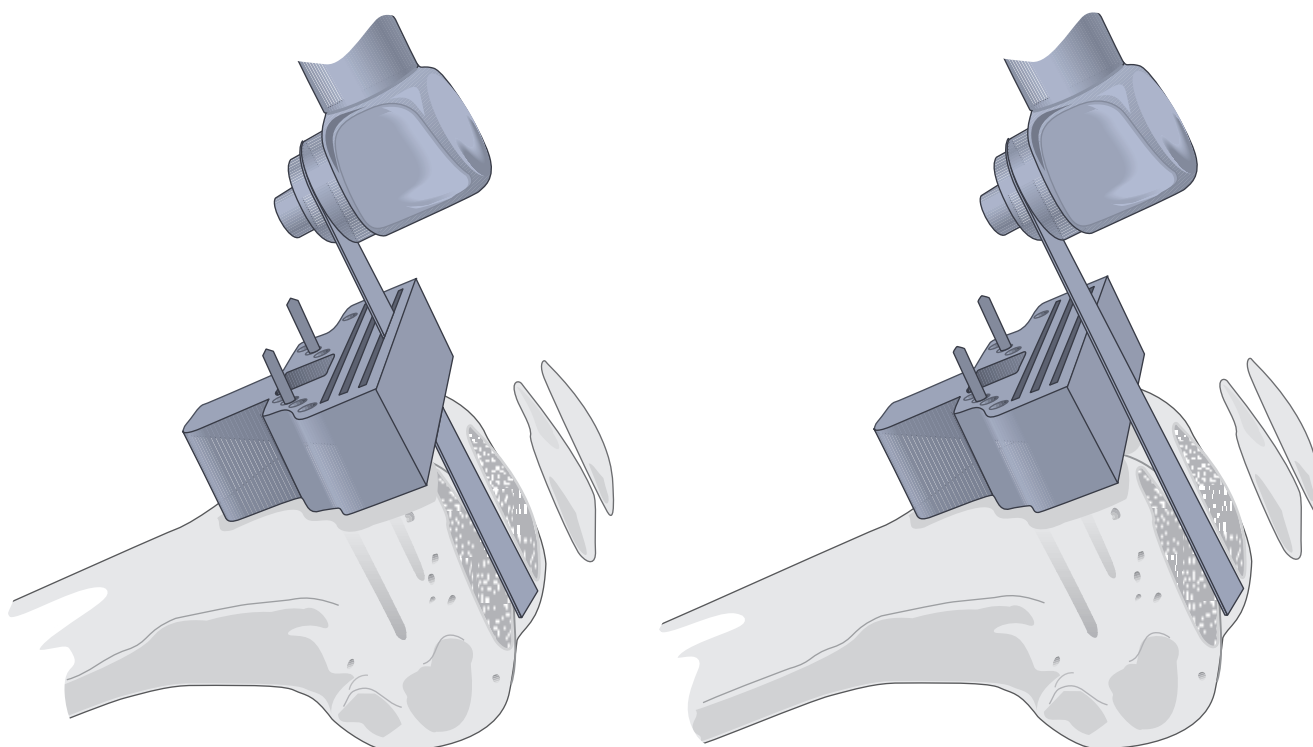
**Note:** For P.F.C.<sup>®</sup> Sigma Femoral components, the following distal resection is recommended: Sizes 1.5 through 5: 9 mm distal resection, size 6: 10 mm distal resection.

# The Distal Femoral Cut



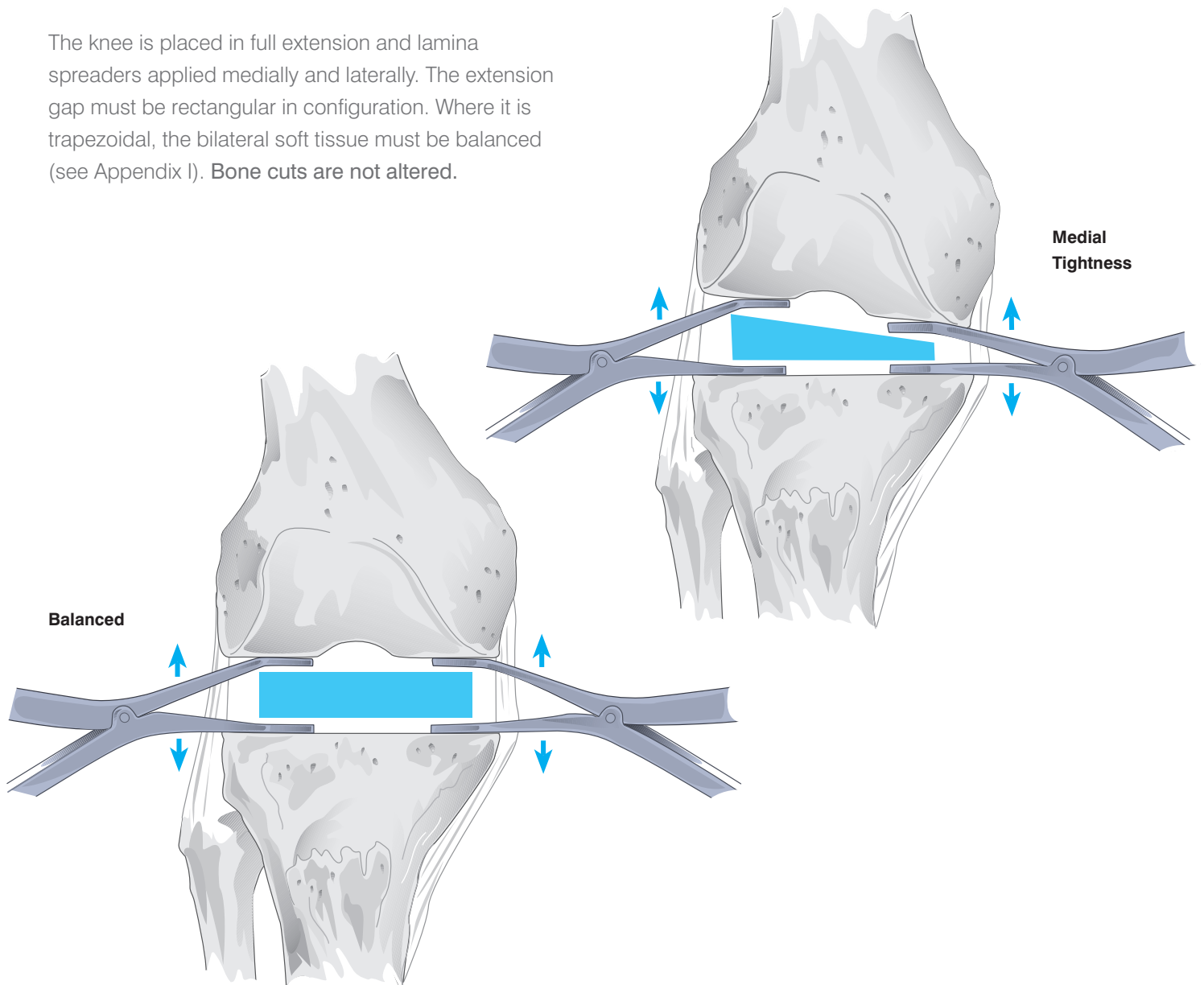
The locating device and intramedullary rod are disengaged from the cutting block by depressing the right button on the cutting block. The holes on the block are designated -2, 0, and +2, indicating in mm the amount of bone resection each will yield supplemental to that indicated on the calibrated outrigger.

The oscillating saw blade is positioned through the slot, or, where applicable, the blade is positioned flush to the top cutting surface of the block. The condyles are resected and the surface checked for accuracy.



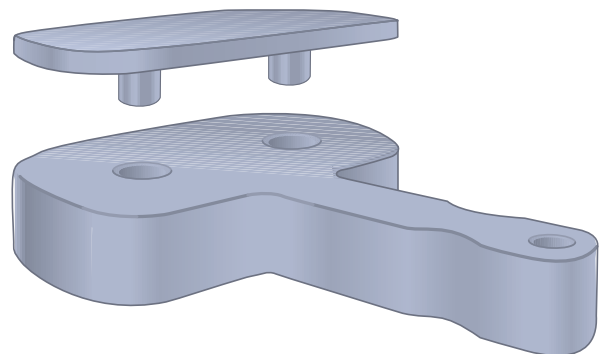
# Evaluating the Extension Gap

The knee is placed in full extension and lamina spreaders applied medially and laterally. The extension gap must be rectangular in configuration. Where it is trapezoidal, the bilateral soft tissue must be balanced (see Appendix I). **Bone cuts are not altered.**



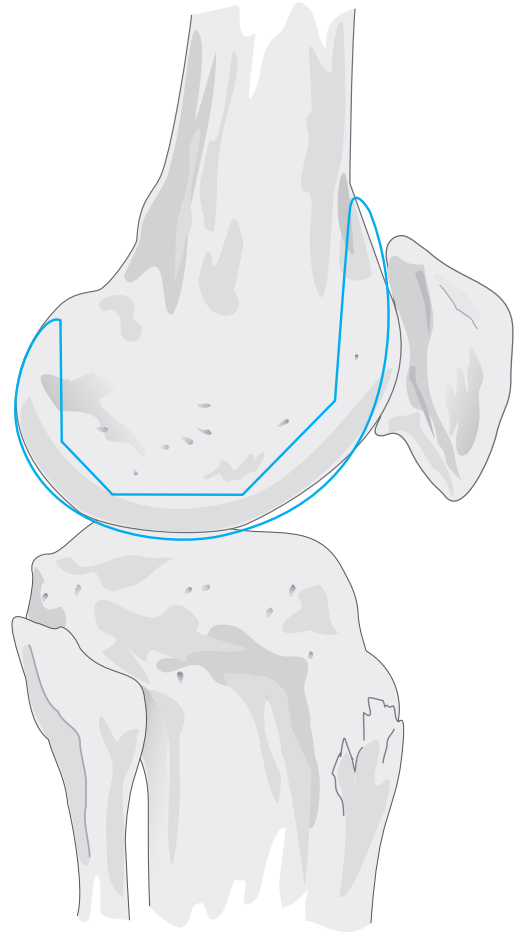
A set of spacer blocks measures the gap and indicates the appropriate thickness of the tibial insert, subject to re-evaluation at trial reduction.

When using blocks to assess flexion and extension gaps, a 1 mm shim should be used for the extension gap and the shim removed when assessing the flexion gap. This will compensate for the 1 mm difference between the distal and posterior resection levels.



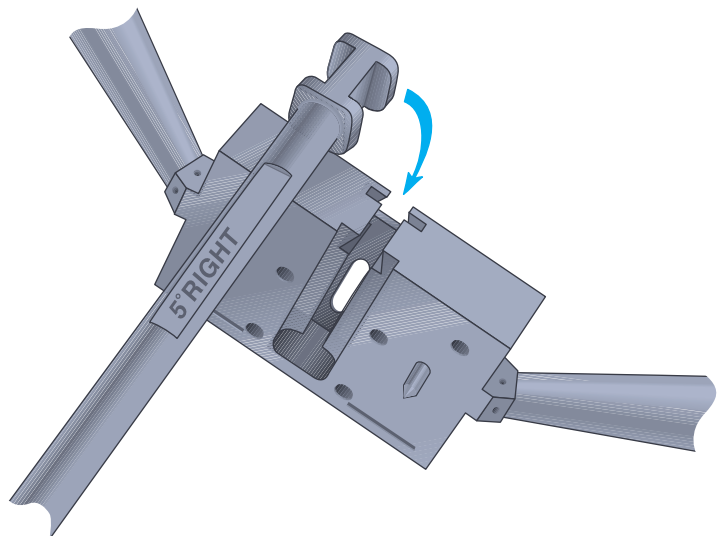
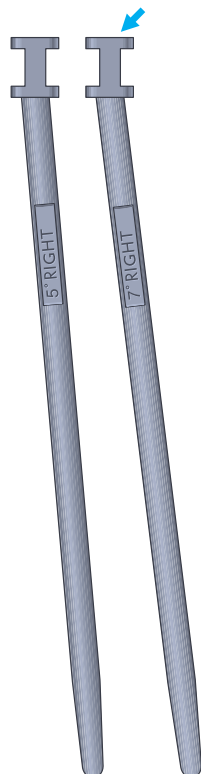
# Sizing the Femoral Component

Careful preoperative planning, including the application of templates to lateral radiographs, is critical to the sizing of the femoral component. Priority is given to reestablishment of the A/P dimension, as this will restore normal kinematics and quadriceps function. Under-sizing will cause looseness in flexion and possible notching of the anterior femoral cortex. Over-sizing will create tightness in flexion and increased tension in the quadriceps mechanism. Where a stabilising or constraining insert is used, a matched size relationship between the components must be maintained.



## Assembling the Femoral A/P Cutting Block

The appropriate rod is selected and assembled to the femoral A/P cutting block, the appropriate RIGHT/LEFT designation to the anterior. The pins are retracted.



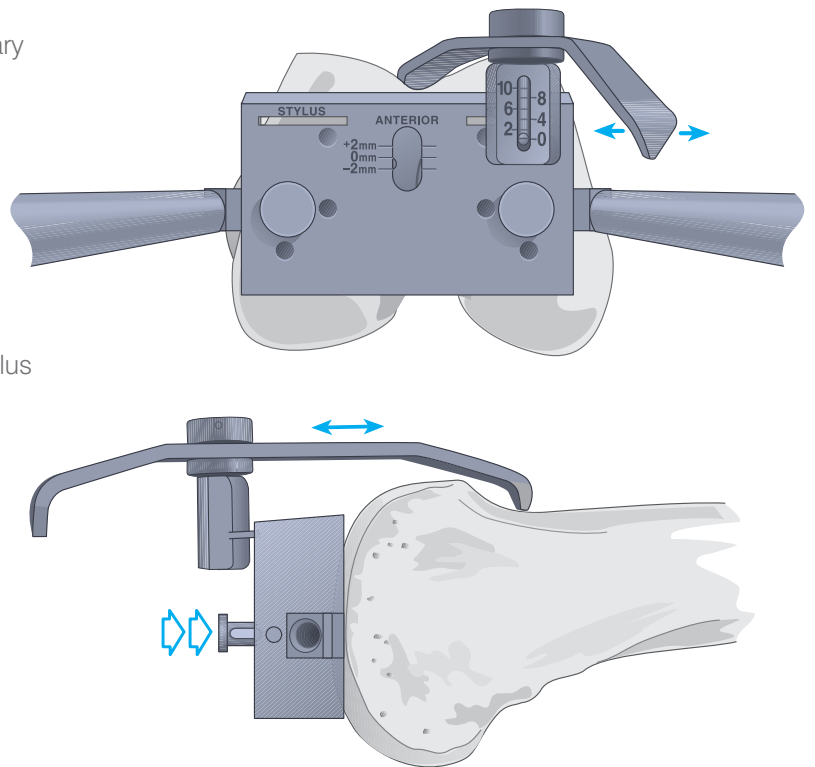
**Note:** Alternatively, the femoral sizing guide is used to position the size the component (see pages 14-20). With positioning established, any appropriate A/P cutting block may be used.

# Positioning the Cutting Block

The rod is introduced into the prepared intramedullary hole until the cutting block is seated flush to the cut distal surface.

The foot of the stylus assembly is fully seated in its receptacle on the anterior surface of the block such that it reads 0.

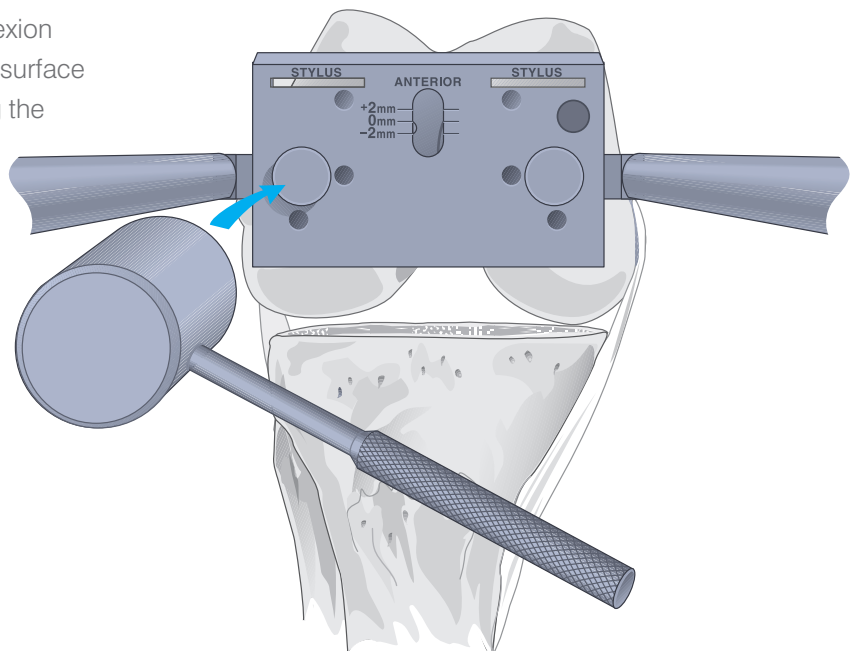
The cutting block is adjusted posteriorly until the stylus which has the arm marked non-slotted positioned toward the bone in contact with the anterior femoral cortex.



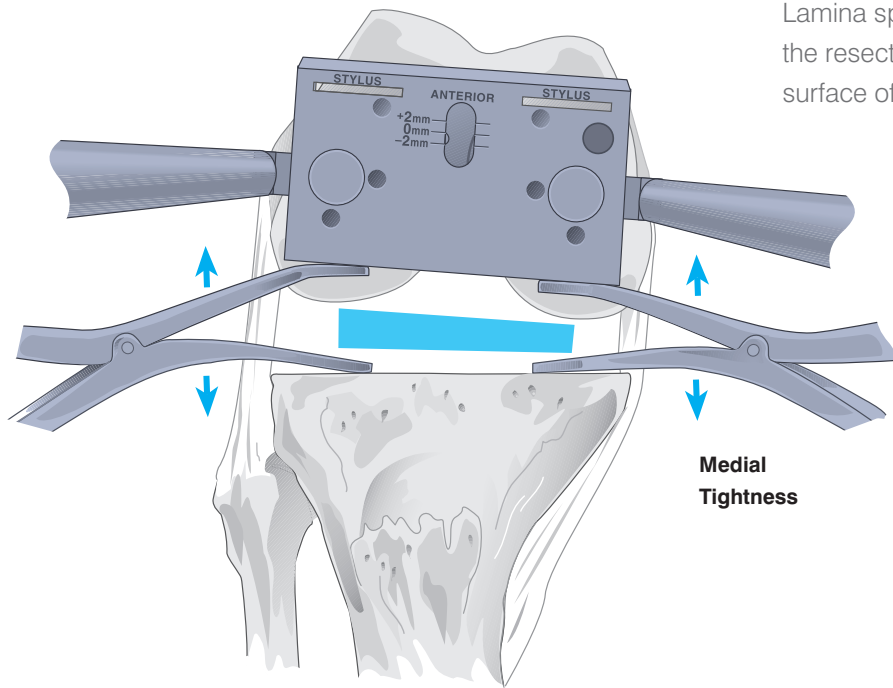
## Rotational Adjustment

Rotation is determined with the knee in 90° of flexion and the block positioned such that its posterior surface is parallel to the resected tibial plateau, creating the desired rectangular flexion gap.

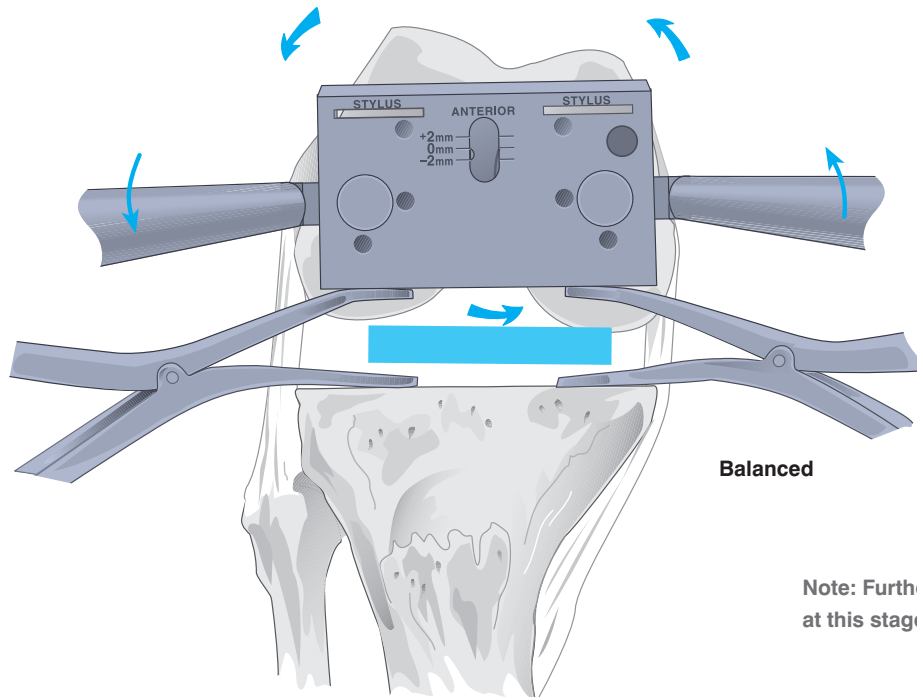
The retractable pins are subsequently tapped into the distal femur.



# Evaluating the Flexion Gap



Lamina spreaders are positioned bilaterally between the resected proximal tibial surface and the posterior surface of the block. Tension is applied.

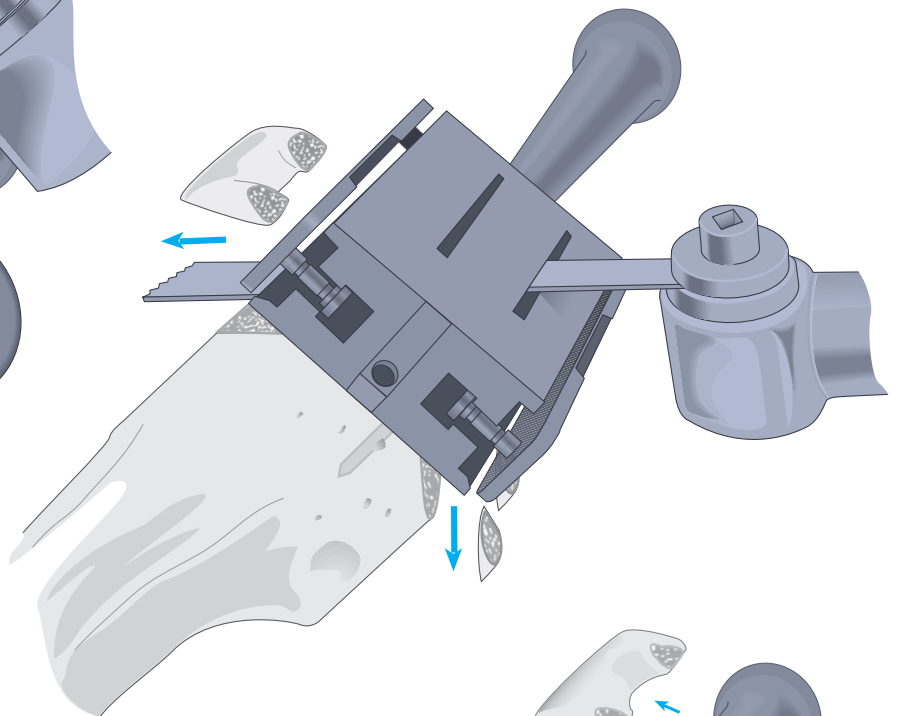

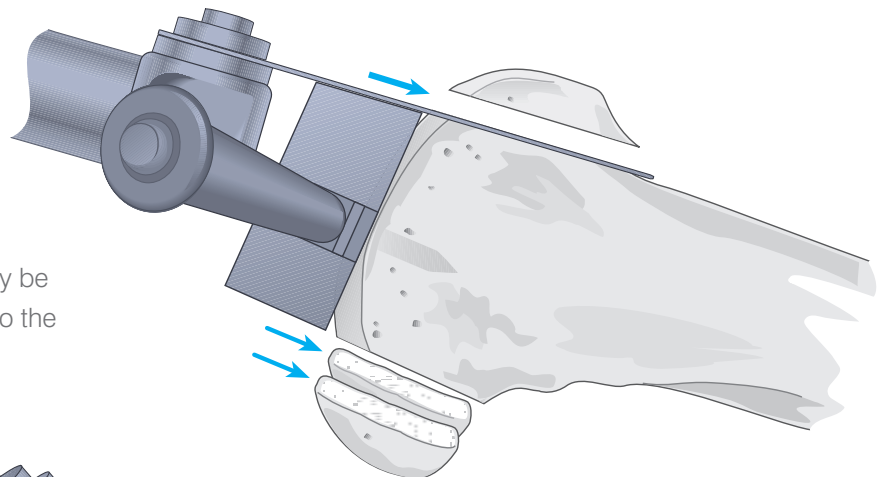


**Note:** Further ligamentous release is not recommended at this stage.

# Anterior and Posterior Femoral Cuts

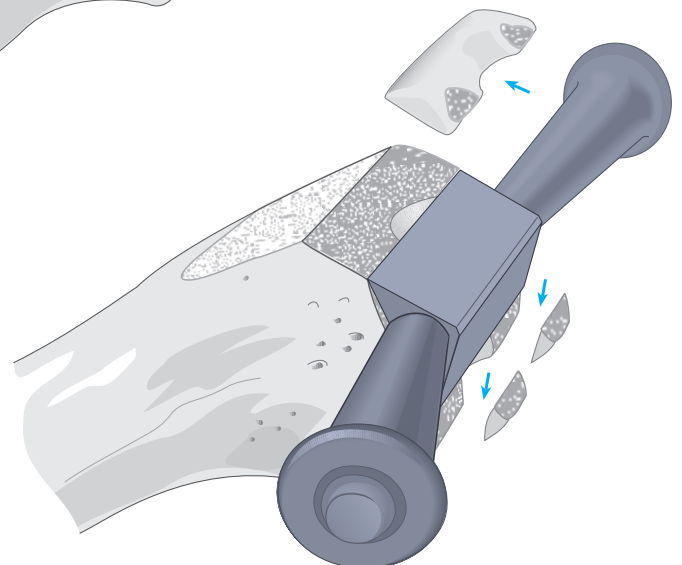
The anterior and posterior cuts are made with the blade of the oscillating saw held flush against the respective surfaces. The cuts are checked for accuracy and the cutting block removed.

Alternatively, the slotted A/P chamfer block may be substituted for the cutting block, positioned into the distal bilateral holes. A 1.19 mm saw blade is recommended.



The chamfer cuts can be made through the slotted A/P block at this time.

Alternatively, a separate chamfer block can be used to guide the anterior and posterior chamfer resections.

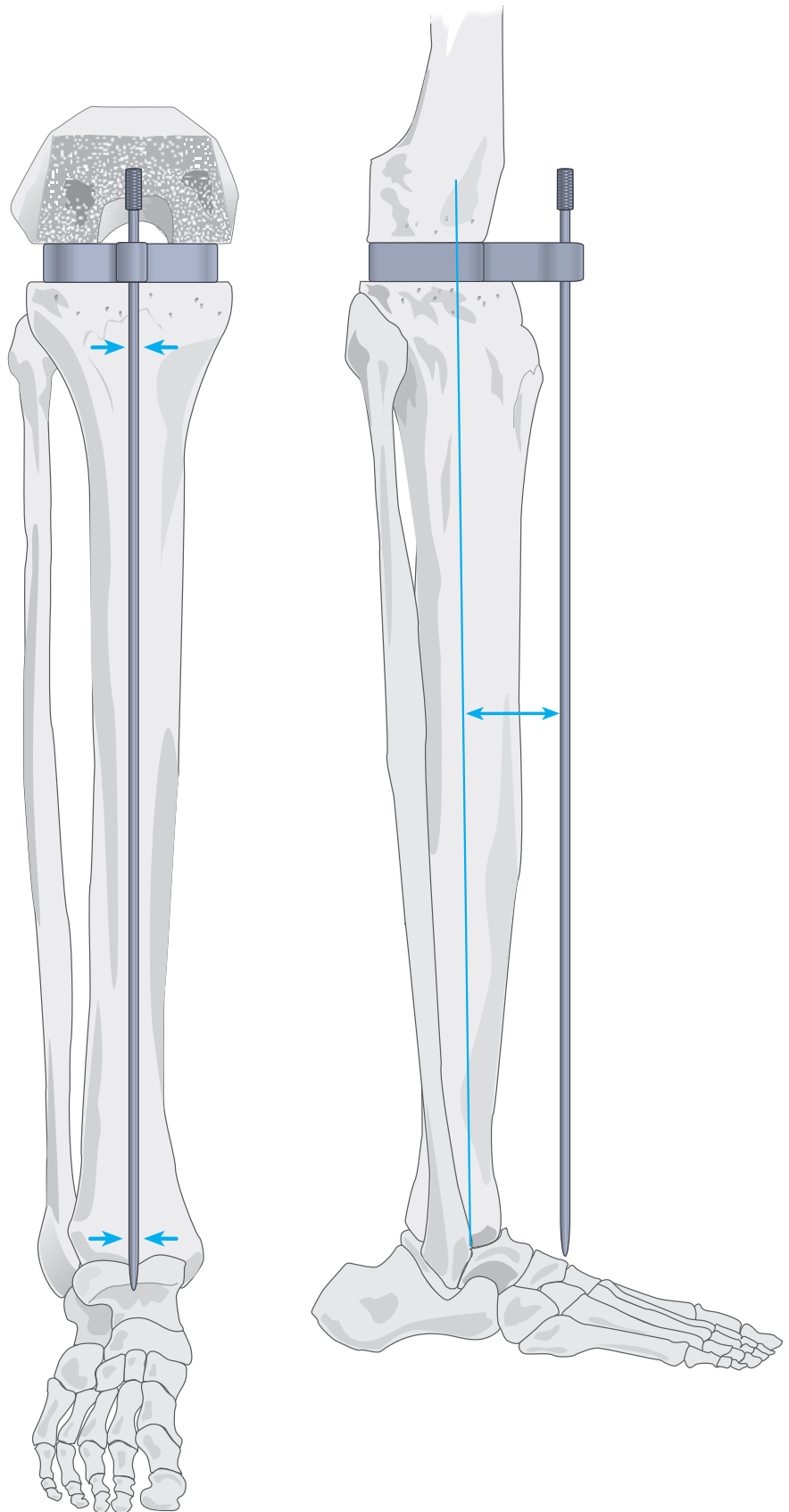


# Measuring Flexion Gap

Spacer blocks are used to measure the gap at 90° of flexion. When using blocks to assess flexion and extension gaps, a 1 mm shim should be used for the extension gap and removed when assessing the flexion gap. This will compensate for the 1 mm difference between the distal and posterior resection levels.

Where further distal femoral resection is required to establish equivalent flexion and extension gaps, the Steinmann pins are returned to their original position in the anterior femoral cortex and the distal femoral cutting block repositioned using the holes designated +2 and +4 as indicated.

The long alignment rod should pass through the centre of the talus and lie parallel to the lateral tibial axis.

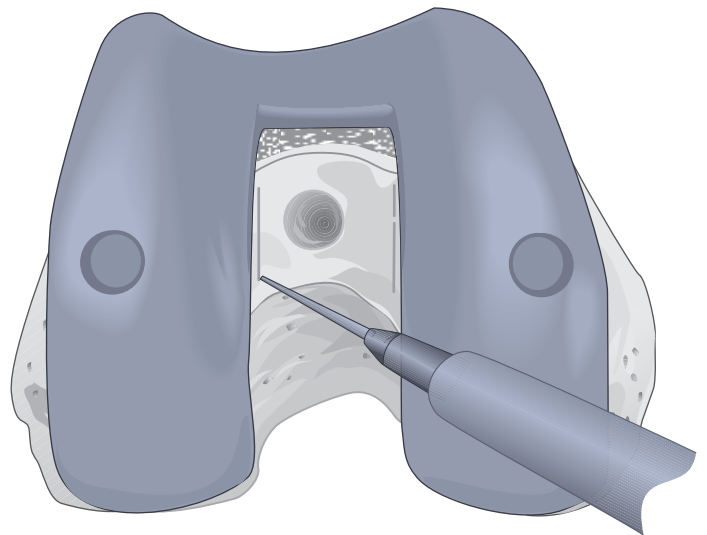
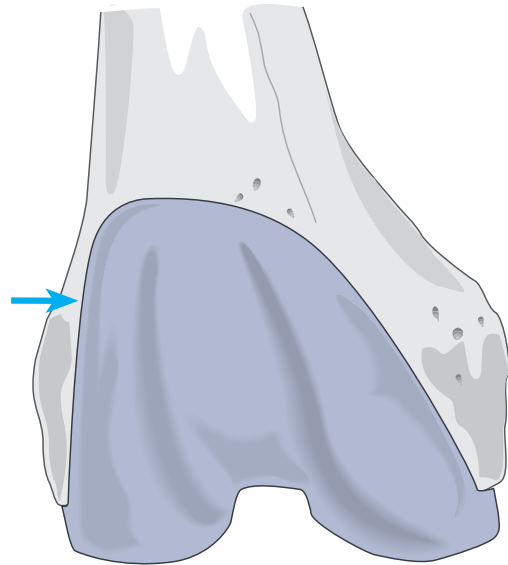




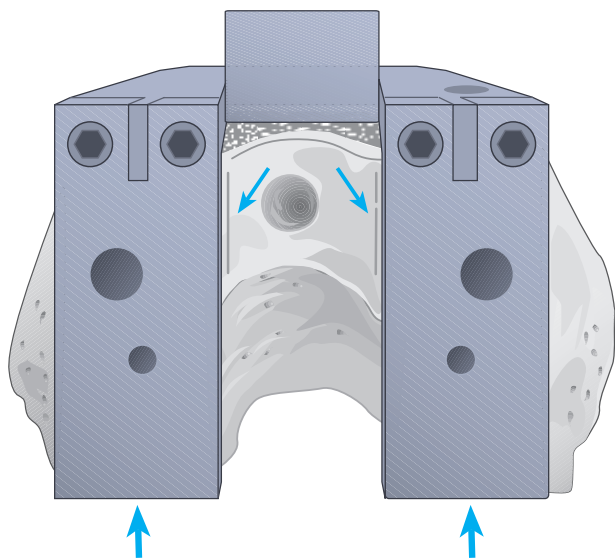
# The Femoral Notch Cut

Place the trial femoral component onto the prepared femur and position it such that the lateral flange of the trial component meets the lateral margin of the femur. Overhang of the flange is avoided where possible.

With an electrocautery, mark the medial/lateral location of the trial with lines drawn on the distal femur within each border of the intercondylar notch.



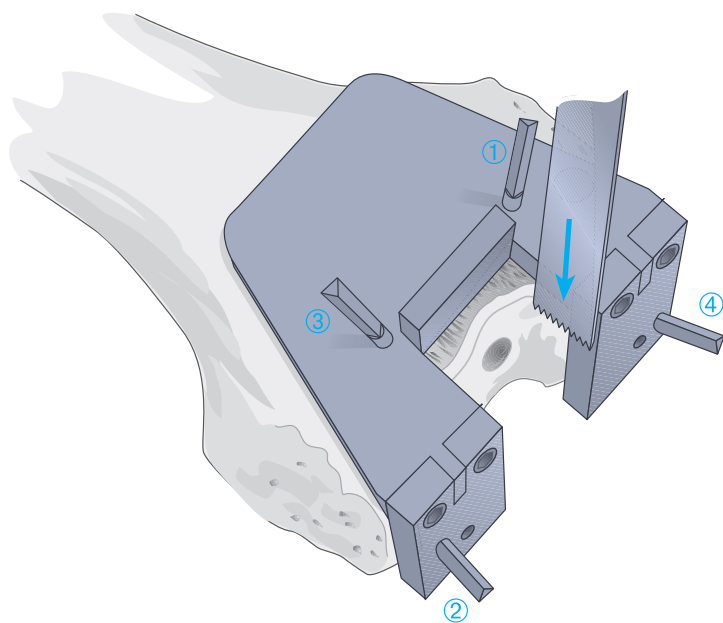
# The Femoral Notch Guide



The appropriate femoral notch guide is applied to the distal femur, seated flush upon the cut anterior and distal surfaces. It is centred about the two lines, previously made within the intercondylar notch.

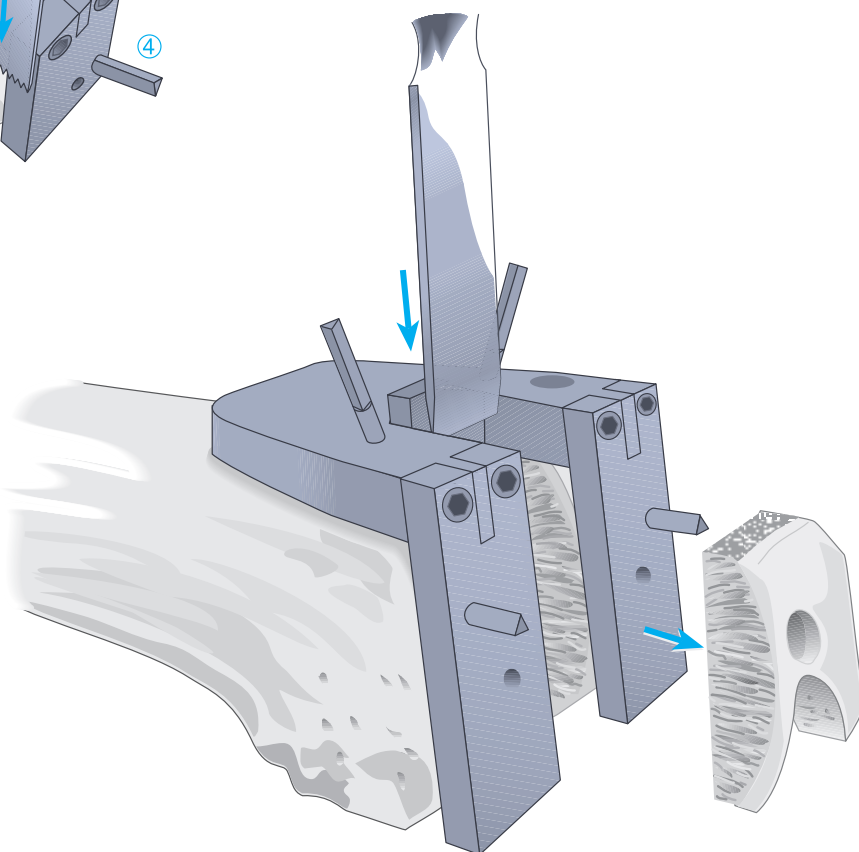
Where the posterior margins of the guide fail to align with the cut posterior condyles, the cuts are accordingly revised.

Steinmann pins are introduced in the sequence displayed: anterior (1), contralateral distal (2), anterior (3) and distal (4).



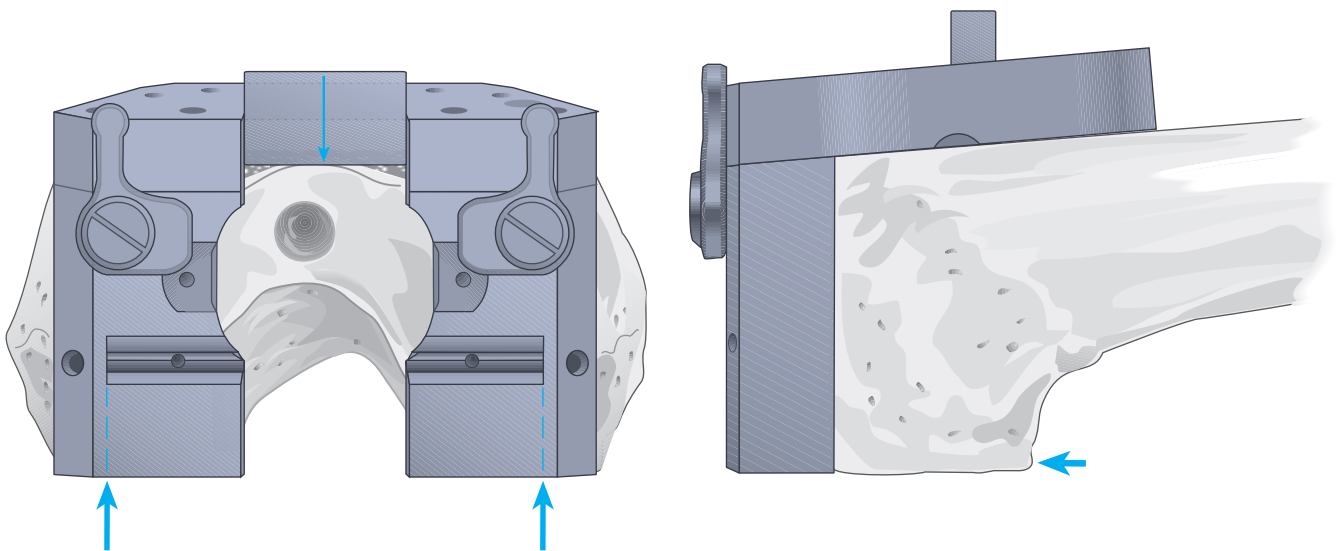
The notch is created with an oscillating saw and an osteotome.

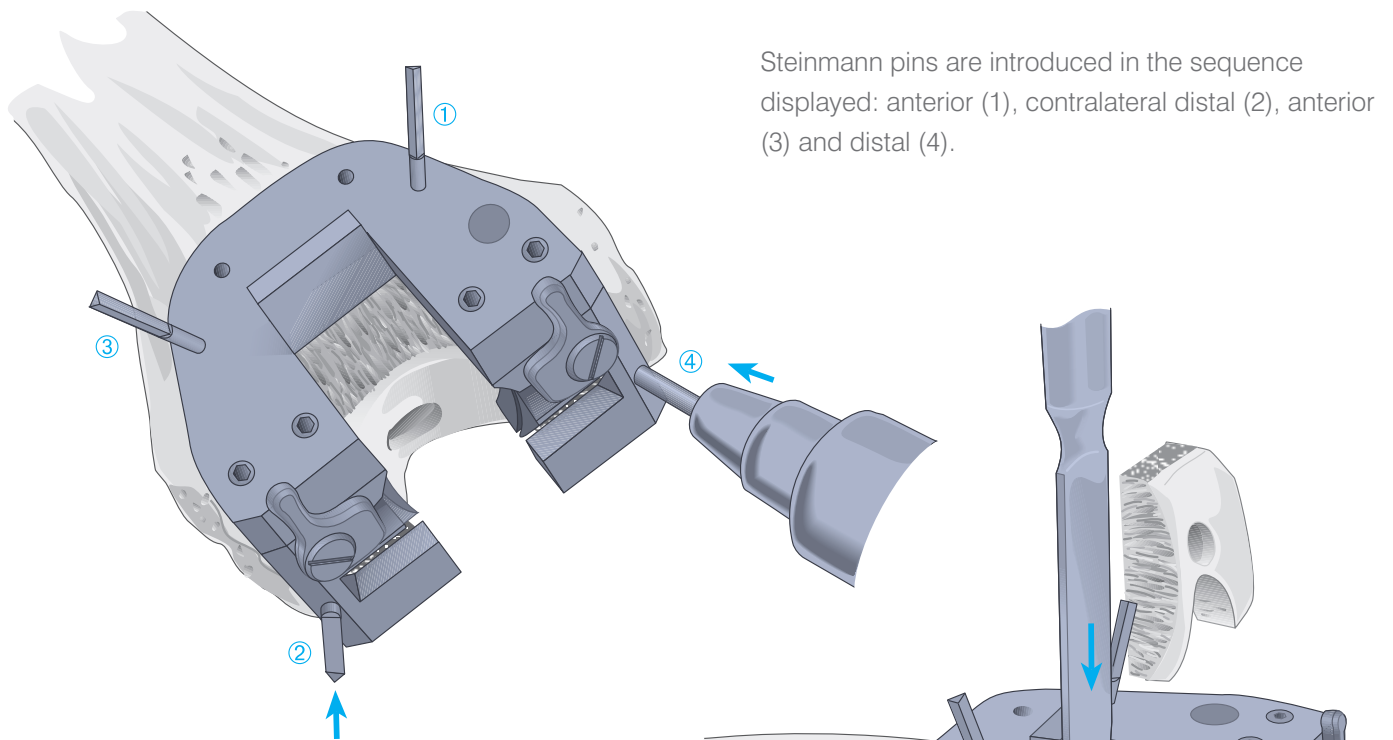
A ½" x 1.19 mm blade is recommended.



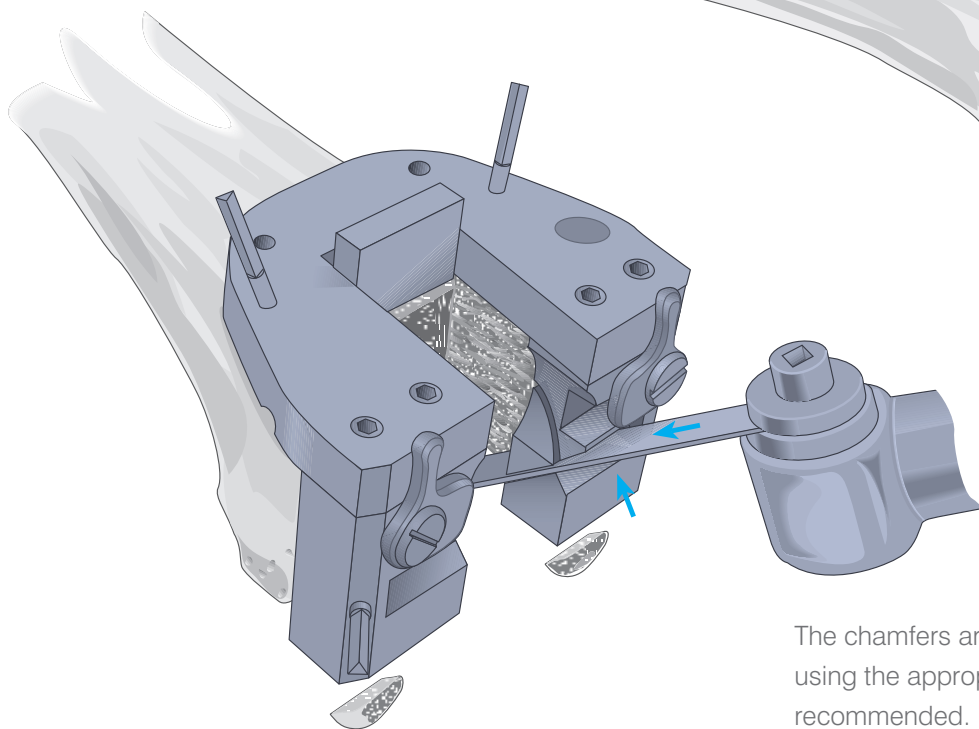
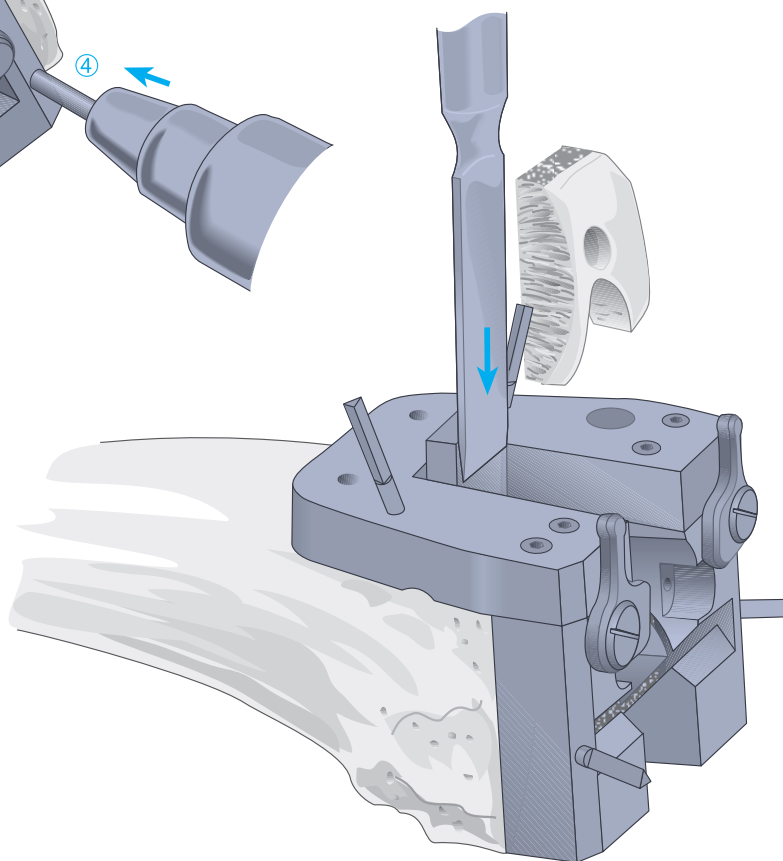
Alternatively, the femoral notch/chamfer guide may be employed for the notch and chamfer cuts.

The M/L size of the implant is given at the arrows indicated below. The mediolateral positioning of the guide is confirmed.





The notch is created with bilateral and superior transverse cuts, as described above.  
A  $\frac{1}{2}$ " x 1.19 mm saw blade is recommended.



The chamfers are fashioned with the oscillating saw using the appropriate slots. A 1.19 mm saw blade is recommended.

# Patellar Resurfacing

It is important that the sagittal dimension and accurate tracking are maintained and that adequate bone stock is preserved. Problems will arise from inadequate or oblique resection, resulting in greater thickness to the complex, asymmetric positioning of the implant, subsequent patellar tilt and implant wear.

It is important that sufficient soft tissue be freed at the prepatellar bursa to position the calipers at the anterior cortex.

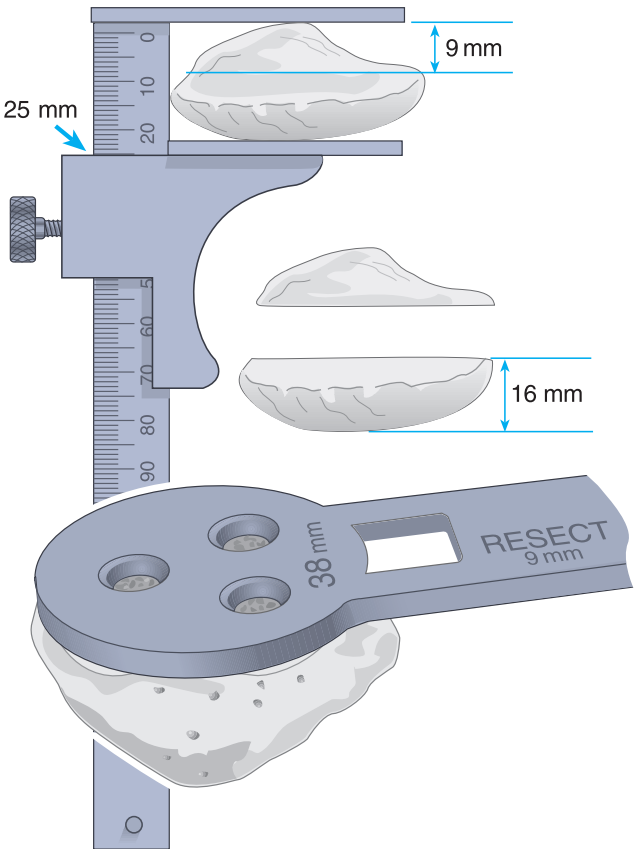
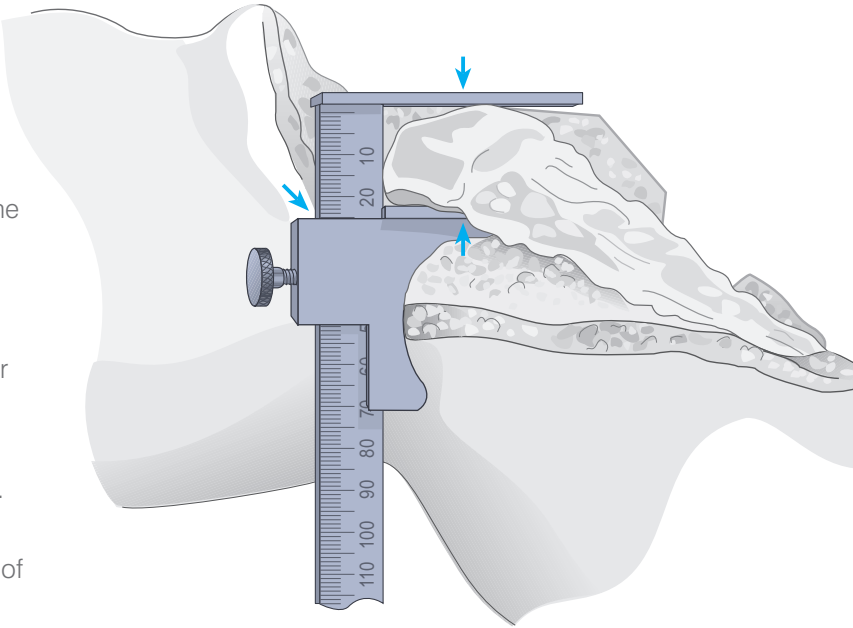
The greatest sagittal dimension is at the median ridge. The normal range is 20-30 mm. The dimension is established and an amount corresponding to the size of the selected implant subtracted. The remainder equals the target dimension following resection. Where the patella is small, a minimal residual dimension of 12 mm should be maintained.

**Example:** (for a 38 mm size dome or oval/dome patella)  
From a patella 25 mm thick, 9 mm of articular surface is resected, yielding 16 mm of residual bone to accommodate the 9 mm thick implant.

The template is selected that most adequately covers the articular surface without overhang. The handle is positioned on the medial side of the everted patella. Where bone is deficient on the lateral side, the next smaller size is selected, but positioned slightly to the medial side to enhance patellar tracking.

The amount of appropriate bone resection, as indicated on the template, is noted.

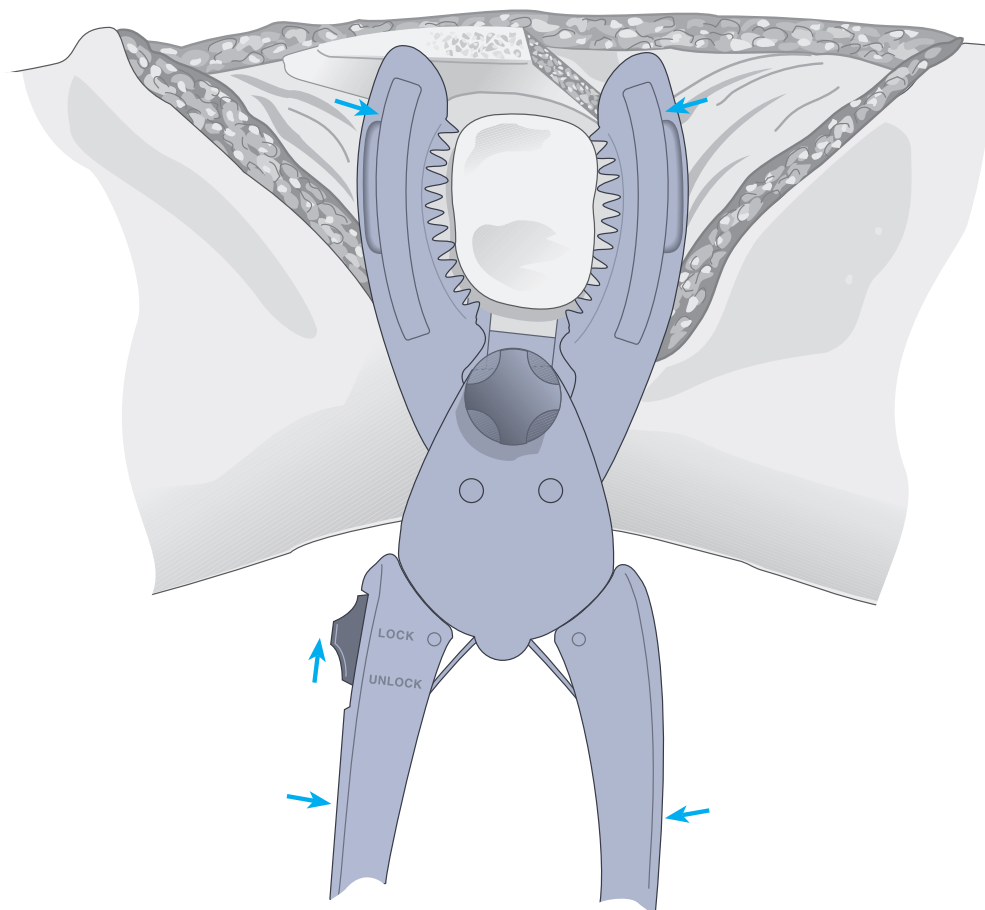
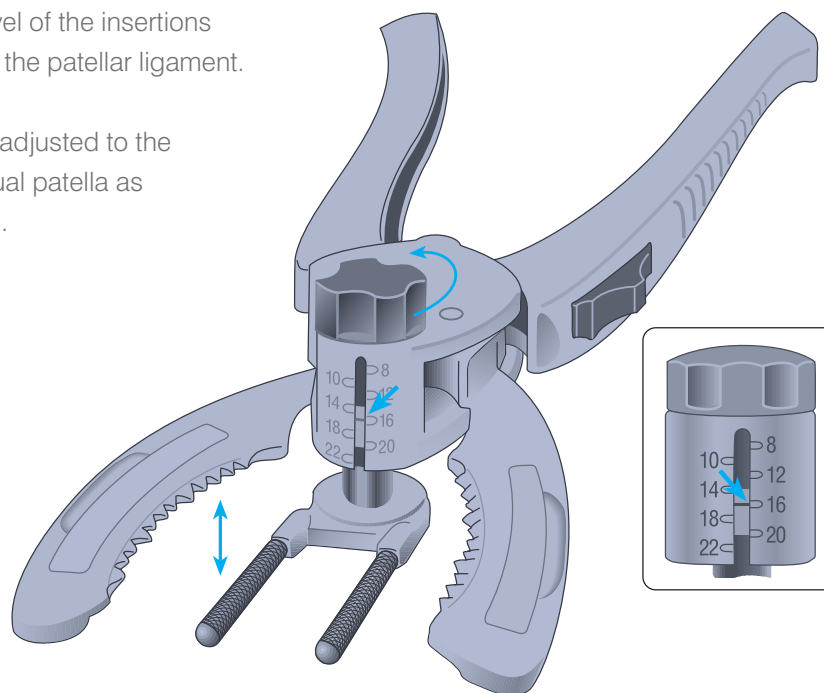
Patellar size	Resection
32 mm	8.0 mm
35 mm	8.5 mm
38 mm	9.0 mm
41 mm	11.5 mm



# The Patellar Cutting Guide

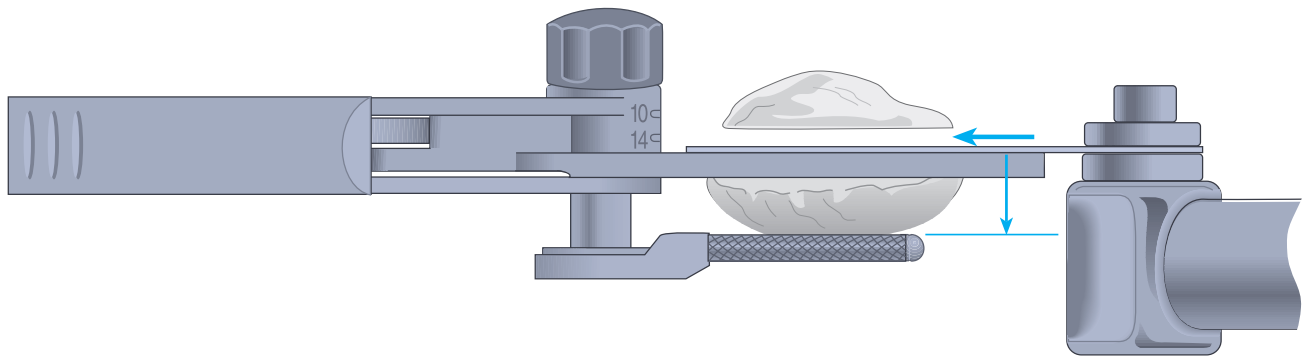
Synovial tissue is cleared to the level of the insertions of the quadriceps mechanism and the patellar ligament.

The prongs of the knurled fork are adjusted to the predetermined dimension of residual patella as indicated on the calibrated column.

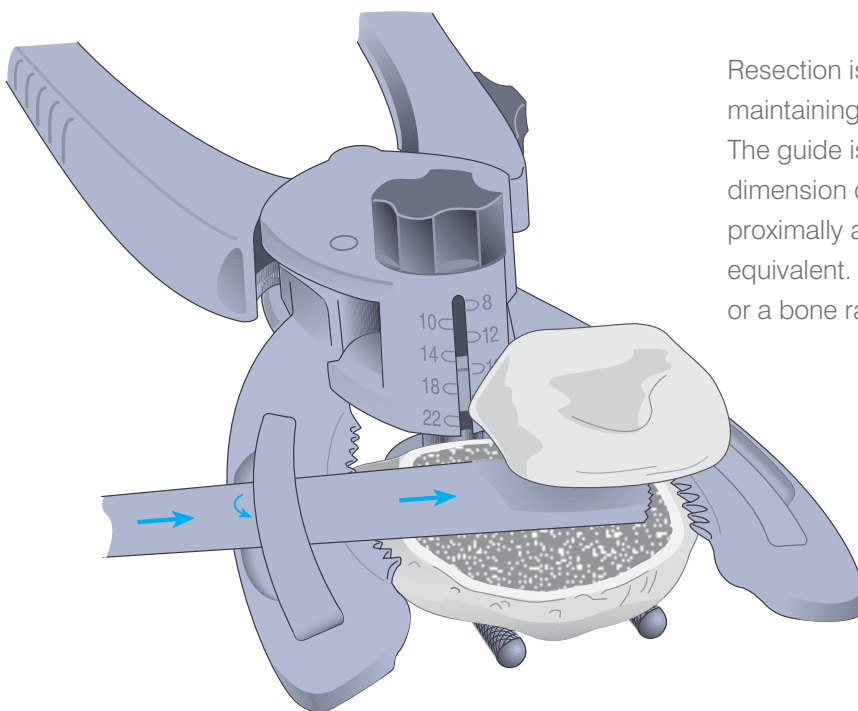


The leg is placed in extension, the cutting guide positioned with the prongs of the fork deep to the prepatellar bursa and against the anterior patellar cortex with the serrated jaws at the superior and inferior margins of the articular surface. The switch is placed to the LOCK position and the jaws closed to firmly engage the patella.

# Resection and Drilling

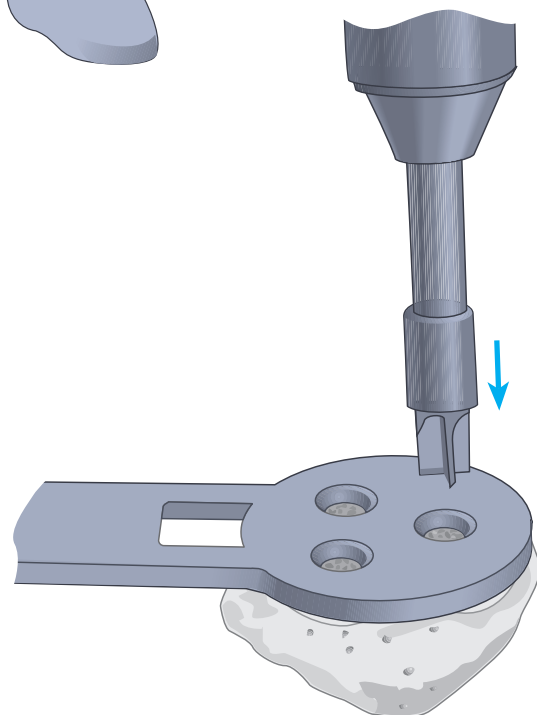


Resection is performed with an oscillating saw, maintaining the blade flush to the cutting surface. The guide is subsequently removed and the residual dimension checked with calipers, laterally, medially, proximally and distally. All measurements should be equivalent. Asymmetry is addressed with the saw or a bone rasp.



Alternatively, the saw blade is inserted into the well of the cutting surface of either of the jaws. The insert is lifted and the blade thereby confined within the slot created, ensuring that the cut will remain flush to the cutting surface. A 1.19 mm saw blade is recommended.

The previously selected template is positioned onto the cut surface with the handle positioned on the medial side of the everted patella, such that two drill holes lie at the medial side, one at the lateral. The template is firmly engaged to the resected surface and the hole fashioned with the appropriate drill bit.



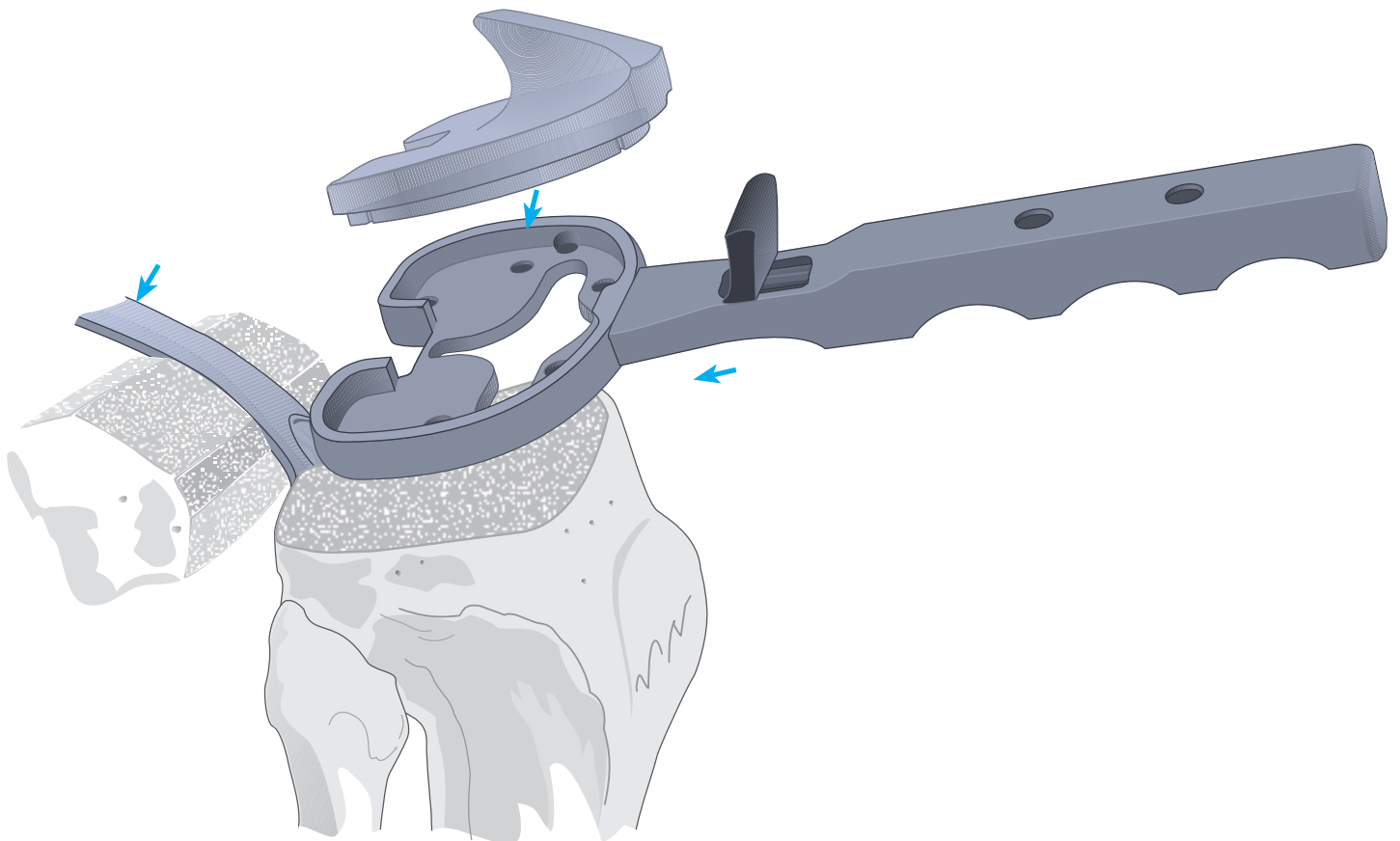
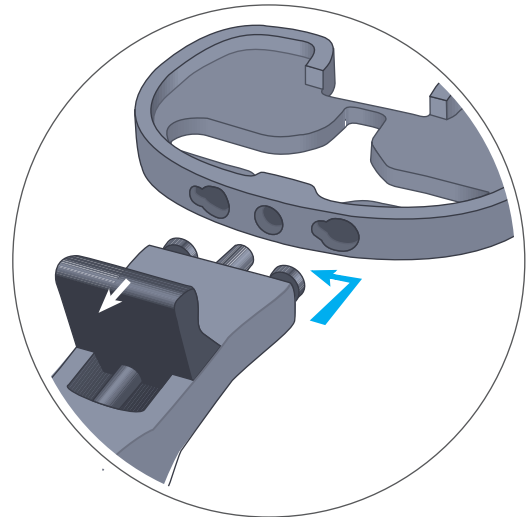# The Trial Tibial Component

With the knee in maximal flexion, the tibia is subluxed anteriorly with the tibial retractor.

The tibial tray is selected which provides the greatest coverage of the prepared surface without overhang anterior to the midcoronal plane.

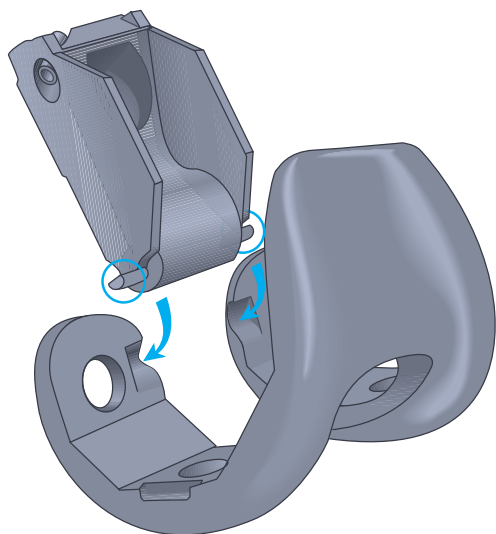
The tibial tray alignment handle is connected to the tibial tray trial by retracting the knob, inserting the two pins into the anterior portion of the tray trial, indexing the handle to the left and releasing the knob.

The appropriate colour-coded nylon trial is selected and inserted into the tray.





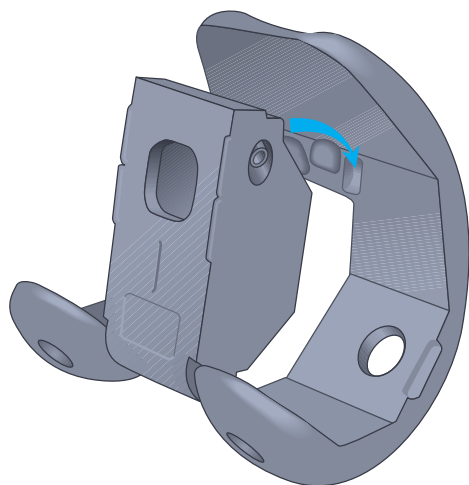
# The Trial Femoral Component



## The Femoral Component Box Assembly

1. Place the two outrigger tabs of the box trial into the recesses of the posterior condyles.
2. Insert the two anterior tabs into the recesses of the anterior flange.
3. Turn the angled screw, located in the side of the box, until tight.

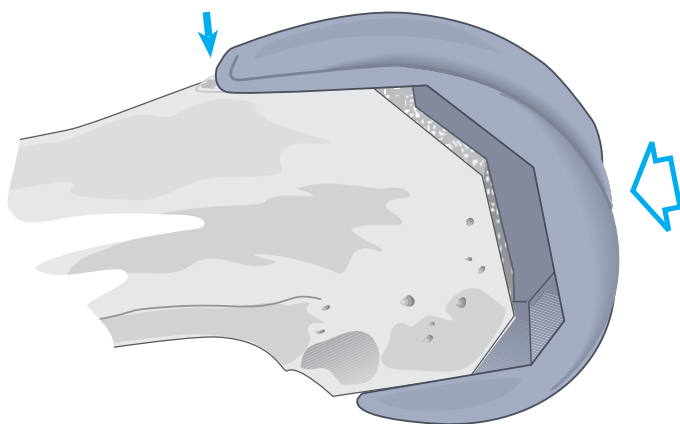
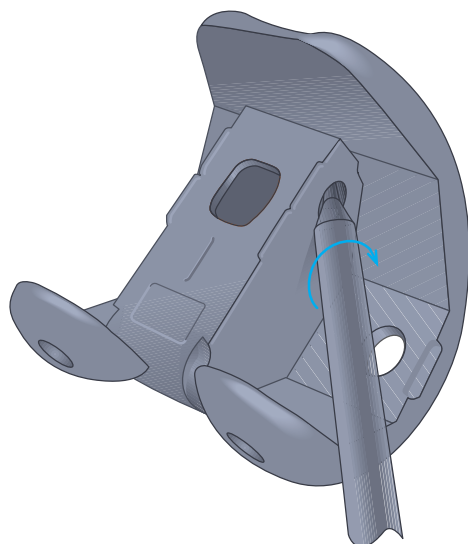
**Note: Do not overtighten the screw or attempt to remove the screw from the box trial as this will result in damage to the box trial attachment.**



The femoral trial is positioned on the prepared distal femur and the accuracy of the cuts is evaluated.

Where the component tends to rotate posteriorly (rocking into flexure) the A/P cuts may require adjustment. Where there is lateral rocking, the depth of the notch is inadequate.

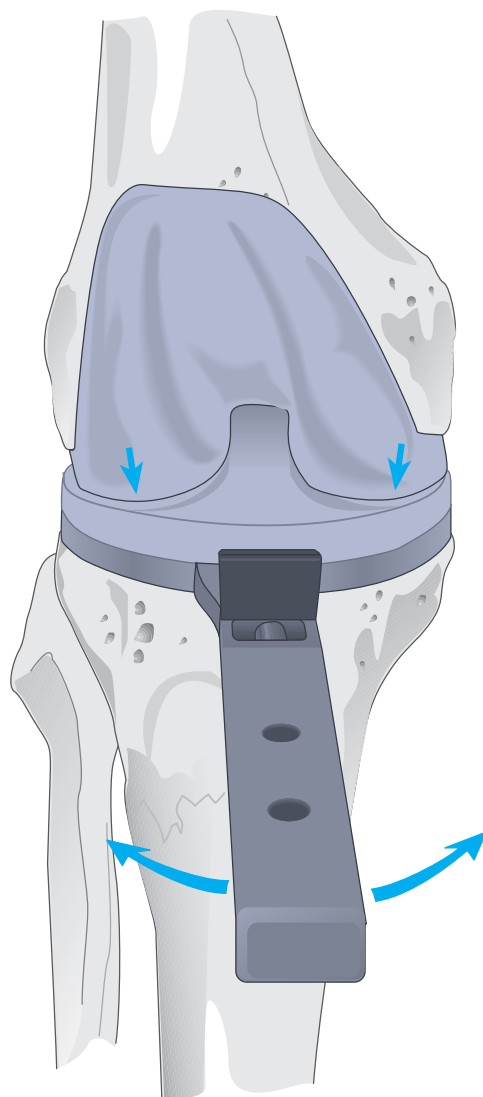
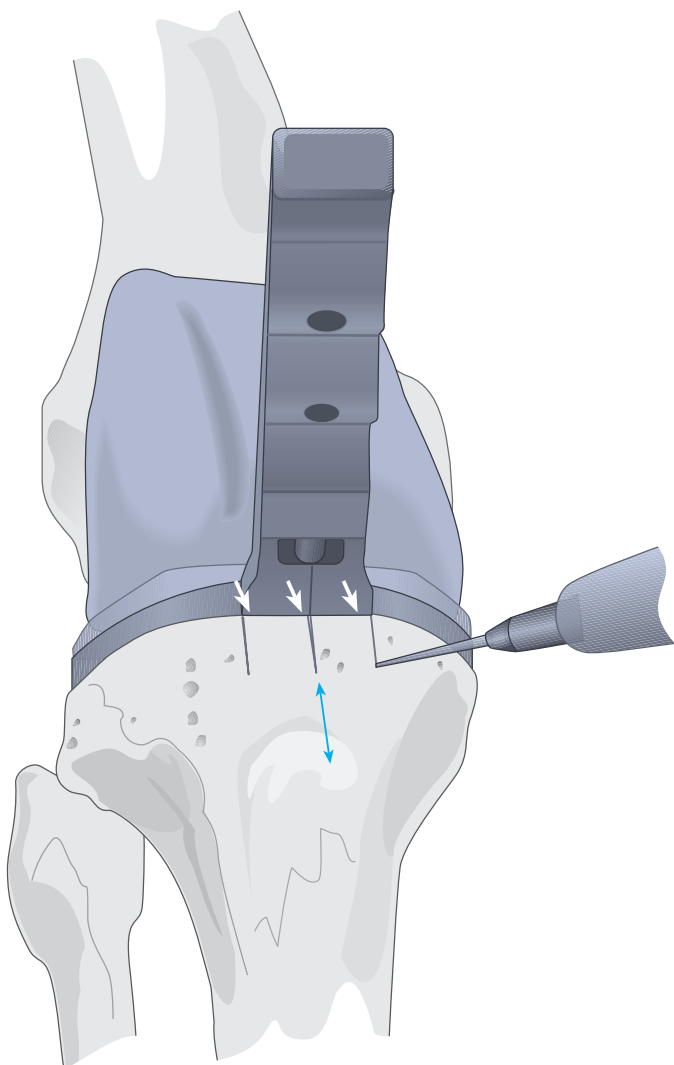
All appropriate modifications must be made at this time.



# Trial Reduction

With all trial prostheses in place, the knee is carefully and fully extended, noting medial and lateral stability and overall alignment in the A/P and M/L plane. Where there is any indication of instability, the next greater size tibial insert is substituted and reduction repeated. The insert that gives the greatest stability in flexion and extension and allows full extension is selected. Where there is a tendency for lateral subluxation or patellar tilt in the absence of medial patellar influence (thumb pressure), lateral retinacular release is indicated.

Rotational alignment of the tibial tray is adjusted with the knee in full extension, using the alignment handle to rotate the tray and trial insert into congruency with the femoral trial.

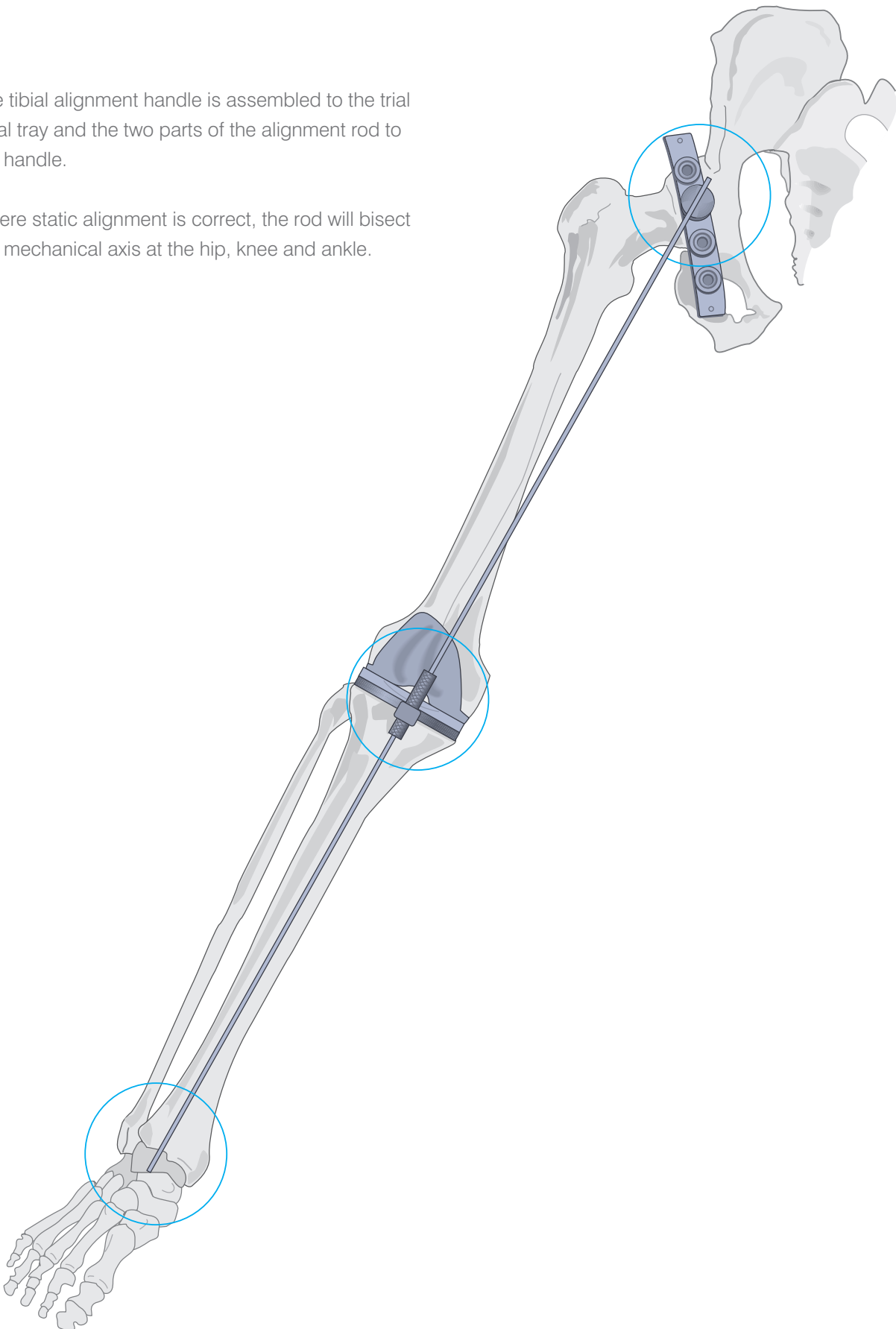


The appropriate position is marked with electrocautery on the anterior tibial cortex.

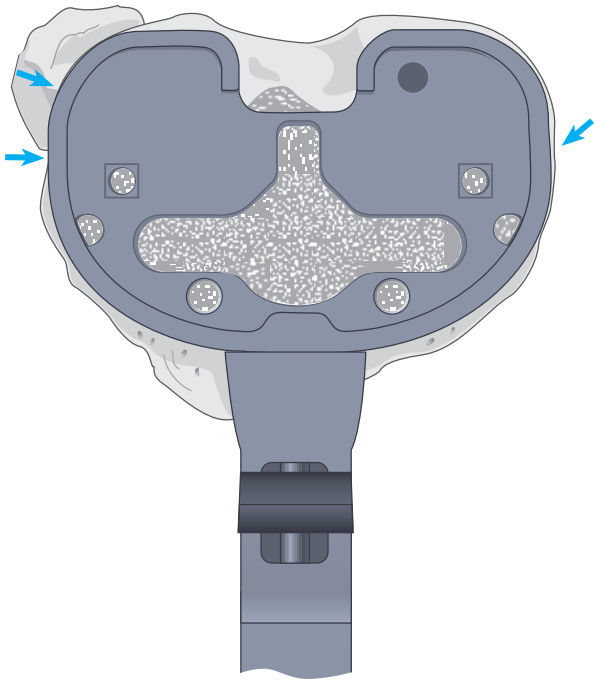
# Overall Alignment

The tibial alignment handle is assembled to the trial tibial tray and the two parts of the alignment rod to the handle.


Where static alignment is correct, the rod will bisect the mechanical axis at the hip, knee and ankle.

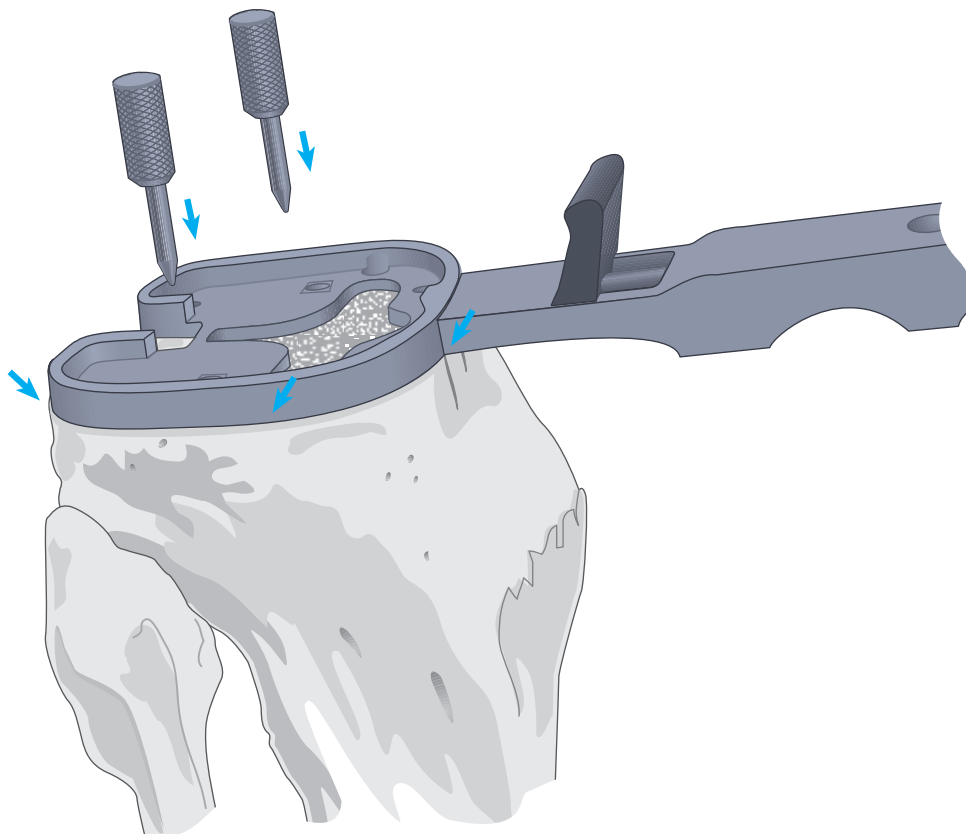


# Plateau Preparation

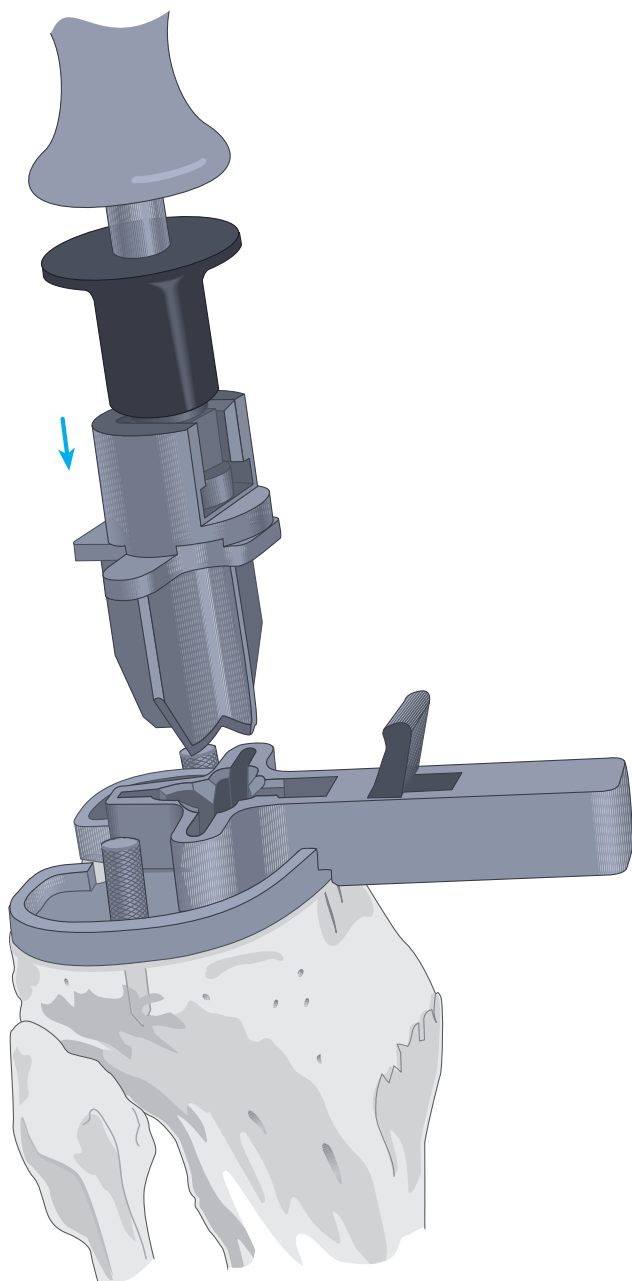


With the knee in full flexion and the tibia subluxed anteriorly, the trial tray is assembled to the alignment handle and placed onto the resected tibial surface. Care is taken that proper rotational alignment with the electrocautery marks is established.

The tray is secured with two short fixation pins inserted through the holes designated .



# P.F.C.® Cruciform Keel Tray Preparation

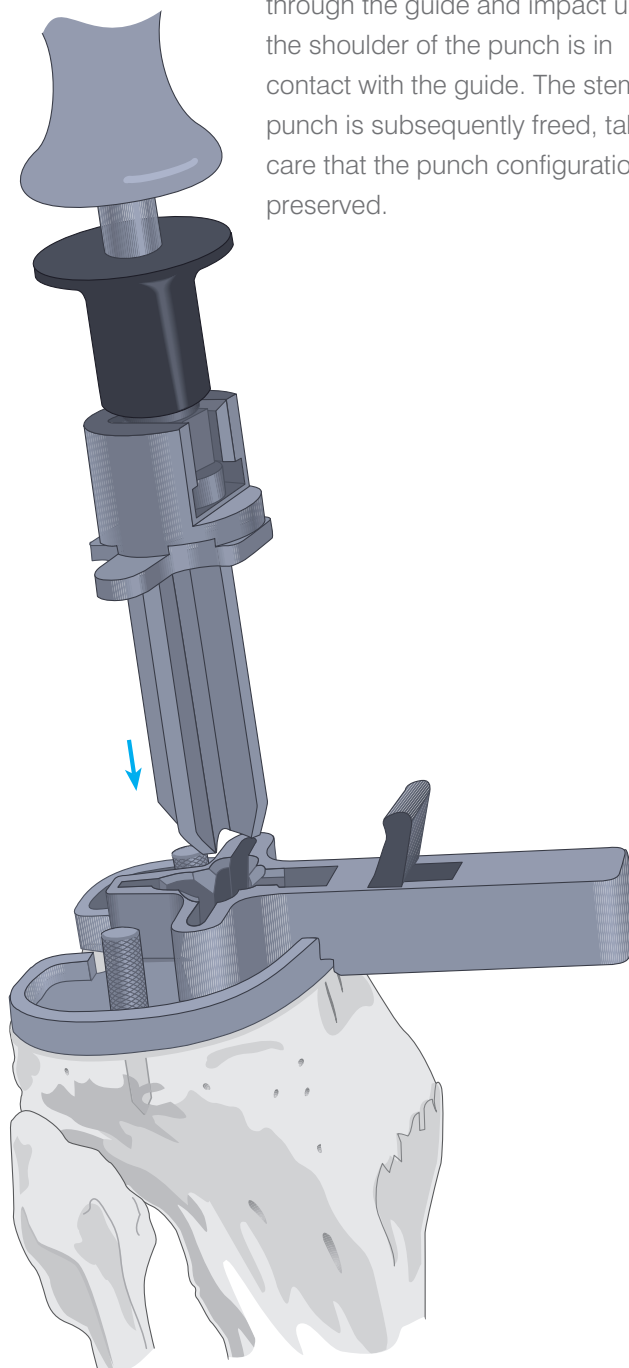


Where the cemented tray is to be implanted, assemble an appropriately sized cemented keel stem punch onto the slap-hammer and insert the punch through the guide and impact until the shoulder of the punch is in contact with the guide. The cemented stem punch is subsequently freed, taking care that the punch configuration is preserved.

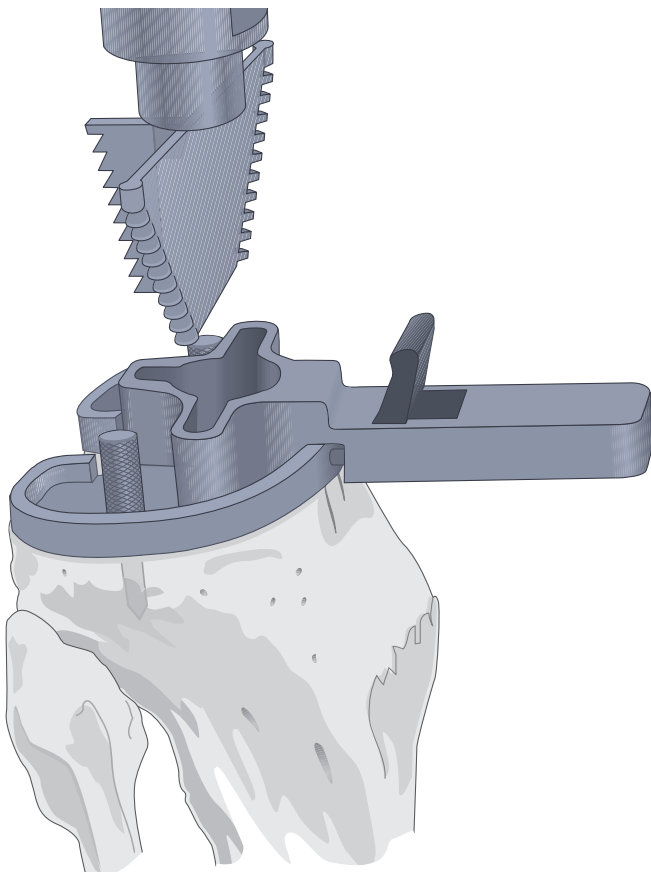
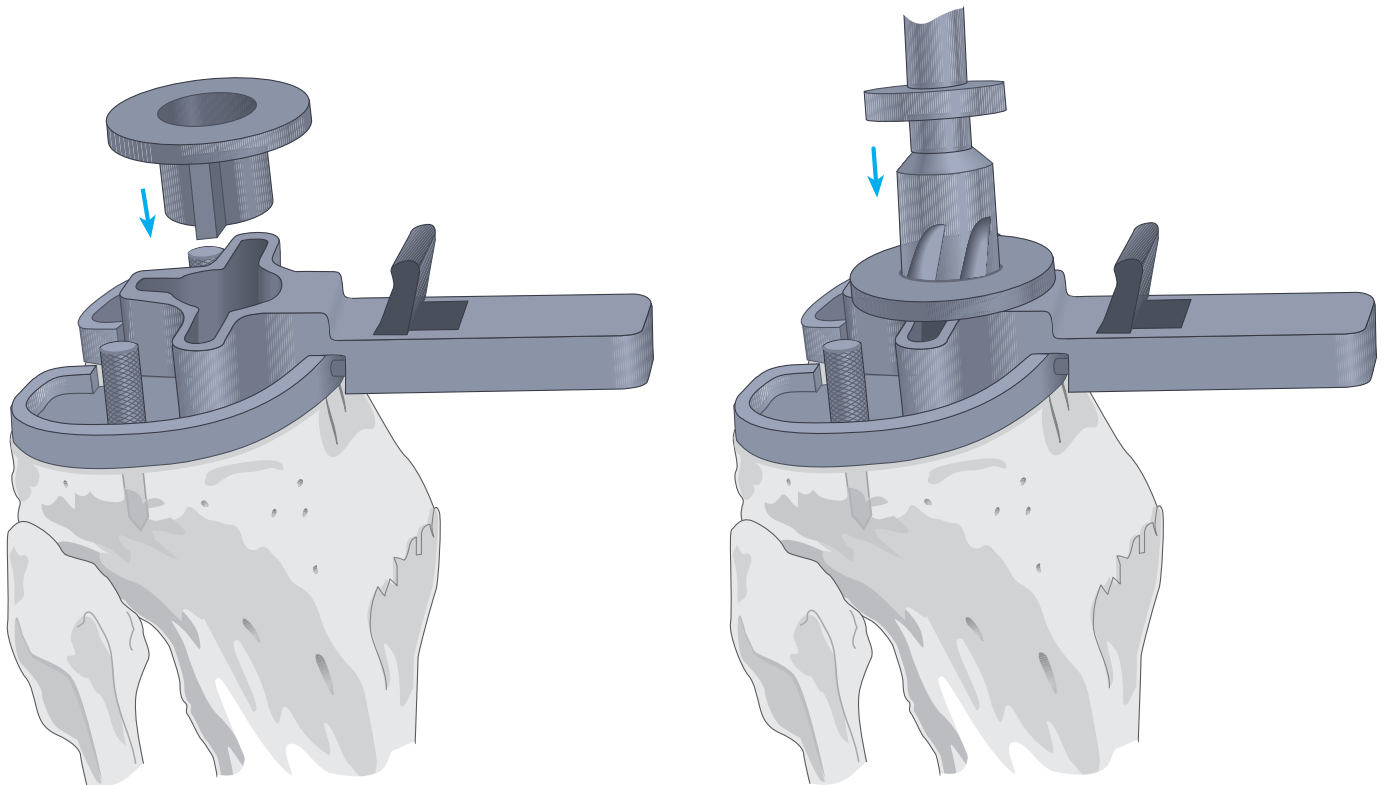
Remove the alignment handle from the tray trial and assemble the appropriately sized cruciform keel punch guide to the tray trial.

Where the non-cemented tray is to be implanted, assemble an appropriately sized non-cemented keel punch onto the slap-hammer and insert the punch

through the guide and impact until the shoulder of the punch is in contact with the guide. The stem punch is subsequently freed, taking care that the punch configuration is preserved.



# P.F.C.® Modular Tray & UHMWPE\* Tibia Preparation



Select the appropriate punch guide, drill bushing, drill and modular keel punch system. Remove the alignment handle from the tray trial and assemble the appropriately sized modular tray punch guide to the tray trial.

Seat the appropriately sized drill bushing into the modular tray punch guide.

The matching drill is fully advanced through the drill bushing into the cancellous bone.

The appropriately sized modular tray keel punch is subsequently positioned through the guide and impacted until the shoulder of the punch is in contact with the guide. The modular tray keel punch is subsequently freed, taking care that the punch configuration is preserved.

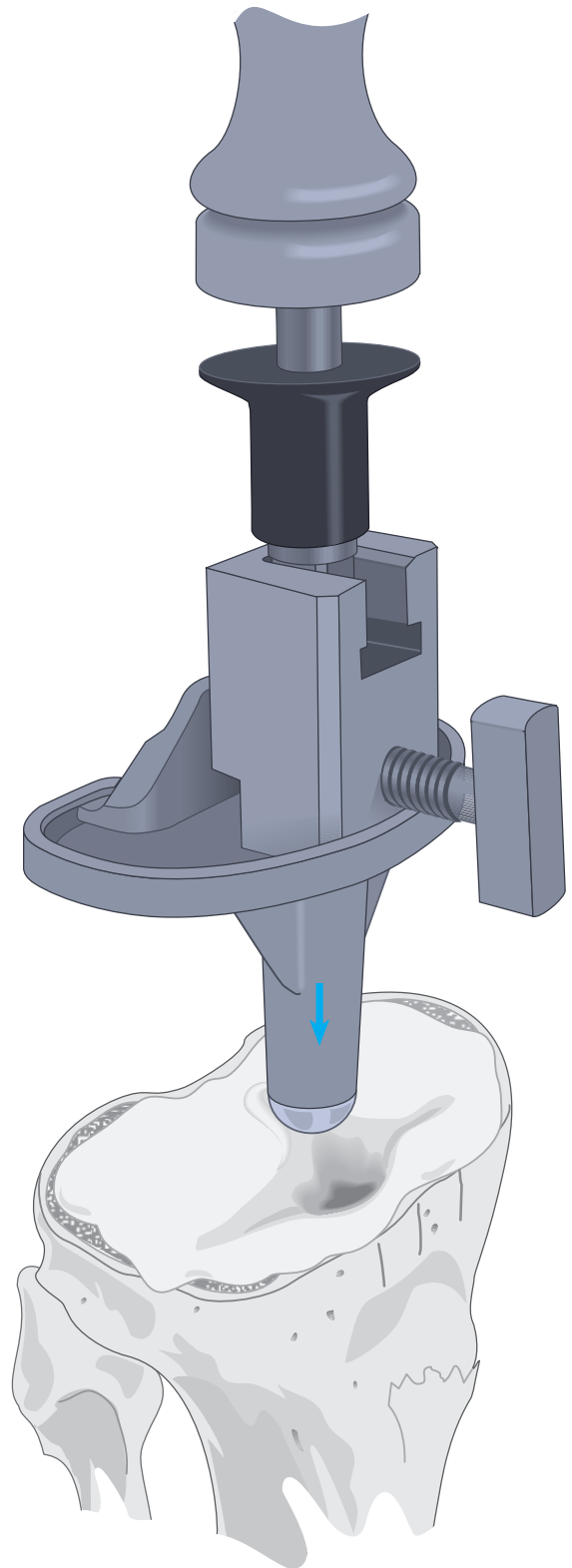
**\*UHMWPE (All-poly)**

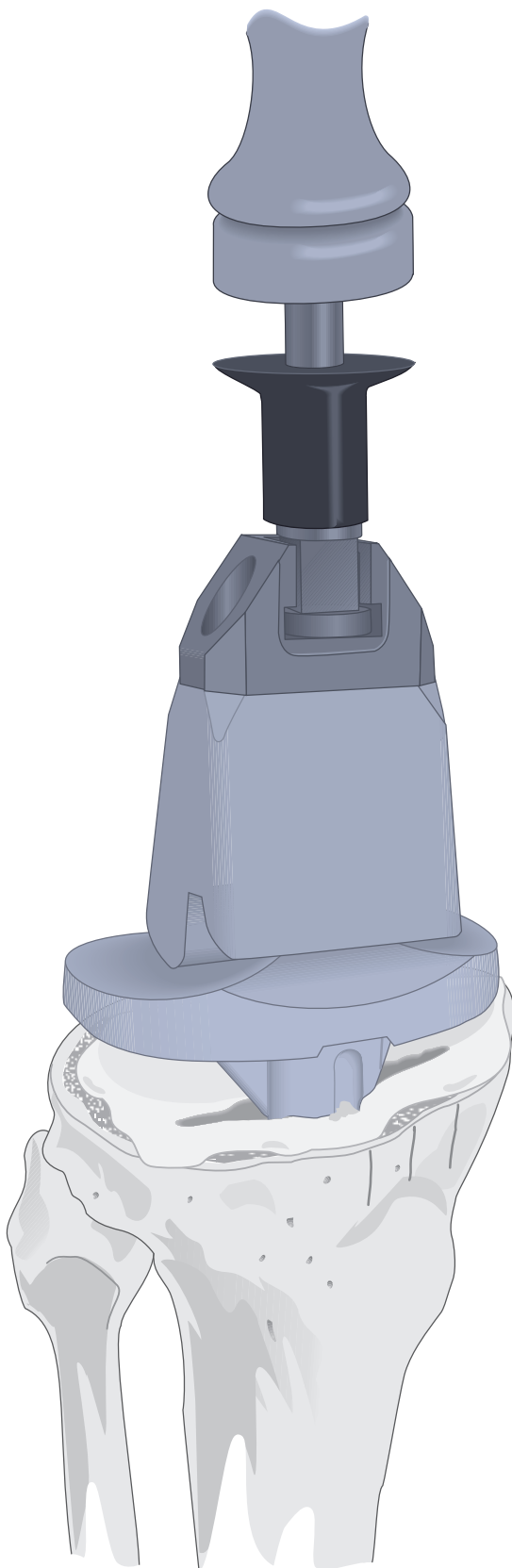
# Implanting the Components

## The Tibial Component

The entire site is thoroughly cleansed with pulsatile lavage. Methyl methacrylate cement is prepared and applied by syringe or digital pressure in its low viscous state to assure maximal penetration into the trabecular bone.

The universal handle is assembled onto the universal tibial tray inserter and assembled onto the tibial tray. The tray is carefully inserted, **avoiding malrotation**. When it is fully seated, several mallet blows are delivered to the top of the universal handle. The nylon tibial tray impactor may be used to further impact the tibial tray.





### **UHMWPE Stabilised Tibial Component**

Alternatively, when implanting an all UHMWPE tibial component, place the component in appropriate orientation and impact the component with the nylon tibial tray impactor. Excess cement is removed from the periphery of the tibial plateau, and a final impaction is performed to ensure complete seating of the component.

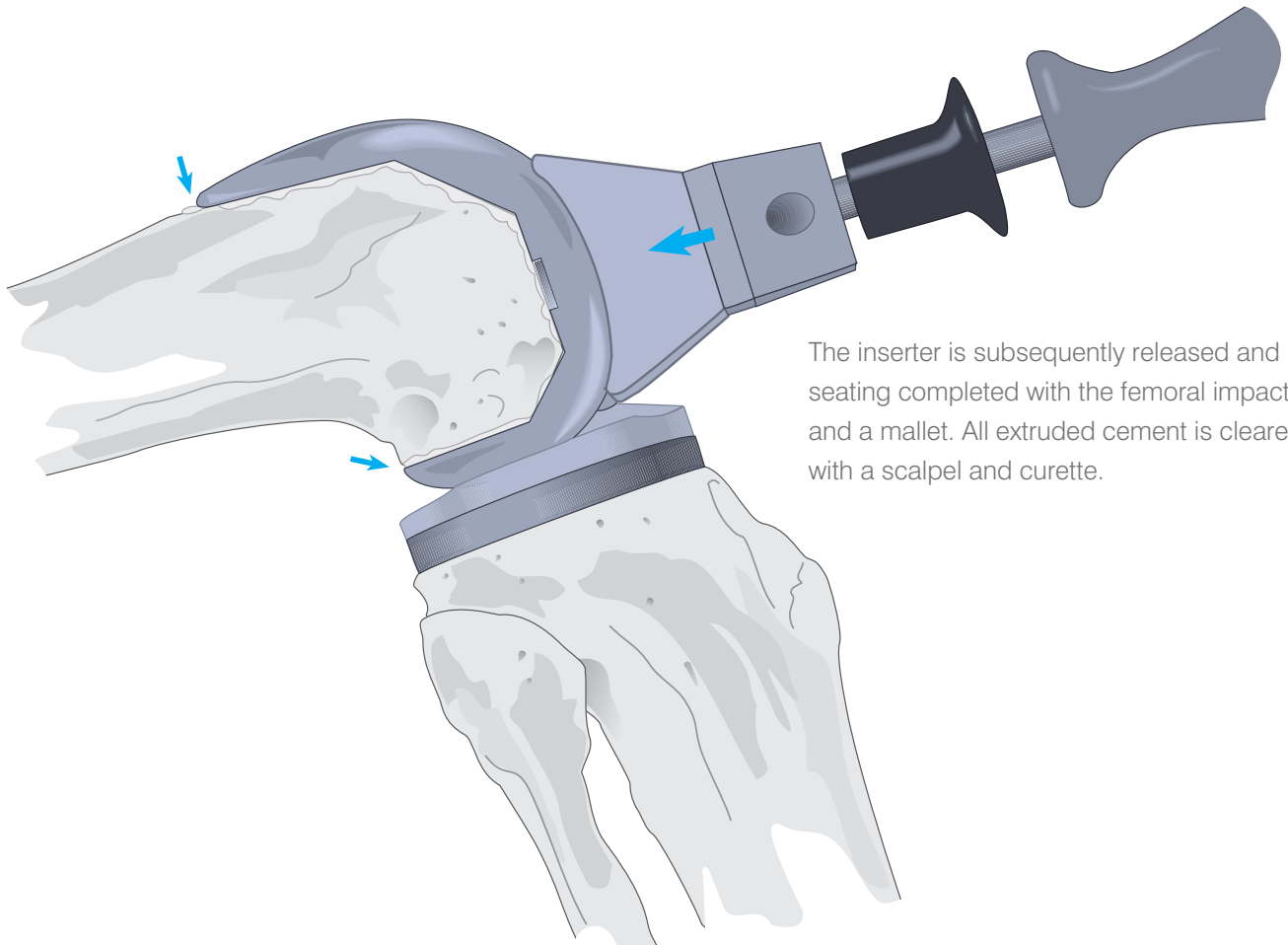
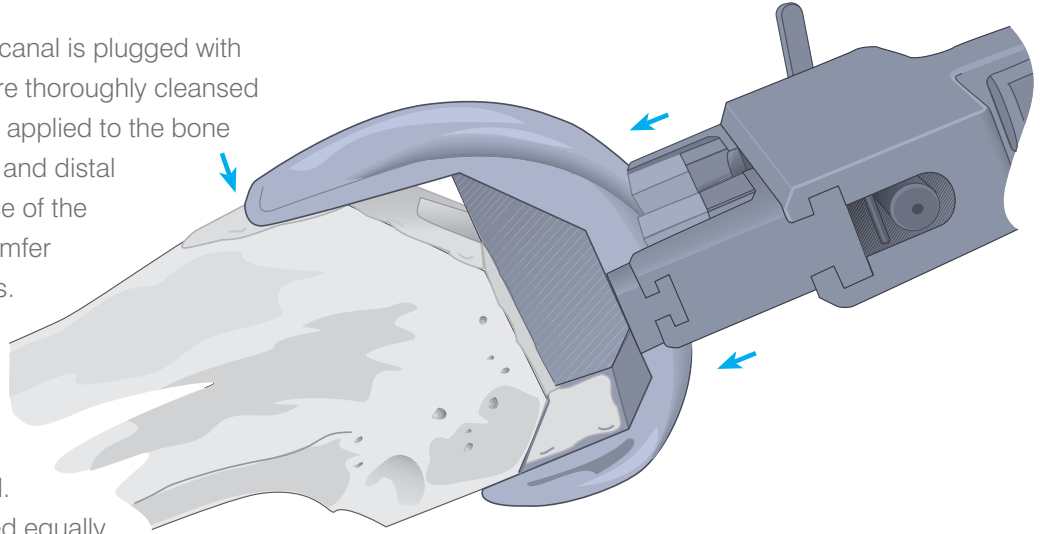
### **Cement Pressurisation**

As the cement polymerises, a trial component is positioned on the prepared femur. The knee is placed in full extension to maintain pressure at the bone/tibial implant interface. Slight valgus stress is maintained to ensure that the tibial implant not tilt into varus. When the cement has set, the knee is placed in flexion and the trial femoral component removed. All extruded cement is carefully removed with special attention to the posterior compartment.



## The Femoral Component

The entry hole at the medullary canal is plugged with cancellous bone. All surfaces are thoroughly cleansed with pulsatile lavage. Cement is applied to the bone at the anterior, anterior chamfer and distal surfaces and to the inner surface of the component at the posterior chamfer and posterior condylar recesses. Care is taken to avoid the articular surface of the implant. The implant is assembled onto the femoral inserter. Care is taken that it is correctly oriented. The leading edges are advanced equally, parallel to the distal surface and protecting the carefully configured surfaces.

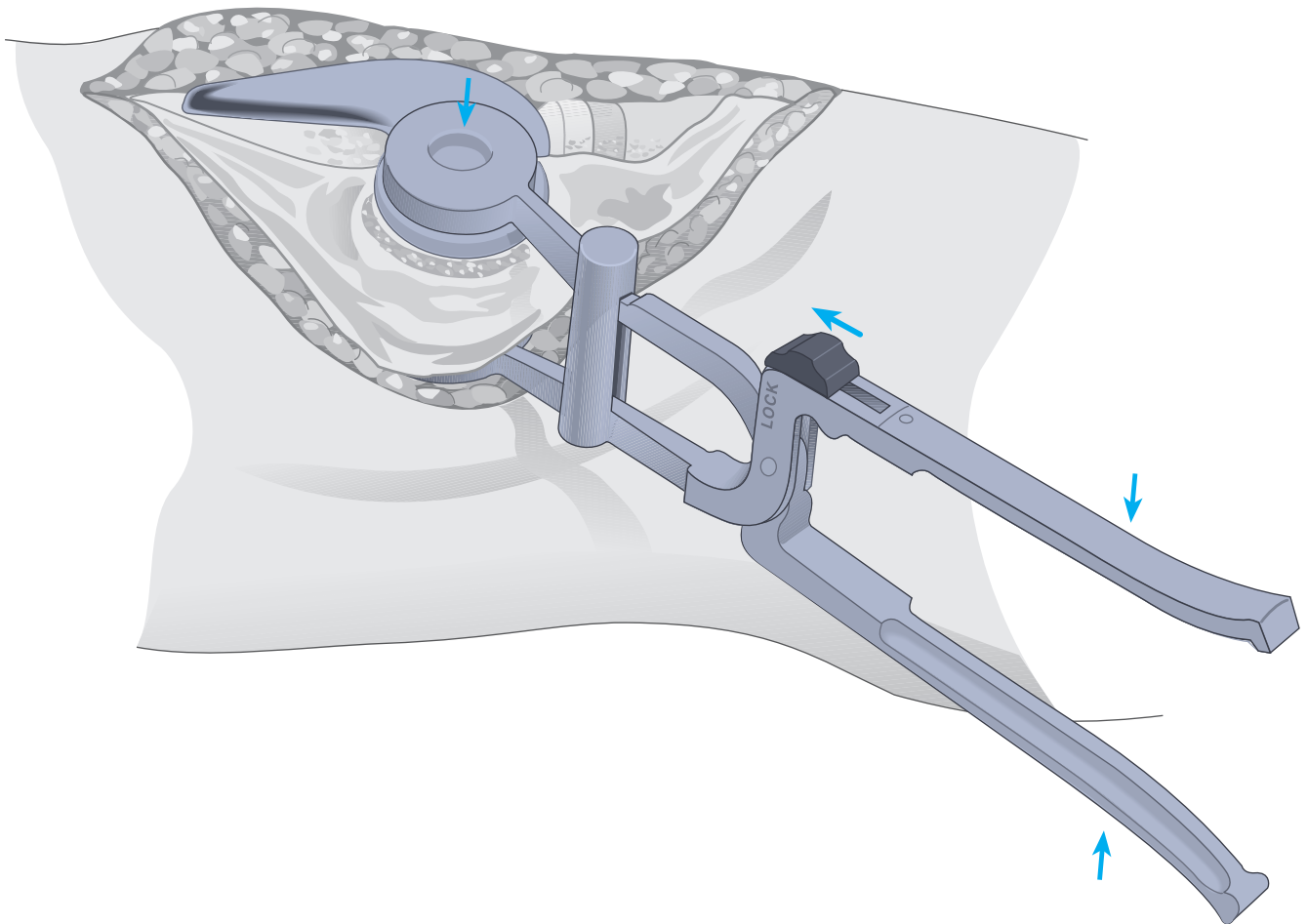


The inserter is subsequently released and seating completed with the femoral impactor and a mallet. All extruded cement is cleared with a scalpel and curette.

## The Patellar Component

The patellar implant may be cemented at the surgeon's convenience with either of the other components. The cut surface is thoroughly cleansed with pulsatile lavage. Cement is applied to the surface and the component inserted.

The patellar clamp is designed to fully seat and stabilise the implant as the cement polymerises. It is positioned with the silicon O-ring centred over the articular surface of the implant and the metal backing plate against the anterior cortex, avoiding skin entrapment. When snug, the handles are closed and held by the ratchet until polymerisation is complete. Excessive compression is avoided as it can fracture osteopenic bone. All extruded cement is removed with a curette. To release the clamp, place the locking knob in the unlocked position and squeeze the handles together to release the pawl.

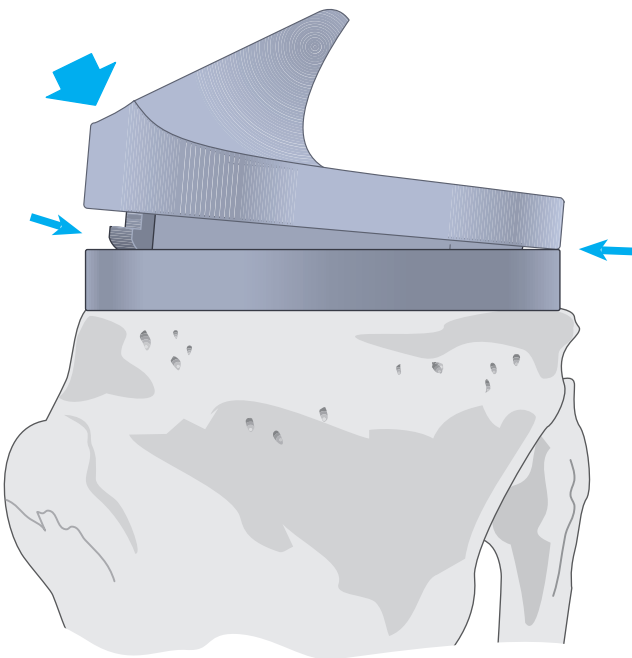
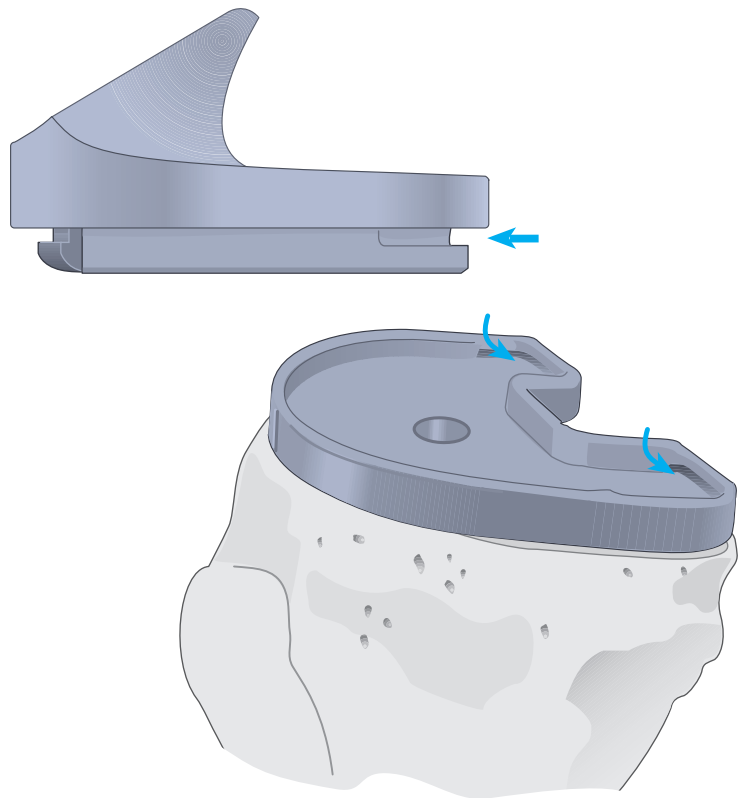


## The Tibial Insert

The trial insert is removed and the permanent insert introduced into the implanted tibial tray and seated posteriorly, its anterior margin resting on the lip.

The anterior margin is tapped with a nylon mallet, deflecting it past the lip of the tray into position. Seating is confirmed by circumferential inspection.

Alternatively, the permanent insert may be inserted at any convenient time during the cementing procedure.



## Closure

The tourniquet is released and bleeding controlled by electrocautery. A closed-wound suction drain is placed in the suprapatellar pouch and brought out through the lateral retinaculum. The fat pad, quadriceps mechanism, patella tendon, and medial retinaculum are reapproximated with interrupted sutures.

The knee is put through a range of motion from full extension to full flexion to confirm patellar tracking and the integrity of the capsular closing. The final flexion against gravity is noted for postoperative rehabilitation.

Subcutaneous tissue is reapproximated and the skin closed with sutures or staples.

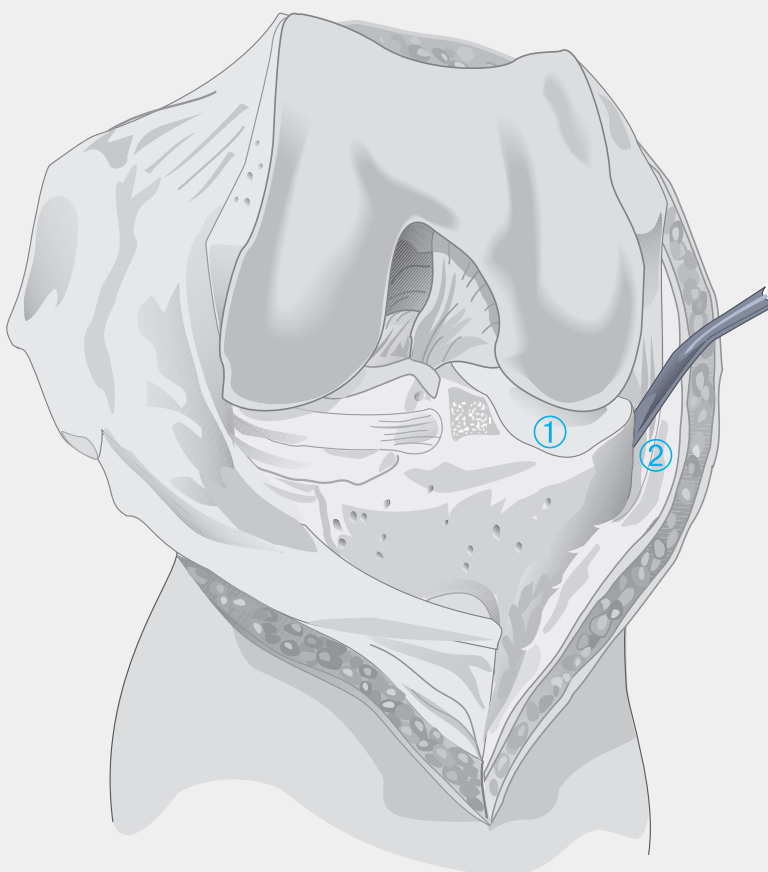
# Ligamentous Balance in Total Knee Arthroplasty

The suggested sequence of ligamentous release to correct varus or valgus deformity and quadriceps-mechanism imbalance is described. There is no general agreement on the order, but there is on the principles:

- Preliminary soft-tissue release is performed at the start of surgery, based upon preoperative evaluation.
- Balance is established by eliminating soft-tissue contractures, not by modifying the bone cuts.
- Final correction is established at trial reduction

## Medial Ligamentous Release for Fixed Varus Deformity

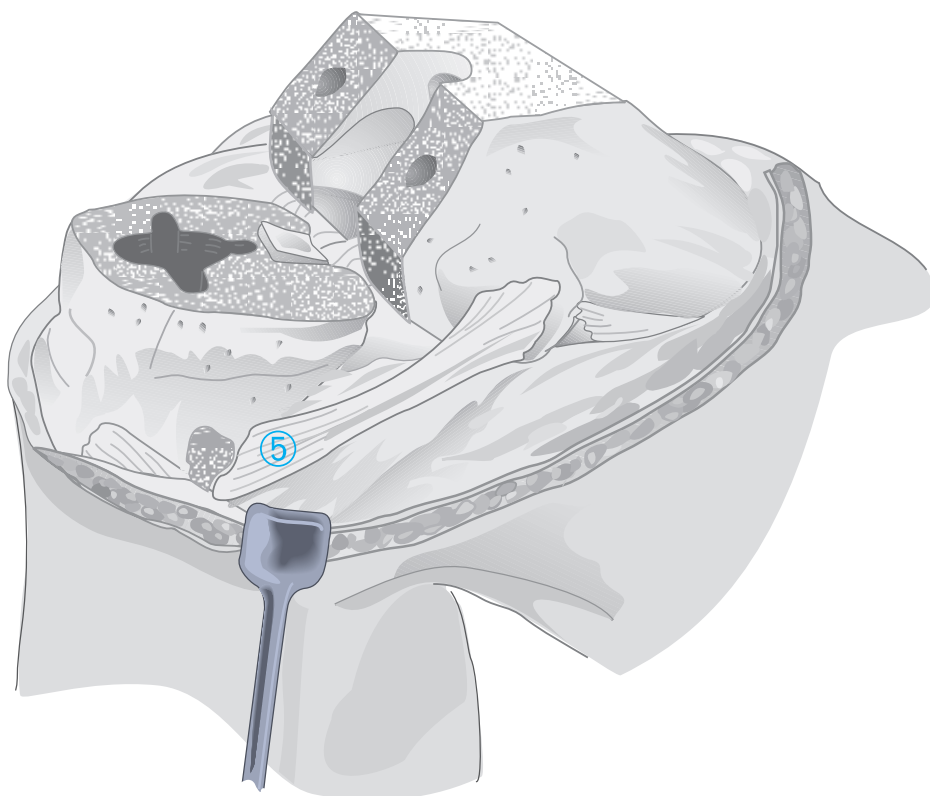
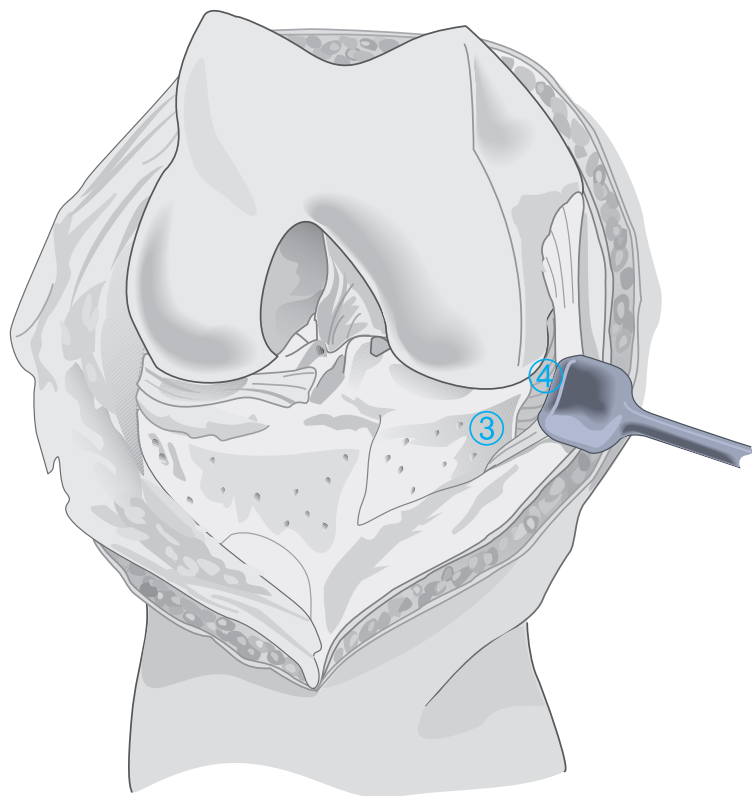
Following removal of peripheral osteophytes, the medial meniscus (1) and the meniscotibial ligament (2) are excised. In rheumatoid arthritis and minimal deformity, this is often sufficient.



Where further release is indicated, the posterior expansion of the deep medial collateral ligament is released from its tibial attachment (3) using a curved osteotome.

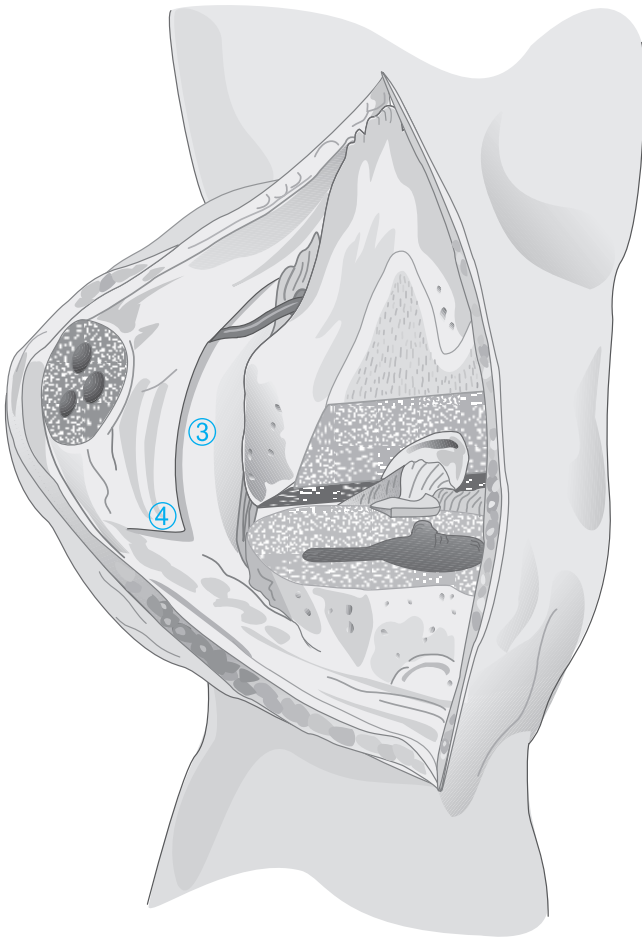
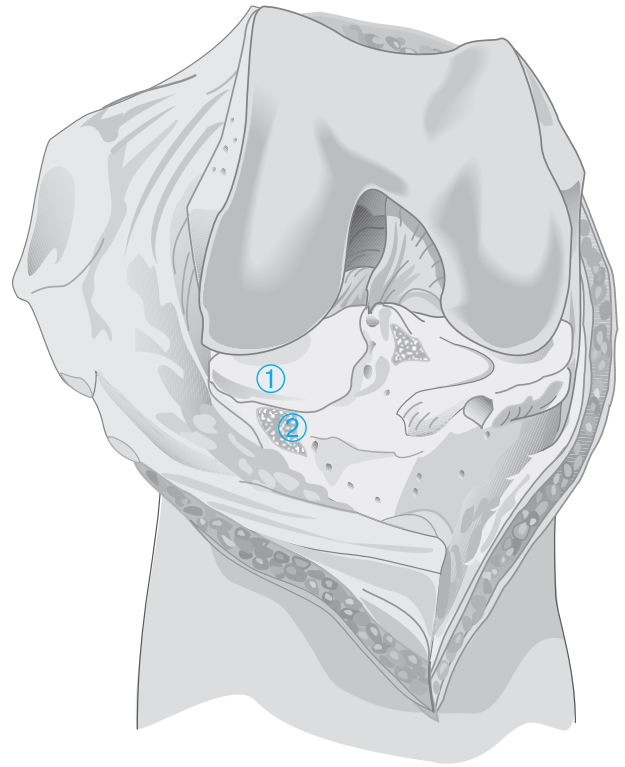
Where still further release is indicated the medial tibia is denuded subperiosteally (4).

Where, following trial reduction, further release is indicated, the superficial portion of the medial collateral ligament is released from its tibial attachment (5). Generally, this is indicated only in severe deformity associated with significant flexion contracture.



# Lateral Ligamentous Release for Fixed Valgus Deformity

Following removal of peripheral osteophytes, initial release comprises medial meniscectomy (1) the release of the iliotibial band from its tibial insertion (2). A lateral quadriceps retinacular release is indicated where there is poor patellar tracking at trial reduction.



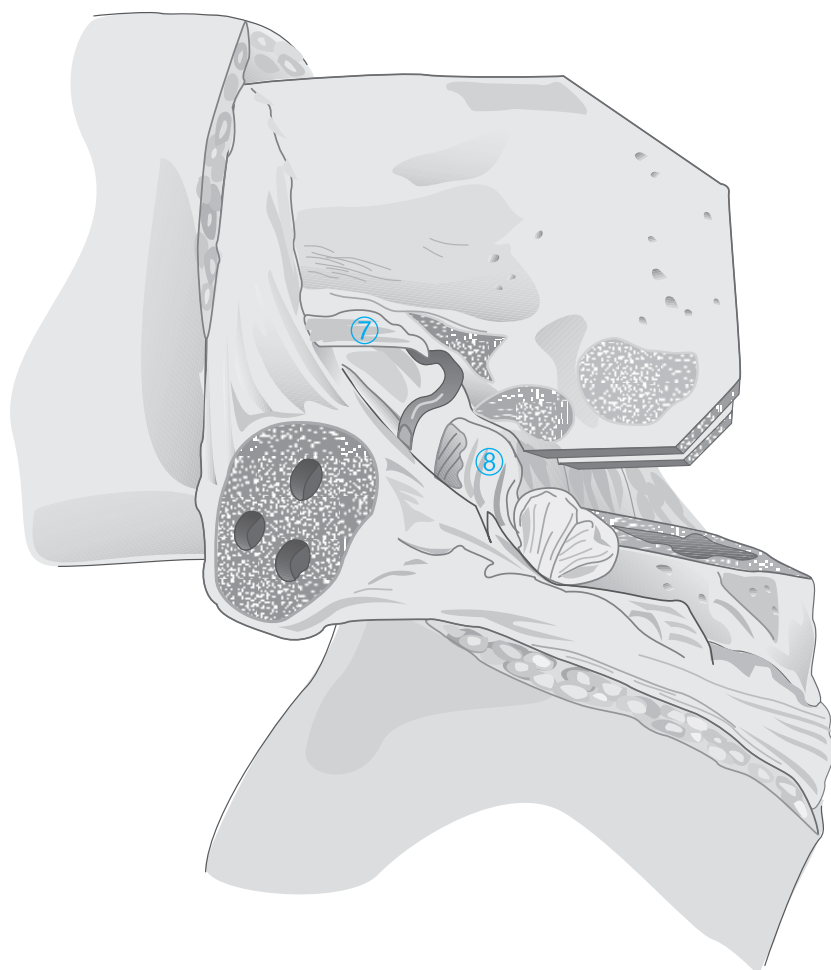
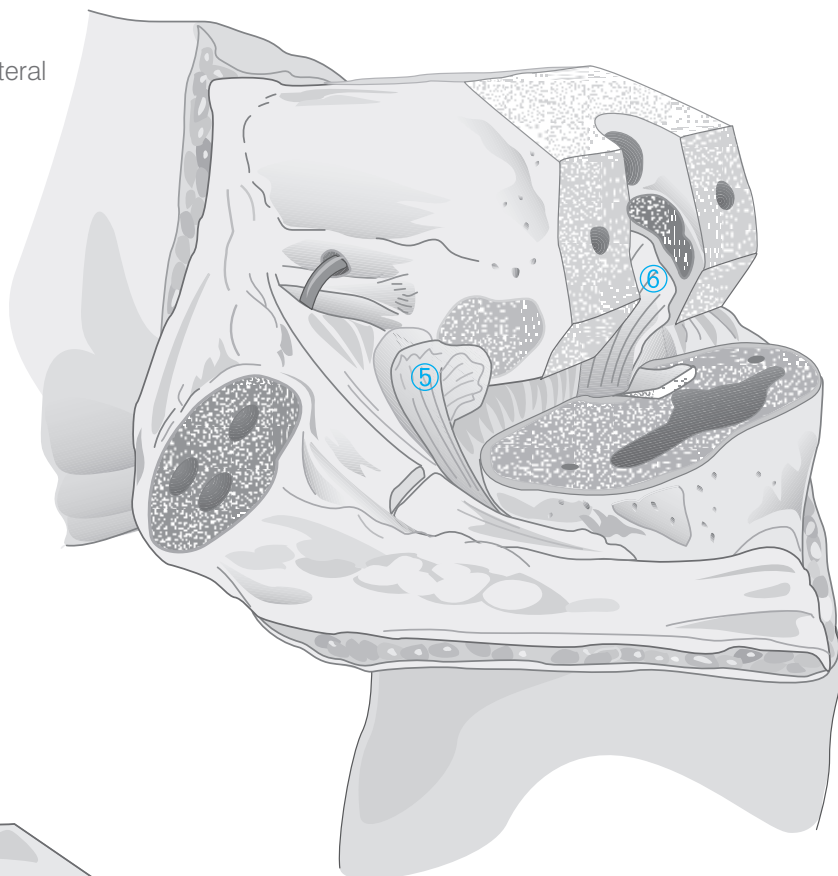
Lateral retinacular release is performed on the internal surface in the longitudinal plane. Care is taken that the lateral superior genicular artery is protected; it is isolated at the intermuscular septum as it penetrates the retinaculum superficially, retracted proximally as the retinacular incision is carried to the level of the joint-line, distally as the incision is extended superiorly to the intermuscular septum (3).

Where indicated, further release is effected by extending the distal terminus of the incision transversely to the lateral margin of the patellar tendon (4) and posteriorly to the lateral collateral ligament.

Where still further release is indicated, the lateral collateral ligament and popliteus tendon are released from the femoral epicondyle and allowed to slide posteriorly (5).

Where further release is indicated, the posterior cruciate ligament is evaluated and, where necessary, sacrificed (6).

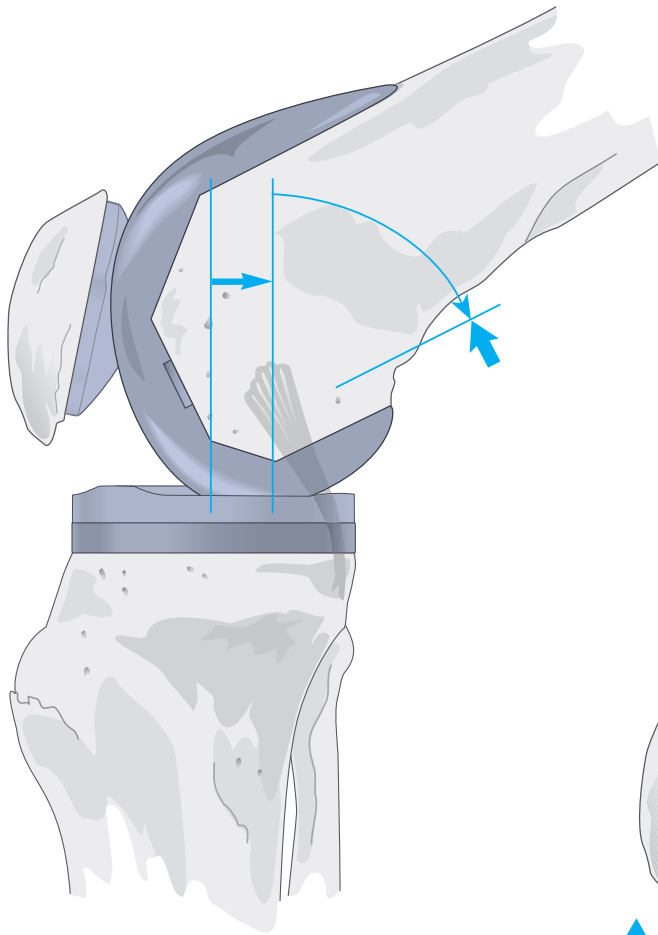
**Note: Priority of steps 5 and 6 is a matter of preference.**



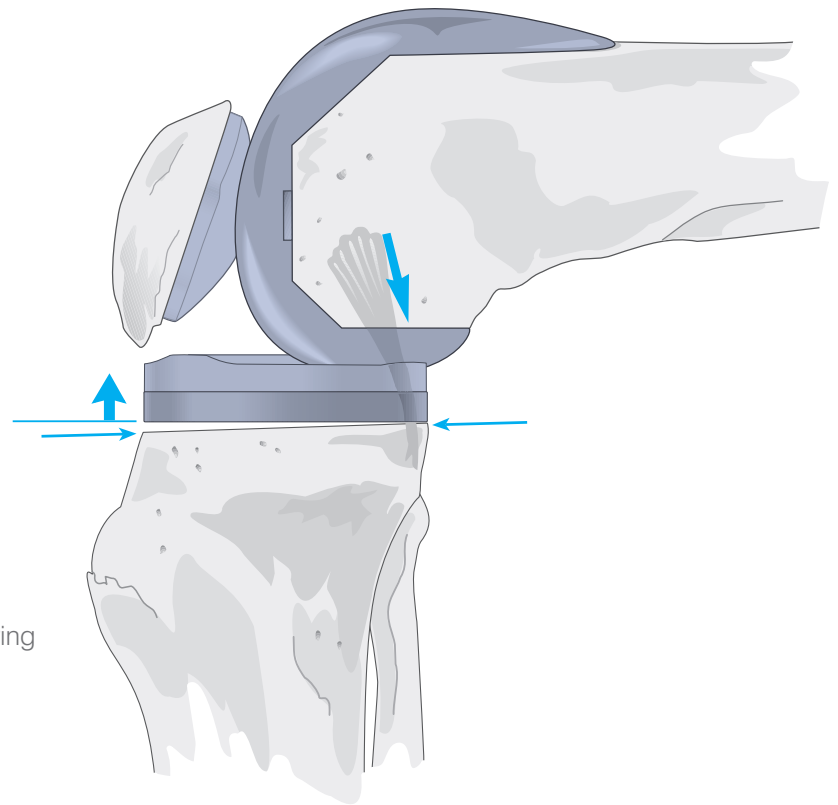
Where balance requires still further release, dissection is extended posteriorly, freeing the intermuscular septum (7) and the lateral head of the gastrocnemius (8).

Care is taken that the posterolateral neurovascular structures be preserved and that the insertion of the biceps femoris, which overlies the common peroneal nerve, remain intact.

# Balancing the Posterior Cruciate Ligament



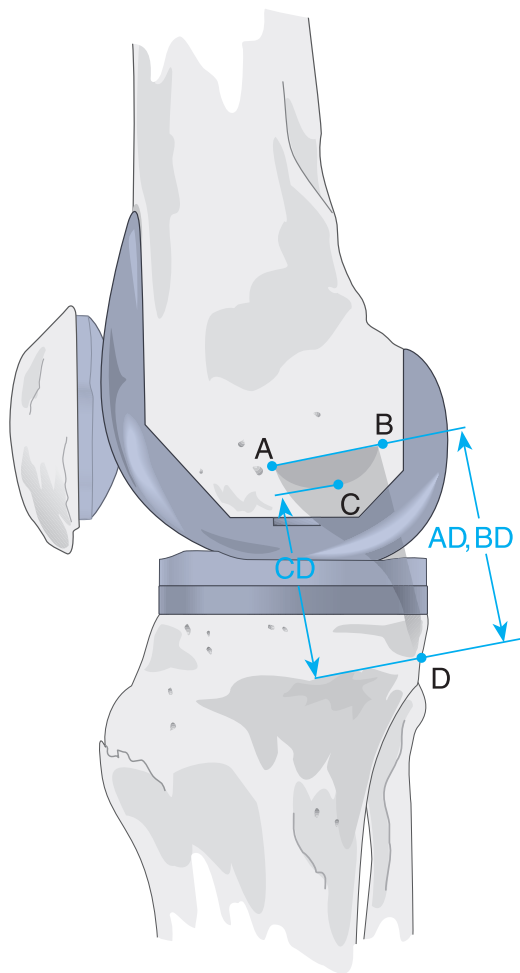
In cruciate-retaining total-knee replacement, there are three indicators for PCL tightness identified at trial reduction: limited flexion with excessive femoral rollback, anterior lift-off of the tibial tray and palpable ligamentous tension in flexion.



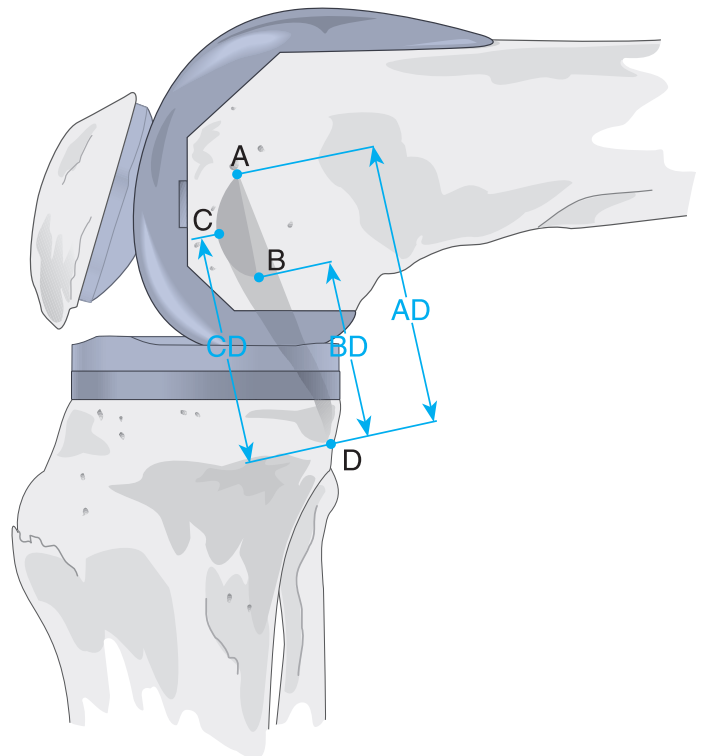
Possible causes include residual posterior/posteromedial osteophytes and loose bodies such as meniscal segments. It is essential during initial exposure that all peripheral posterior osteophytes be cleared, that the menisci be completely removed and that the attachments of the PCL be defined.

Problems commonly arise from failure to clear the posterior horns of the menisci, including the posterior menisiofemoral ligament, and failure to identify synovial adhesions.





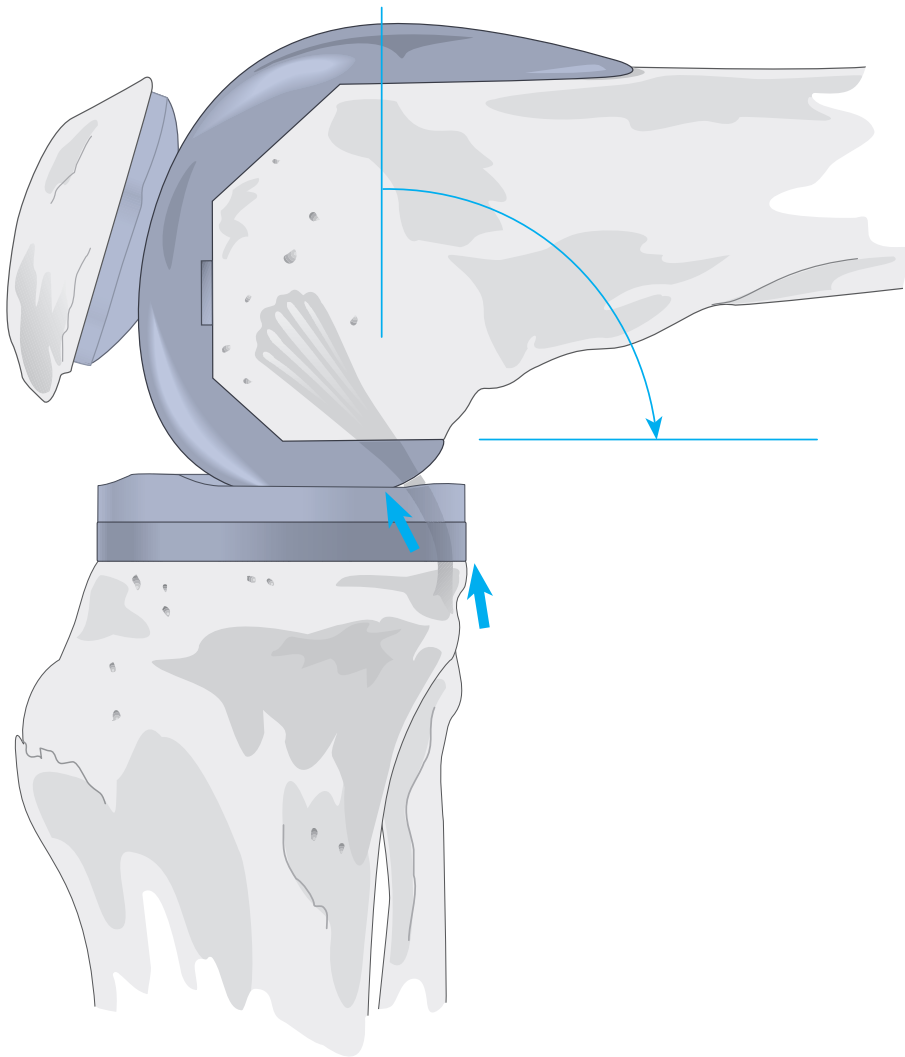
Where the surgeon elects to increase the posterior slope, it should not exceed a total of  $7^\circ$ , as excessive posterior slope will complicate ligamentous balance in flexion and extension. It is preferable, therefore, that the PCL be recessed.



PCL recession is possible at either the tibial or femoral attachments, but as the anterior and posterior fibres at the femoral attachment differ in tension in transition from extension to flexion and as compromising this attachment increases the likelihood of evulsion, preliminary recession at the tibial attachment is recommended.

The diagram above shows the changes in PCL tension throughout range of motion.

In extension, the bulk of the PCL is relaxed and only the posterior band is tight. In flexion, the bulk of the PCL becomes tight and the small posterior band is loose.



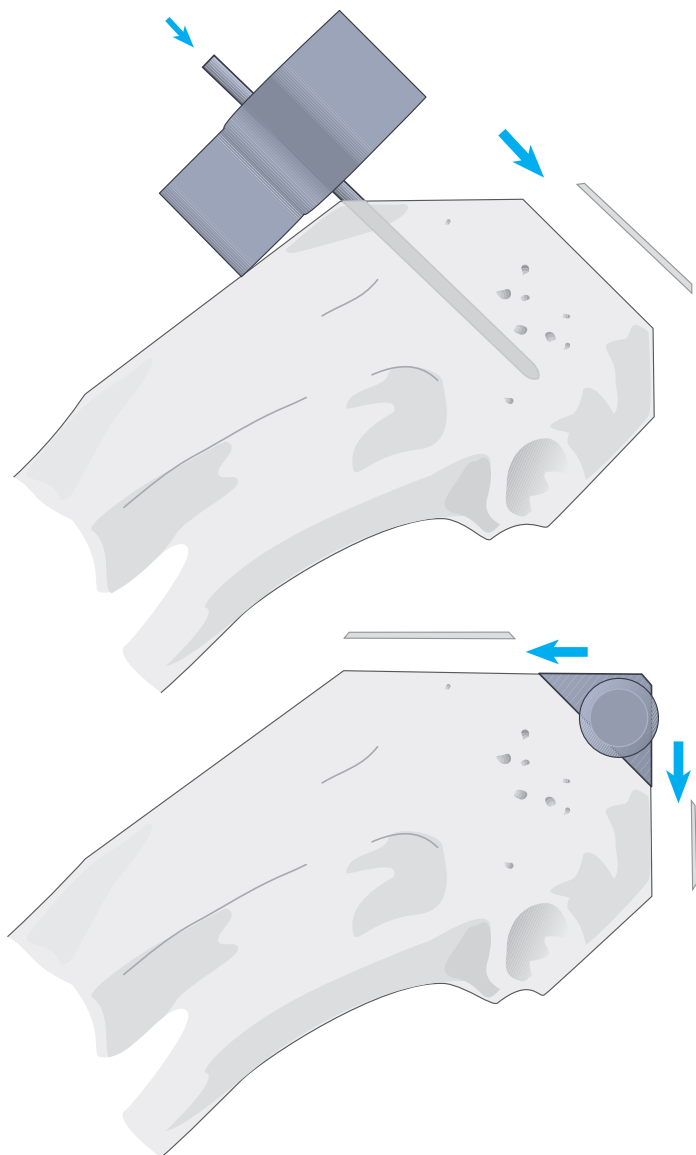
The tibial attachment is elevated subperiosteally along the entire proximal margin such that the ligament is allowed to recede incrementally until flexion tension in trial reduction is satisfactory with normal patellar tracking.

Where tightness persists, further release is indicated, which may be preformed at the femoral attachment. This can produce laxity; to lessen the likelihood, a supplemental curved component is introduced. The knee is placed in 90° of flexion and the tensed fibres incrementally freed from the femoral attachment with sharp dissection until the supplemental component is accepted without anterior lift-off of the tray.

**Note: Residual posterior osteophytes or undetected bone fragments can impinge upon the component and promote lift-off.**

# Balancing Flexion and Extension Gaps

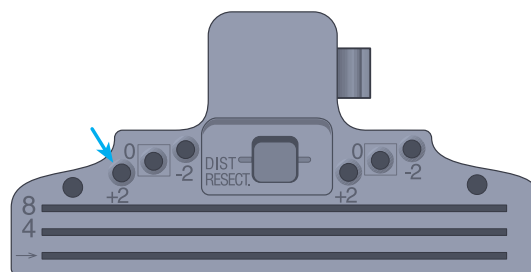
Where the joint line is maintained, flexion and extension gaps are usually found to be balanced at trial reduction, but where there is pre-operative deformity and contracture, imbalance may be present.



## Residual Flexion Contracture

Where there is restriction in extension but not in flexion, additional bone is removed from the distal femur. This affects the extension gap but not the flexion gap. Where contracture persists following appropriate retinacular release and removal of posterior osteophytes and scar tissue, depending on severity, removal of an additional 2-4 mm of distal femur is indicated.

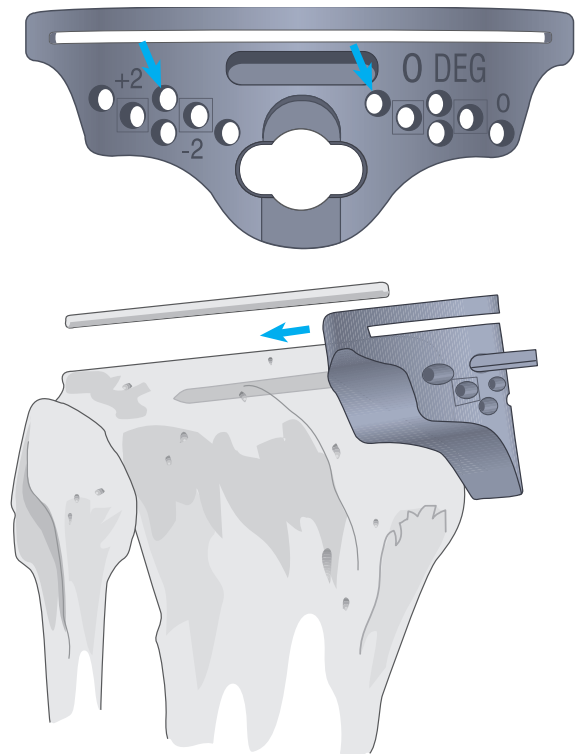
The Steinmann pins are returned to their original position in the anterior femur and the distal femoral cutting block returned to the pins using the holes designated +2 as the degree of contractor indicates. The distal cut is accordingly revised.



Chamfers are subsequently revised to maintain the correct configuration; anterior and posterior cuts are not. This affects ligamentous tension in extension but not in flexion.

### Residual Tightness in Flexion and Extension

A thinner tibial insert or additional tibial resection is indicated, as either will affect flexion and extension gaps. Where resection is selected, it is recommended that 2 mm of proximal tibia be removed. The Steinmann pins are returned to their drill holes in the anterior tibial cortex and the cutting block repositioned on the pins, using the holes designated +2. The cut is accordingly revised.

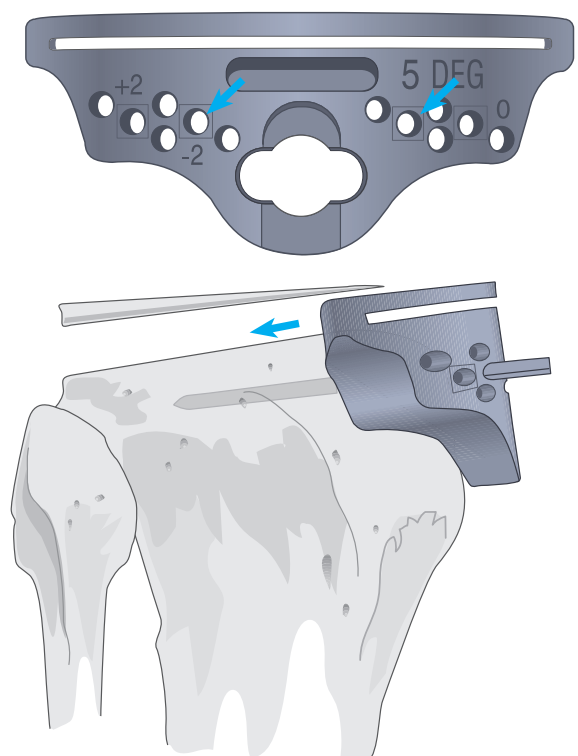


### Residual Tightness in Flexion Only

Where this is the case, PCL recession is indicated to relieve excessive PCL tension. Recession is effected as described above. Residual posterior osteophytes, soft tissue, and loose bodies may be factors and must be addressed. In the rare cases where tension persists following appropriate correction, 5° of additional posterior slope may be indicated. The pins are returned to the anterior cortex and the 5° cutting block positioned using the holes designated □. Final slope should not exceed 7°.

Alternatively, tightness in flexion may be addressed by downsizing the femoral component, provided anterior femoral notching is avoided. The pins are returned to the distal femoral surface, the designated cutting block positioned, and the cuts revised. As an additional posterior condyle is resected, flexion gap is increased.

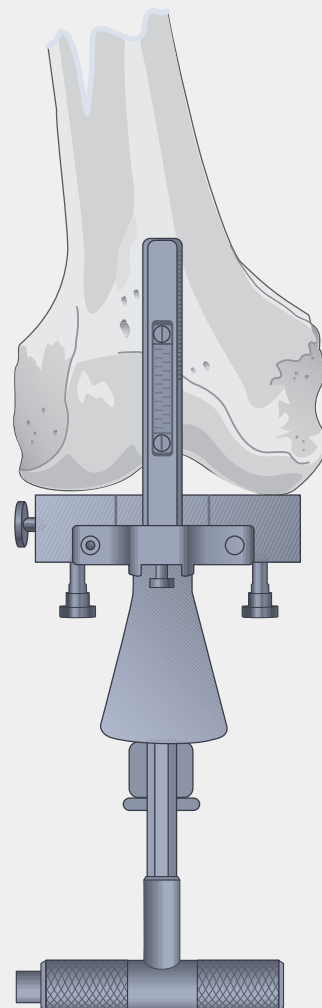
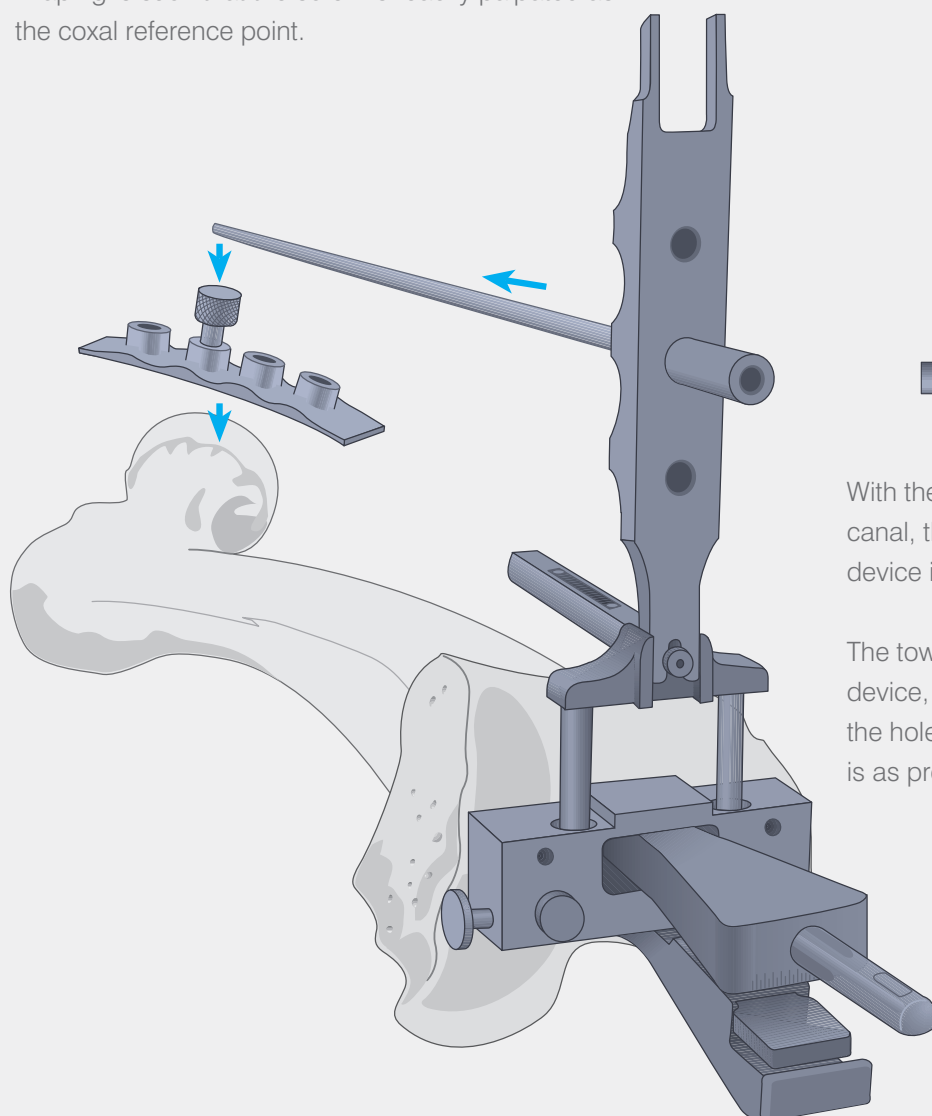
**Note: For discussion of soft-tissue balancing, see above.**



# The External Femoral Alignment System

In patients with femoral deformity or with total hip replacement, the intramedullary alignment system is not appropriate. The short intramedullary rod coupled to the femoral locating device (set at 0°), tower and alignment rod are employed. The femoral head is identified preoperatively, radiopaque markers positioned parallel and just distal to the inguinal ligament. An A/P radiograph identifies the marker which approximates the centre of the hip.

At surgery, the femoral head locating device is taped over the radiopaque markers, the large-headed screw introduced into the hole over the intensified marker. Draping is such that the screw is readily palpated as the coxal reference point.



With the rod repositioned in the medullary canal, the handle is removed and the locating device is placed over the rod.

The tower is assembled to the locating device, the alignment rod introduced through the hole and advanced to the hip. Resection is as previously described.

# Intramedullary Alignment Device

### Preoperative planning

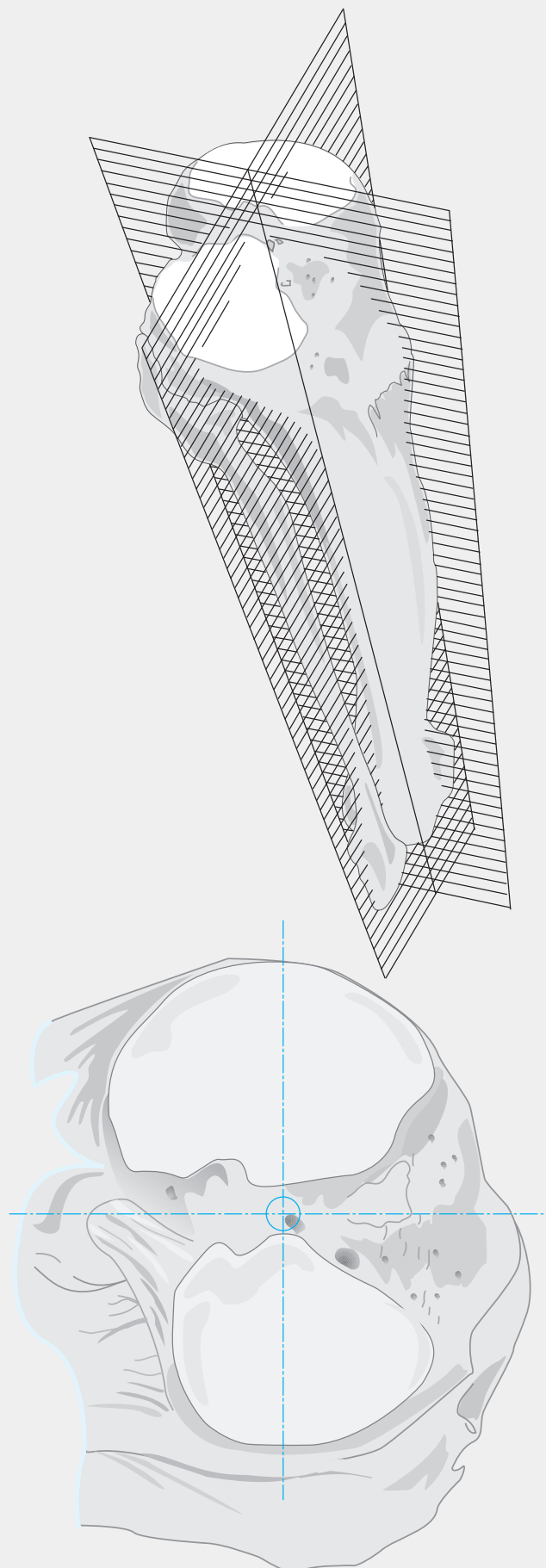
Where the Specialist® 2 Intramedullary Tibial Alignment System is to be used, it is essential that the appropriate point of entry on the tibial plateau be accurately determined. In most cases, this point will be centred on the tibial spine in both the medial/lateral and anterior/posterior aspect. In some cases, it may be slightly eccentric.

Using full-length extremity radiographs, lines are constructed along the central axis of the tibia on the A/P view by determining mid-points of the diameter of the tibia in the diaphysis at least 10cm apart. A line defined by these two points is extended proximally to the knee joint and distally to the ankle joint. The point of intersection with the tibial plateau determines the point of entry in the medial lateral plane. This line should pass at or near the centre of the ankle joint. If it does not, it is usually because of excessive tibial bowing. In this circumstance, it is preferable to use an external tibial alignment system.

In the lateral view a point is defined at the mid-point of the tibial plateau and another point defined at the mid-point of the isthmus. The line defined by these two points will define the appropriate placement of the intramedullary tibial alignment rod in the lateral plane.

These lines are projected to the tibial plateau; their intersection determines the appropriate point of entry.

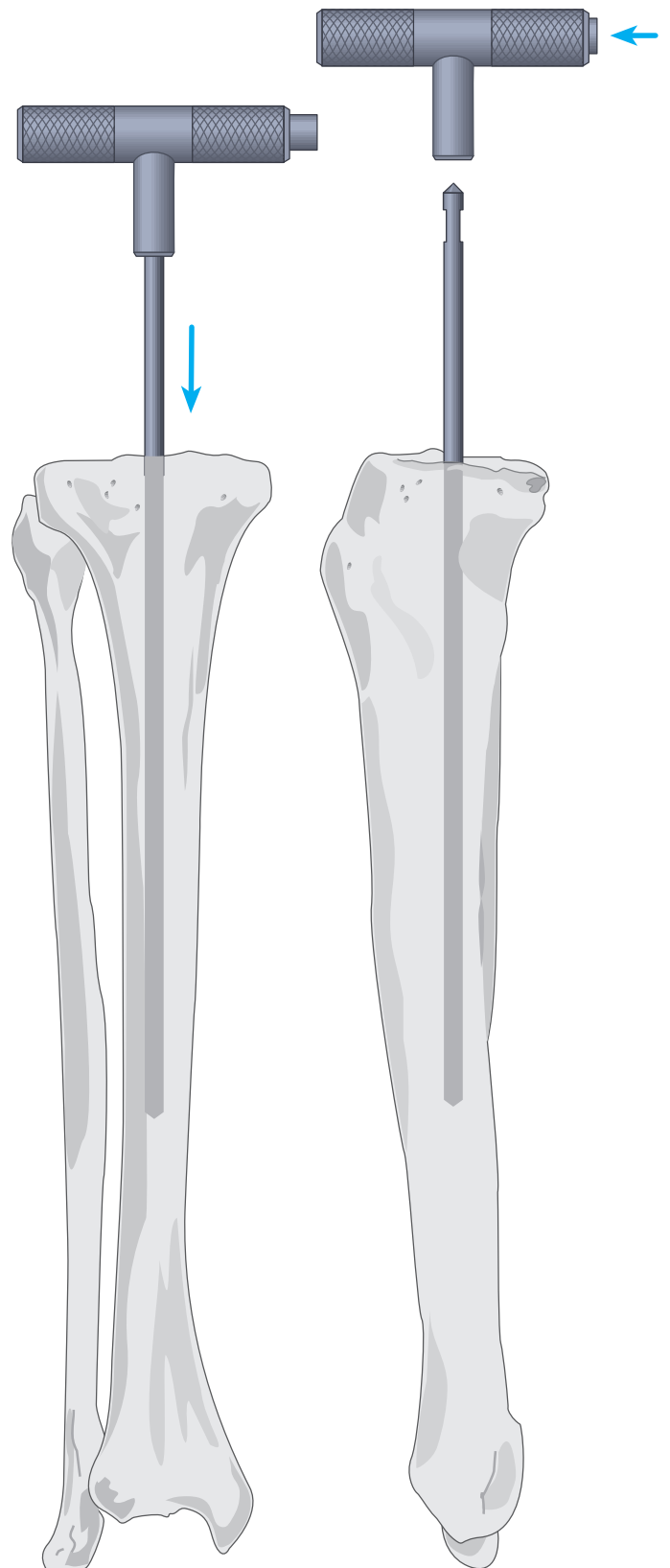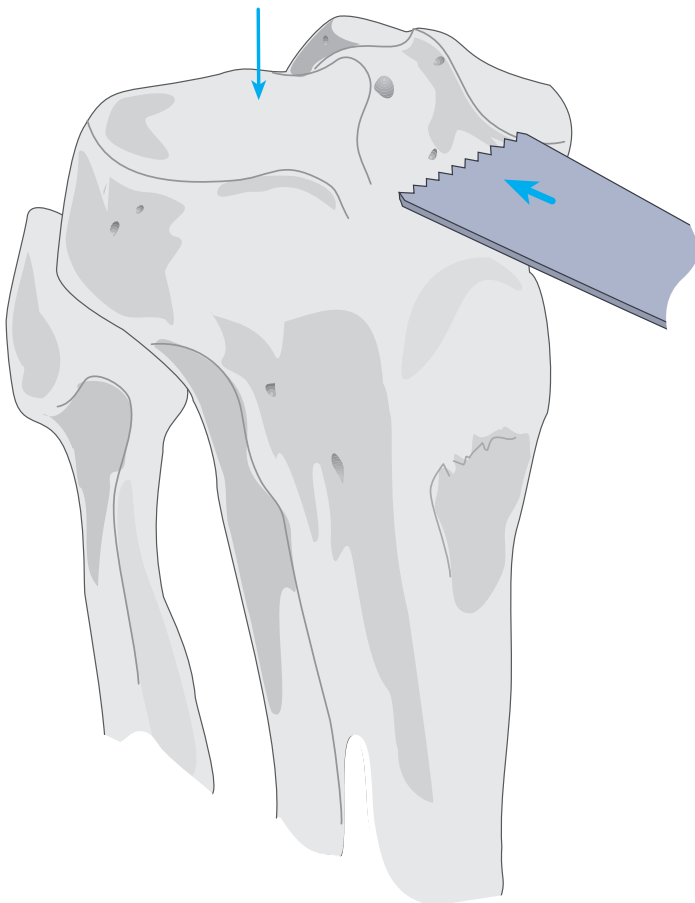
**Note: The entry point for the intramedullary alignment rod is a critical starting point for accurate alignment of the intramedullary alignment system. Selected correctly neutral alignment in the antero posterior and lateral planes is easily achieved.**



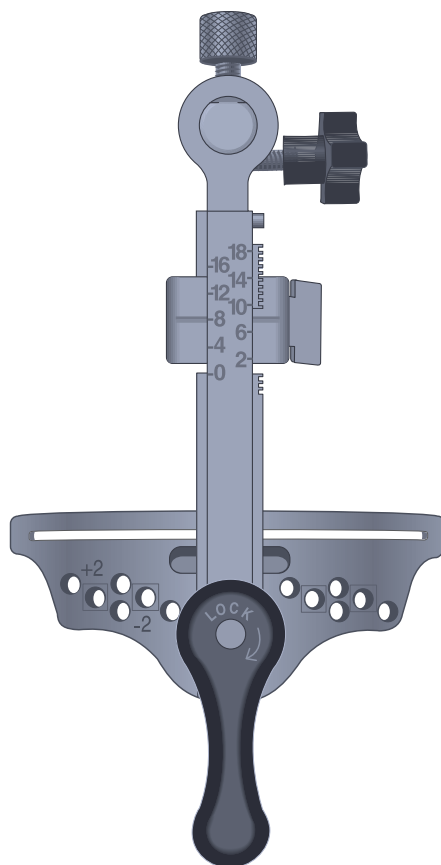
# Entering the Medullary Canal

The knee is flexed maximally, the tibial retractor inserted over the posterior cruciate ligament and the tibia subluxed anteriorly. All soft tissue is cleared from the intercondylar area. The tibial spine is resected to the highest level of the least affected tibial condyle. Entrance to the medullary canal is facilitated with a  $\frac{5}{16}$ " step drill bit which makes a pilot hole to assure accuracy.

The intramedullary rod is passed down into the medullary canal until the isthmus is firmly engaged.



# The I.M. Tibial Alignment Guide



## Assembling the Guide

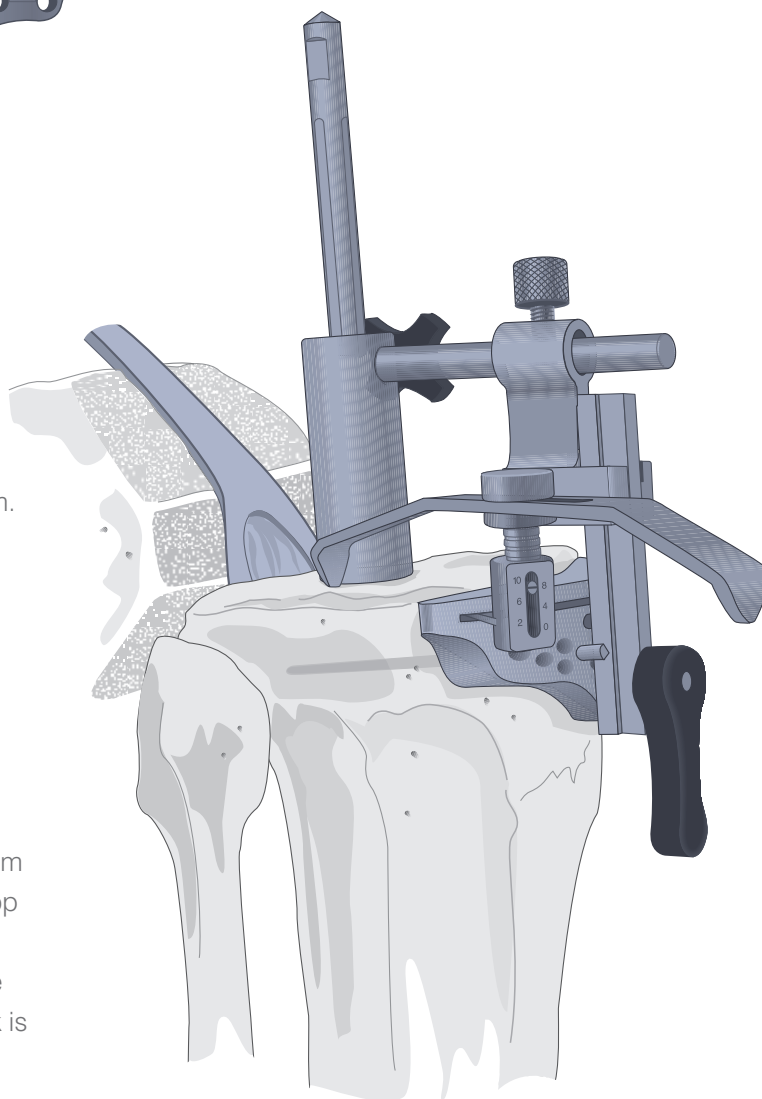
As a posterior slope is usually desired, a 3° or 5° posteriorly sloped cutting block is selected.

## Positioning the Guide

The handle is removed and the I.M. tibial alignment guide is positioned on the I.M.rod. The I.M. guide should sit flush to the resected tibial spine.

It is suggested the level of resection be set at 8 or 10 mm. This is accomplished with the use of the stylus, set at the appropriate resection level (see footnote), positioned in the centre of the condyle of the least affected side.

Alternatively, to use the reference scale on the front of the outrigger to measure the resection level, the scale as indicated is relative to cutting through the slot. To adjust for cutting on the surface of the block, add 4 mm to the front scale. For example, when cutting on the top of the slotted block and an 8 mm resection is desired, set the outrigger for 12 mm and proceed to cut on the surface of the block. Note, the top of the cutting block is engraved 4 mm offset.



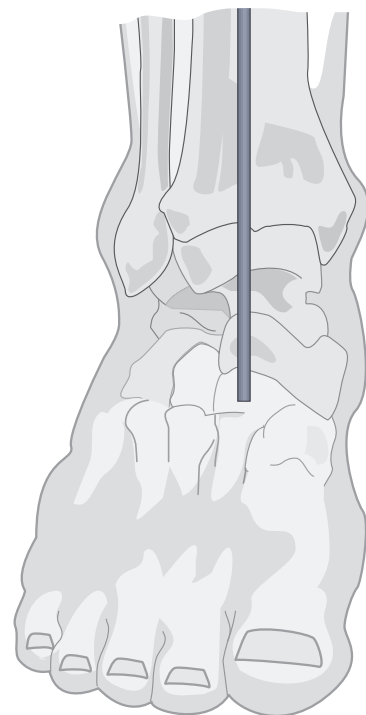
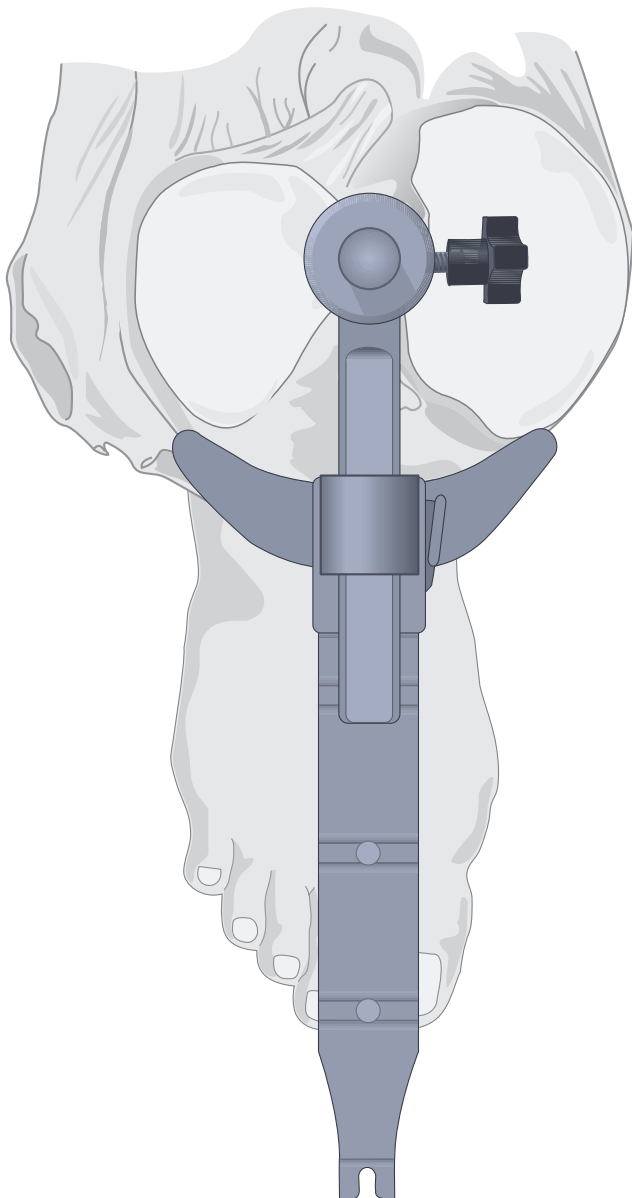
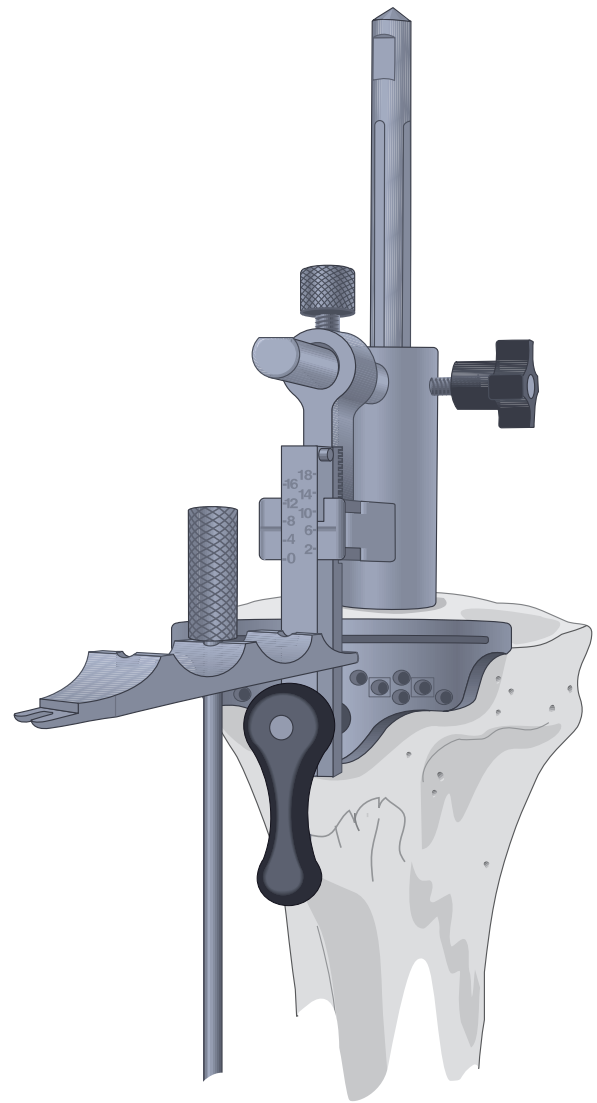
**Note:** For full explanation of the stylus, refer to page 25 of this manual.



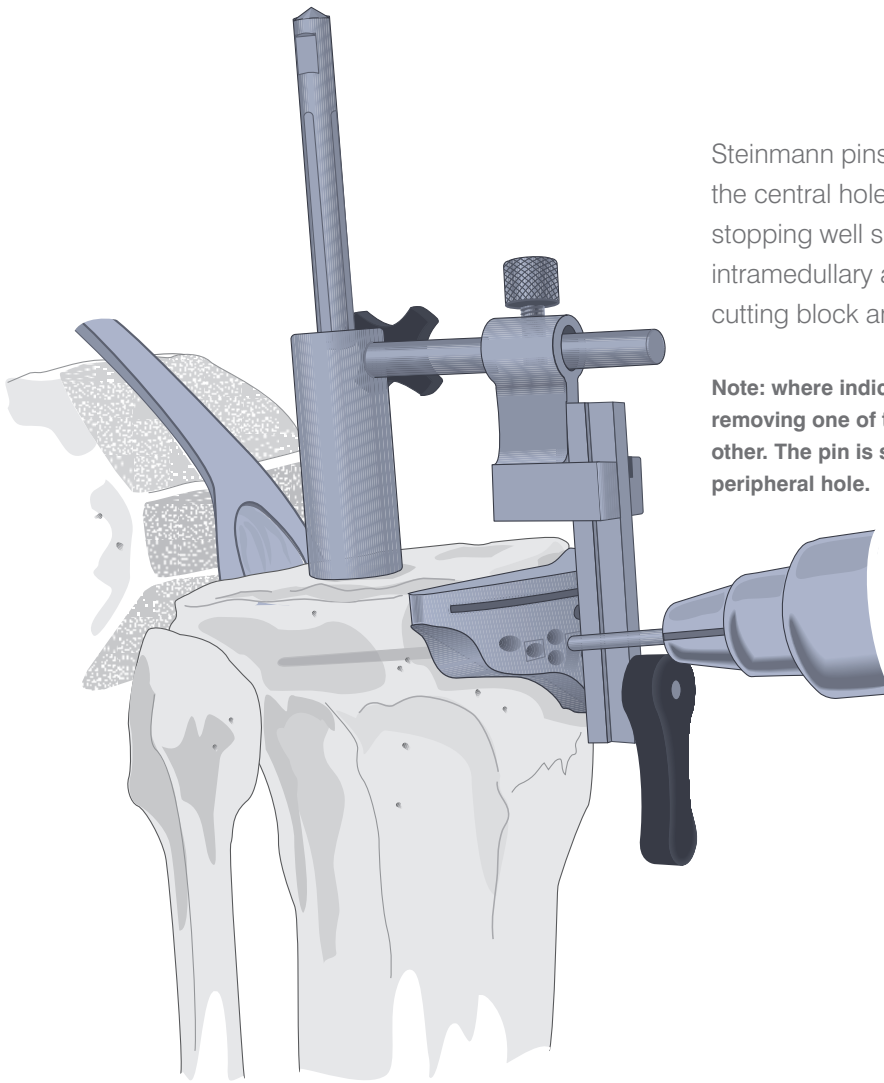
# Rotational Alignment

When the level of resection has been determined, the alignment tower, tibial side, is inserted into the tibial cutting block and rotated such that the centre of the block is aligned with the medial third of the tibial tubercle.

The long alignment rod is passed through the appropriate hole to the ankle. It should align with the centre of the talus. Lateral alignment is similarly confirmed.



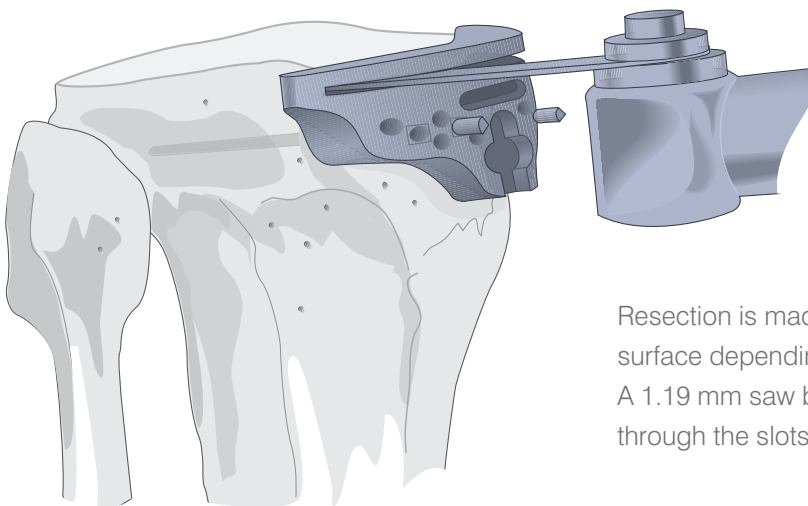
# Securing the Cutting Block



Steinmann pins or  $\frac{1}{8}$ " drill bits are introduced through the central holes, marked with a  , into the tibia stopping well short of the posterior cortex. The intramedullary alignment device is removed from the cutting block and the I.M. rod is subsequently removed.

**Note:** where indicated, varus/valgus corrections are made by removing one of the pins and allowing the block to pivot on the other. The pin is subsequently repositioned through a more peripheral hole.

## Tibial Resection



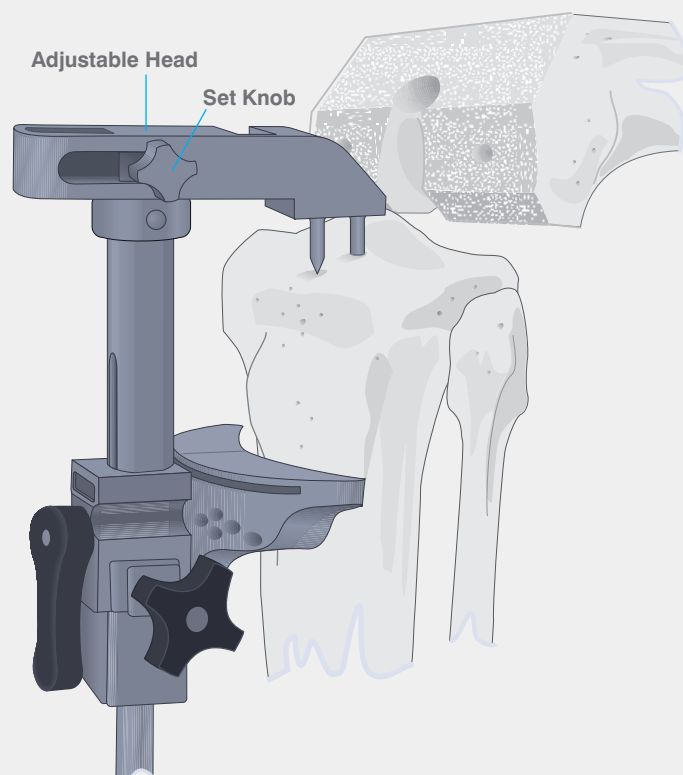
An entry slot is cut with a narrow oscillating saw into the intercondylar eminence anterior to the attachment of the PCL and an osteotome positioned to shield the ligament.

Resection is made either through the slot or on the top surface depending upon the stylus reference used. A 1.19 mm saw blade is recommended when cutting through the slots.

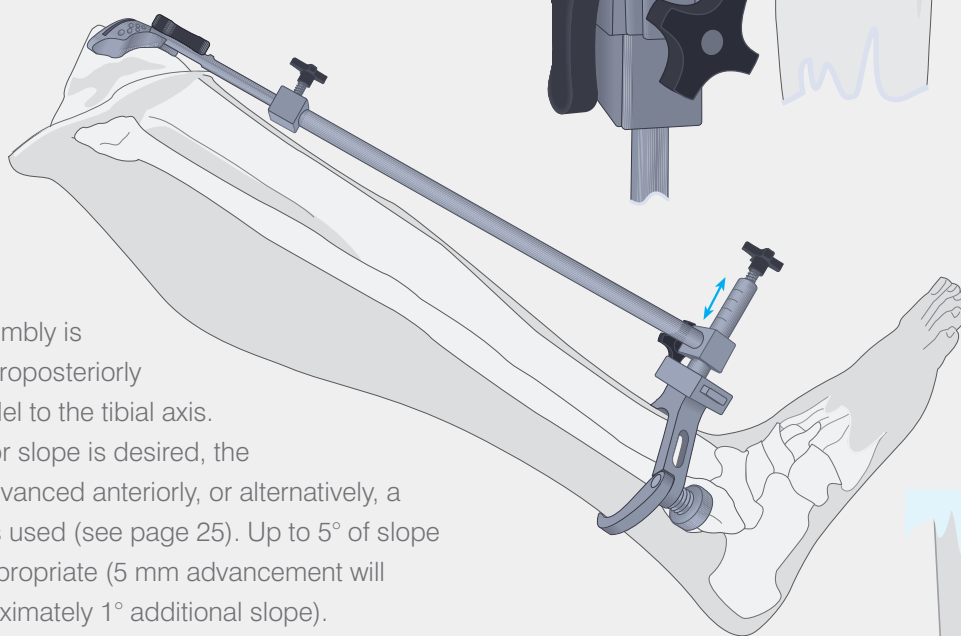
## APPENDIX IV

# Extramedullary Tibial Alignment Device with Proximal Fixation Spike

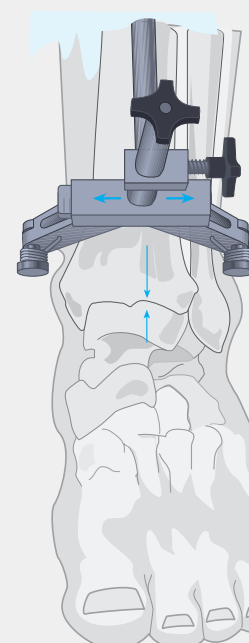
The knee is placed in maximum flexion with the tibia distracted anteriorly and stabilised. The malleolar clamp of the tibial alignment device is positioned proximal to the malleoli. With the appropriate transverse tibial cutting guide attached to the tibial alignment device, the proximal spike is placed in the centre of the tibial eminence and seated to the depth of the shortest or anterior, spike. The cutting block is advanced posteriorly to the proximal tibia and the head containing the spikes is tightened.



The lower assembly is translated anteroposteriorly to align it parallel to the tibial axis. Where posterior slope is desired, the assembly is advanced anteriorly, or alternatively, a sloped block is used (see page 25). Up to 5° of slope is generally appropriate (5 mm advancement will produce approximately 1° additional slope). There are scribes marks at 1 cm for reference.

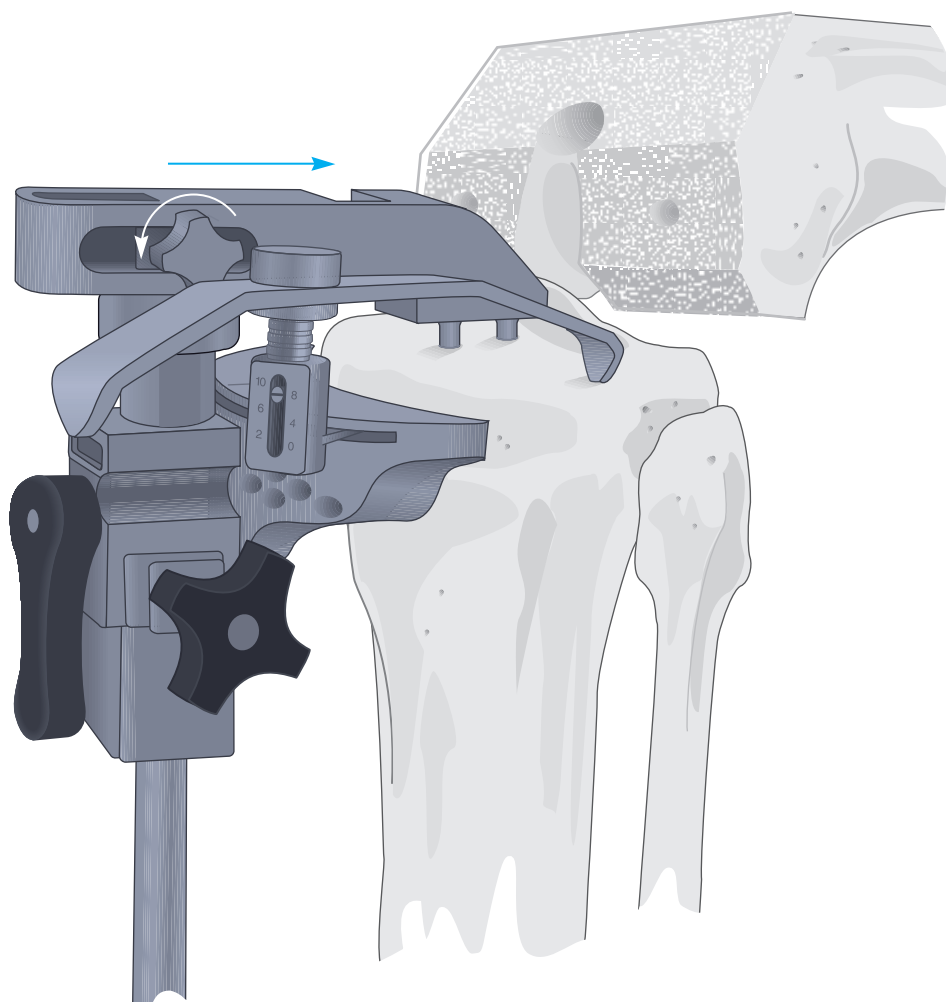


Mediolateral alignment is approximately parallel to the tibial axis, but as the lateral malleolus is more prominent, bisecting the transmalleolar axis will prejudice the cut into varus. The midline of the tibia is approximately 3 mm medial to the transaxial midline. The lower assembly is translated medially to the palpable anterior crest of the tibia, usually to the second vertical mark. There are scribe marks at 3 and 6 mm for reference. Where the platform is medially displaced, adjustment is made at the lower assembly.



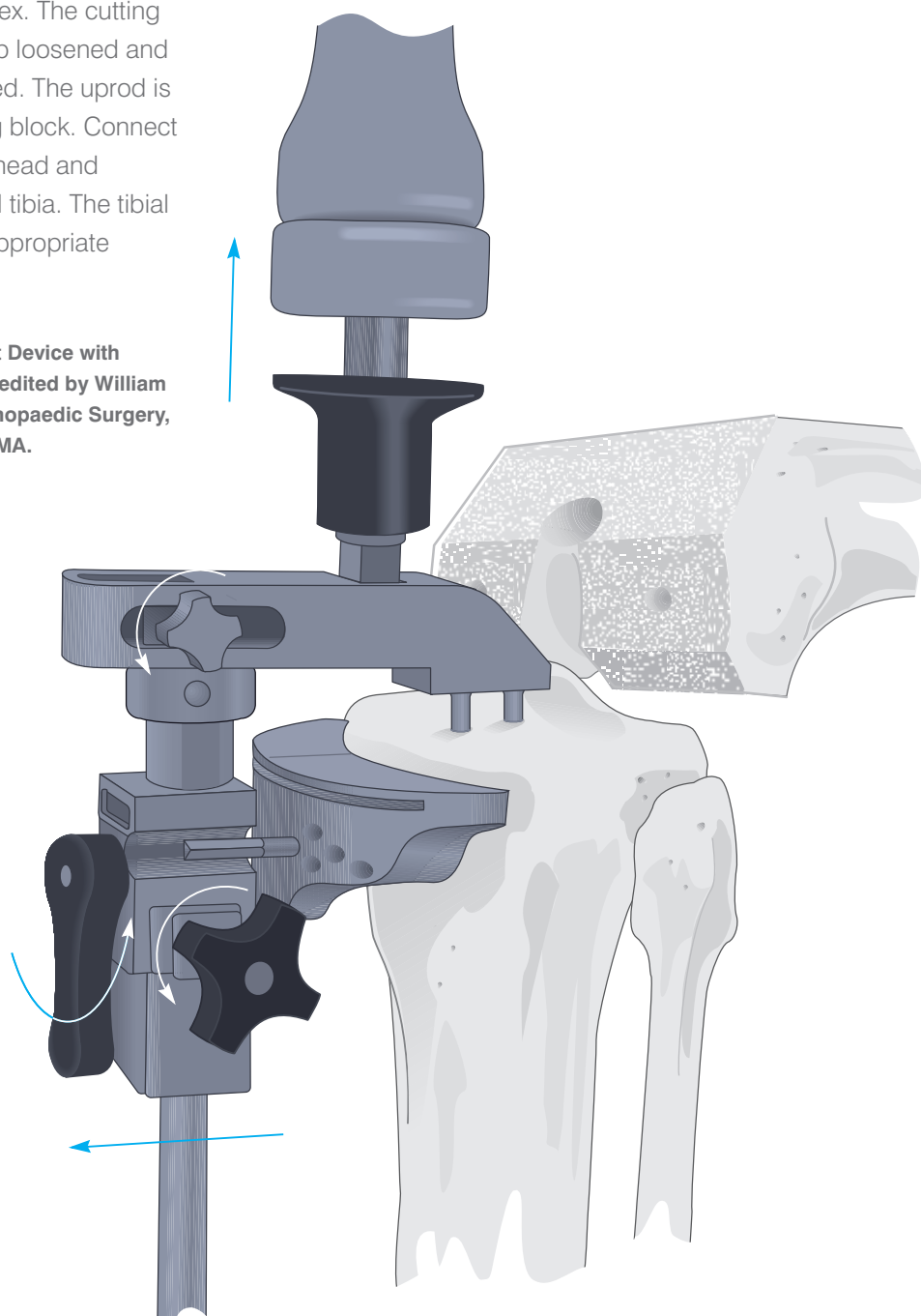
Appropriate rotation is established and the shorter spike is seated in the proximal tibia, securing the medial/lateral, anteroposterior, and rotational positions. With the set knob of the adjustable head free, slide the cutting block forward until contact with the anterior tibia is established. Tighten the set knob. The cylinder foot of the stylus is inserted into the slot of the cutting block and adjusted to the appropriate level. A level of 8 mm or 10 mm is suggested where resection is based on the less involved condyle.

A level of 0 mm or 2 mm is selected where resection is based on the more involved condyle and does not result in excessive contralateral resection. The block is adjusted such that the stylus rests on the centre of the condyle and the block is secured by the large lateral knob.



Steinmann pins or  $\frac{1}{8}$ " drill bits are introduced through the central holes marked with a □, into the tibia, stopping well short of the posterior cortex. The cutting block is unlocked, the black lateral knob loosened and the set knob securing the head loosened. The uprod is pulled and disengaged from the cutting block. Connect the quick connect slap-hammer to the head and disengage the spikes from the proximal tibia. The tibial alignment device is removed and the appropriate resection performed.

**Appendix IV, Extramedullary Tibial Alignment Device with Proximal Fixation Spike Surgical Technique**, edited by William L. Healy, M.D., Chairman, Department of Orthopaedic Surgery, Lahey Hitchcock Medical Centre, Burlington, MA.

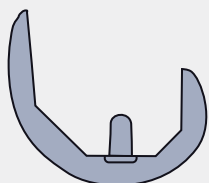


## APPENDIX V

# Cruciate Retaining Femoral and Tibial Insert Compatibility

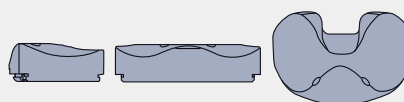
TIBIAL INSERTS								
Size 1.5								
41AP/61 ML	PLI	■	■					
	CVD	■	■					
Size 2								
43AP/64 ML	PLI	■	■	■	■			
	CVD	■	■	■	■			
Size 2.5								
45AP/67 ML	PLI		■	■	■			
	CVD		■	■	■			
Size 3								
47AP/71 ML	PLI		■	■	■	■		
	CVD		■	■	■	■		
Size 4								
51AP/76 ML	PLI				■	■	■	
	CVD				■	■	■	
Size 5								
55AP/83 ML	PLI					■	■	■
	CVD					■	■	■
Size 6								
59AP/89 ML	PLI						■	■
	CVD						■	■

### Femoral Components



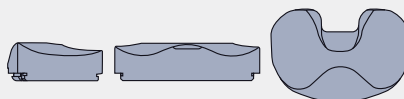
CR

### Tibial Inserts



#### Curved

8, 10, 12.5, 15, 17.5, 20 (mm)



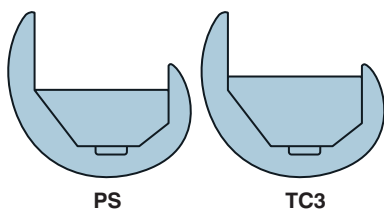
#### Posterior Lipped

8, 10, 12.5, 15, 17.5, 20 (mm)

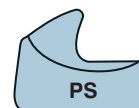# Cruciate Substituting Primary and Revision Femoral and Tibial Insert Compatibility

TIBIAL INSERTS													
Size 1.5													
41AP/61 ML	PS SP	■	■	■	■								
	TC3		■		■								
Size 2													
43AP/64 ML	PS SP	■	■	■	■	■	■	■	■				
	TC3		■		■		■		■				
Size 2.5													
45AP/67 ML	PS SP			■	■	■	■	■	■				
	TC3				■		■		■				
Size 3													
47AP/71 ML	PS SP			■	■	■	■	■	■	■	■		
	TC3				■		■		■		■		
Size 4													
51AP/76 ML	PS SP							■	■	■	■	■	■
	TC3								■		■		■
Size 5													
55AP/83 ML	PS SP									■	■	■	■
	TC3										■		■
Size 6													
59AP/89 ML	PS SP										■	■	■

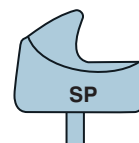
## Femoral Components



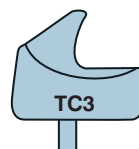
## Tibial Inserts



Posterior Stabilised  
8, 10, 12.5, 15, 17.5, 20, 22.5, 25 (mm)



Stabilised Plus  
10, 12.5, 15, 17.5, 20, 22.5, 25, 30 (mm)



TC3  
10, 12.5, 15, 17.5, 20, 22.5, 25, 30 (mm)





